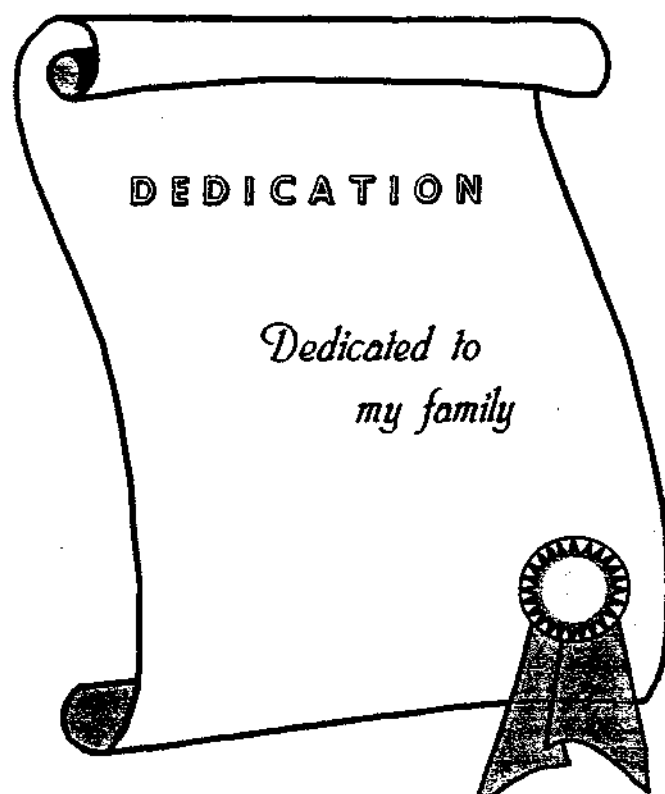


SYNDROMES IN AUDIOLOGY A REVIEW

Register No. M9914

An Independent Project Submitted as part fulfillment
for the First year M.Sc. (Speech & Hearing) to University of Mysore.



DEDICATION

*Dedicated to
my family*

Certificate

This is to certify that the Independent Project entitled "Syndromes In Audiology- A Review " is the bonafide work done in part fulfillment for the degree of Master of Science (Speech and Hearing) of the student with Register No .M9914..

Mysore

May 2000

D. J. Angewas
Director


All.India.Institute.o
Speech & Hearing,
Mysore - 570006

f

Certificate

*This is to certify that the independent Project entitled
Syndromes In Audiology - A Review " has been prepared
under my supervision and guidance.*

*Mysore
May:2000*


Dr. K. Rajalakshmi
Lecturer, in Audiology
Dept. of Audiology
AIISH. Mysore - 570006

Declaration

I hereby declare that this Independent project entitled "Syndromes In Audiology - A Review" is the result of my own study under the guidance of Dr. K. Rajalakshmi Lecturer, department of Audiology, All India Institute of Speech and Hearing, Mysore, and has not been submitted earlier at any other University for any other diploma or degree.

*Mysore
May 2000*

Register:No.M9914

ACKNOWLEDGEMENTS

I express my sincere gratitude to my teacher and guide 'Dr. K. Rajalakshmi', lecturer, department of Audiology for her patience, constant support and guidance through out this project.

" 'Tis easy enough to be pleasant

when life flows along like a song

but the man worthwhile is the one who will smile

when every thing goes dead wrong."

Madam you have been my source of light in chasing away the darkness with your encouraging and pleasant smile. Madam thanks for everything.

I am thankful to 'Dr. (Ms.) Nikam', director All India Institute of Speech and Hearing Mysore for permitting me to carry out this project.

Madam you have been the source of inspiration for most of us. I am proud to be a part of your concern.

'The family is one of the masterpieces.'

"It is a wise father that knows his own child."

Appa, your valuable advices, guidances and love have given me the strength to make this real thing happen.

"What the mother sings to the cradle goes all the way down to the coffin."

Amma, your constant touch of love and care has brought wonders in my life.

"Love is the true price of love."

Dearest Selvi,

All the good times I share with you, fights, love, tears and fun are always evergreen in my mind that keeps questioning me "Are you a sister or an Angel."

"Assets make things possible people make things happen"

Thatha, Nacchi, Mamma, Athais, Chithappa, Chithi, Arvind, Nisha, Naresh.

A circle of heaven where love showers from all corners. I am happy that I am blessed with each one of you, as you all have shaped me in special ways.

'Faith is the substance of things hoped for the evidence of things not seen.'

Periappa, periamma, Annas, Madnis, Kutty's.

Your faith in me, your support and affection through all stages of my upcoming teaches me that you are the pillars of my life.

'There is no cosmetic for beauty like happiness'

Baru

I am proud and lucky to get a person like you. The kindness, care, love you showed me have boosted me many times in many situations. Encouraging words of advices of your's has helped me in finishing this project.

"Knowledge is power."

Dear Sir/Madam,

Dear: P B K L & B J, Dr. Lakshmanan.

*Mrs. Roopa, Mr. Nithun, Ms. Visalakshi, Mr. Ajay,
Mrs. sunitha, Ms. Akila, Mrs. Rajashree, Mrs. Rukmini,
Mrs. Nappini, Mrs. Jennyphilip, Mrs. Sarumathi, Mrs.
Vadivazhagi.*

*A tons of thanks for moulding me into a shape where I am proud to
say I am your student.*

"A true friend is the greatest of all blessings"

Dear friends and crusaders,

*Raj, Anand, Rajesh, Satish, Suresh, Satya, Sudhakar,
Uma.*

*Encouragement and fun at all moments have refreshed my minds all
the times. Thanks guys and gals.*

"A single arrow is easily broken but not ten in a bundle."

Seniors and juniors,

*Prakash, Binu, Reddy, Arvind, Dass, Madhan, Vijay,
Bala, Ranju, Ranga, Ambu, Sundi, Gopi, Raju, J.K, Peter,
Vijay, Saravanan, Aru, Vidya Ramesh, Anitha.*

*A hundred and one pleasure which I would ever treasure. Your timely help, fun, care have made my mood swing disappear, any time!
Keep smiling dears.*

"The true university of these days is a collection of books."

Dear Librarians and Anthropological survey of India.

Your immense help, co-operation have helped me gather all these information. Thank you Ladies and Gentlemen.

*I would like to thank the computer professional for bearing with me, for his patience and overall handling of this project with a smiling face.
Thank you.*

"If God be for us, who can be against us?"

Oh Almighty, I thank you for blessing me with all these souls in my life and making this dream come true.

Table of Contents

Chapter 1 Introduction	1-5
Chapter 2 Review of Literature	6-85
Chapter 3 Summary and Conclusions	86-87
Bibliography	
Appendix	
Glossary	

CHAPTER -1

INTRODUCTION

What is hearing?

Hearing is defined as the entire sequence of coding, processing, integration, responding to sound.

- William. A .Yost, (1994)

What is hearing loss ?

Any loss of sound sensitivity produced by abnormality anywhere in the auditory system. It may be partial or complete.

- F.N. Martin, (1975)

What is Audiology ?

Audiology is a branch of science which deals with hearing and its related disorders.

Causes of Hearing Loss

Hearing loss can be caused by multiple factors. Usually hearing loss in an individual occurs as an isolated entity. But often we come across individuals demonstrating hearing loss with various other abnormalities. In such cases hearing loss can be an associated factor or a primary factor falling under the domain of a syndrome. In literature so far till date about 350 different syndromes are reported where in the general outstanding characteristics of the associated hearing losses are described.

Dedicated investigators in the allied discipline of psychology, Speech pathology, Audiology and Medicine have contributed to the emergence of various syndromes thus giving us a finer insight into the definite nature and causes of hearing loss.

Syndromes are part of everyday diagnosis. Today the number described seems to increase weekly. Until now, few were known or documented accurately.

People who have a definable syndrome and most common in childhood require help from the professionals being medical, nursing, social or educational, In early days patients need support, advice and counselling in order to overcome their child's disability and as well as for more practical aspects of care. Later in the child's life social workers and educationalist become involved.

All these professionals need accurate knowledge of each specific syndrome if they are to be fully effective in the treatment of disabled.

The ability of specialists in rehabilitation field to participate in the process of syndrome delineator, diagnosis and treatment depends on large part on their ability to communicate effectively with professionals from other disciplines who are experienced in clinical genetics. This means the specialist in rehabilitation field must learn the lingo of clinical genetics and apply it to disorders of hearing.

In this project an attempt is made to classify syndromes associated with hearing loss and their clinical features are listed. It is hoped that this project will prove to be of value to all professionals of Speech and Hearing, Students, Teachers and Practitioners in the applied health science who are concerned with the case of hearing disabled children and it is hoped that they will utilize this project as a reference guide for syndromes in audiology.

Pictures of some syndromes are given in Appendix. A Glossary of genetic and medical terms is included in the project to minimize the need to refer to other texts or a dictionary.

What is Syndrome ?

The Oxford English dictionary defines a syndrome as a concurrence of several symptoms in a disease. It can be described as a specific collection of signs and symptoms.

It is defined as the presence of multiple anomalies in the same individual with all of those anomalies having a single cause.

The word '*syndrome*' is of Greek derivation and means "Normally Together". Minimally, a syndrome is viewed as several abnormalities in the same individual.

Craniofacial anomalies are associated with great many syndromes. The physicians who treat children may see a wide variety of anomalies, many of which

are not readily recognized as being associated with any one syndrome. In a large study of newborn infants with multiple anomalies of all kinds (syndromes), only 40 % had known recognized syndrome (Marden et. al, 1964). The other 60 % had provisionally unique pattern syndrome that needed to be further delineated. A major task in medicine is to delineate unknown genesis syndrome as rapidly as possible because such disease fosters good patient care. As an unknown genesis syndromes becomes delineated, it's phenotypic spectrum , natural history and risk of recurrence become known, allowing for better patient care and family counseling. The process of delineation also ends in the study of pathogenesis by severe; anomalies into measuring full biologic categories, (Cohen, 1977) .

The process of syndrome delineation can be divided into two stages

1. Unknown genesis syndrome - (Cause is not known),
2. Provisionally unique pattern syndrome - (Cause is known).

Much of a child's learning is dependent upon information received from listening to speech and other sounds in the environment. As children grow and develop, they continuously acquire and utilize their communicative skills, cognate abilities and skills in social interaction. Since hearing is so important in the process of developing these skills, significant impairment in a child's hearing ability may affect various related aspects of development.

Realizing the importance of hearing in the context of a child's overall development, it can be seen that a child who is suspected of having a hearing loss needs thorough evaluation.

To delay and temporize can be detrimental whereas an evaluation that leads to a finding of normal hearing either may aggravate a parents fear about possible deafness or may lead to the conclusion that there is dysfunction somewhere in the nervous system other than in the auditory portion.

" No child is too young to be tested or too young to be evaluated when there is a suspicion that hearing ability may be impaired "

Purpose of this Independent Project

To collect within a single volume, the important findings emanating from different sources regarding the Syndromes of Audiology in order to enable the reader to get a comprehensive and varied knowledge about the same. Furthermore limited attempts have been made to integrate such information. So the present review of literature was taken up in order to delineate the various syndromes in Audiology in a nut-shell, which will be of greater help for Speech and Hearing professionals in terms of diagnosis and rehabilitation.

CHAPTER-2

REVIEW OF LITERATURE

Classification Systems

There are several methods of classifying hearing impairment, but most often they are described in terms of either their origin (e.g., hereditary, acquired), onset (e.g., genital, delayed), degree of severity and type (e.g., mild-to-profound sensory conductive or mixed), and /or structural pathology (e.g., inner ear congenital anomaly (Michel, Mondini, Scheibe, etc.). Although other nomenclature exists, four classifications are most commonly found in the literature.

The cause of deafness tend to be broadly classified into three primary categories, genetic (hereditary disorder), non-genetic (acquired), and unknown causes. Approximately half of all congenital deafness is hereditary; that is, the genetic trait of deafness is passed from parents to offspring. The remainder of hearing impairment appears equally divided between causative (non-genetic) factors and those of unknown origin.

If an inherited auditory deficit is identified at birth, three recognized genetic forms of inheritance are considered: single-gene abnormalities, chromosomal aberration and disorders due to multifactoral inheritance. Hereditary hearing loss may be congenital (present at birth) or manifest at a later period in life.

Inherited Hearing Loss

Mendelian laws describe genetic traits (physical characteristics) of inheritance that is passed from one generation to another. These fundamental physical and functional units of inheritance are called genes and consists of segments of deoxyribonucleic (DNA) that encode the blue print for every living thing. DNA is structurally packaged within chromosomes. Each human cell contains chromosomes in 23 pairs. Twenty-two of the pairs are identical in the male and female and are designated as *autosomes*. The remaining pair is called as *sex chromosomes* and is represented by two X-chromosomes in the **female** and one **X** and **Y** chromosome in the **male**. One chromosome of each pair is inherited from each parent and, with the exception of the XY male chromosome, each genetic determinant is present in two doses. Pairs of genes are called *alleles* and occupy the identical site on homologous chromosomes. A gene that alters normal characteristics is referred to as a mutant gene. The full complement of genetic material in the set of chromosomes of an organism is called its *genome*.

One method of describing a chromosome is by its structural morphology; its narrowest point is called a *centromere*. Each chromosome has a characteristic length and position of the centromere allowing each projection to be called an arm. At metaphase each chromosome has paired long and short arms. The short arms are designated as "p" (petite) and the long arms as "q". Reference to a specific arm of chromosome would be to 1p or 1q, to chromosome, 2 as 2p and 2q, and so forth.

A + sign or -sign before a chromosome number indicates the addition or absence of an entire chromosome. This represents a numerical chromosomal aberration. Example is the karyotype 17, XY, +21, which is that of a male with an extra number 21 chromosome (i.e., trisomy 21, Down syndrome). In contrast a + sign or - sign following a chromosome number represents an increase or decrease in chromosome length. This represents a structural chromosomal anomaly.

Single - gene mutations

Single-gene (monogenic) mutation that cause changes in the normal sequence of DNA base pairs are associated forms of Mendelian Inheritance and are designated as autosomal dominant, autosomal recessive, and sex (X) - linked patterns, X-linked inherited disorders may be either recessive or dominant A diagrammatic representation of Mandelian inheritance is illustrated in figure 1. Single-gene mutations may cause about 1500 rare syndromes, diseases, and morphologic traits that are associated with a high risk of recurrence.

The term "*syndrome*" is used to describe a pattern of multiple anomalies that are pathogenically related; that is, attributable to a specific etiology, which may be either known or unknown.

Autosomal recessive inheritance : Autosomal recessive inheritance requires a pair of genes for hearing loss - One recessive gene from each parent - to produce the disorder. The mutant gene must be present in a double dose for abnormal characteristics to present The term *recessive* applies only to homozygous (Having similar genetic patterns at both alleles) expressed traits.

Parents are heterozygous, having one normal and one abnormal allele, clinically asymptomatic. Recessive inherited hearing loss is by far the largest of the single-gene mutations, accounting for about 80 % of this genetic trait.

Although usually unaffected themselves these carriers will pass a copy of the recessive gene for hearing loss to about 25 % of their children. Infants who have recessive inherited hearing deficits and are the first-born children represent the largest percentage of undetected neonates discharged by hospitals. Simply, there are no risk factors of physical abnormalities and, generally in family history of hearing loss to "red flag" this population.

Autosomal dominant inheritance : About 20 % of genetic hearing loss are attributed to autosomal dominant inheritance. The term *dominant* applies to a genetic pattern that is expressed when only one gene from either parent is dominant for hearing loss (heterozygous state), In this condition the affected parent need pass only a single mutant gene in a single dose to cause the trait Thus, the trait is manifested in every infant who inherits the gene, irrespective of the condition (normal) of the other allele. The affected offspring will be either the product of an affected parent who has expression of the gene or the result of a new mutation dominant trait With this inheritance pattern, the risk for hearing impairment is 50 % for each pregnancy. The carrier is almost always hearing-impaired.

The term *penetrance* refers to the proportion of individuals who have clinical expression of the gene in some form or another and transmits it to their

offspring; 100 % penetrance means that all individuals with the gene have symptoms of the disorder. The degree of clinical manifestation varies greatly among individuals with a specific disorder. The term expressivity describes the degree of clinical variability encountered. In Waardenburg syndrome, an autosomal dominant disorder, 50% of the offspring are affected, but only 20 % have deafness.

X-linked inheritance : X-linked inherited hearing loss accounts for the remaining 1 % to 20 % of this genetic trait. X-linked genes can be either *recessive* or *dominant*. Because of the XX (female) / XY (male) chromosomal relationship, a female with a recessive gene for hearing loss on one of her two X-chromosomes will have normal hearing. Only males are affected, with offspring having a 50 % chance of hearing loss, whereas each daughter has a 50 % chance of carrying the affected gene and in turn, transmitting the X-linked trait to 50 % of her son's. A male with the gene cannot pass the trait on to his sons (since they will have inherited his Y chromosome), but all of his daughters will be carriers. Two well-known X-linked recessive gene disorders are Hunter and Alport syndromes.

In contrast, X-linked dominant disorders are generally expressed in homozygous males (a condition where only one allele of a specific gene locus is present) and are relevant only for X-linked recessive inheritance, since the recessive allele appears because there is no corresponding allele of Y chromosome. Since a dominant allele will be expressed with just one it does not matter if the individual is a heterozygous female or homozygous male pedigree pattern of X-

linked dominant traits differs from that of autosomal dominance only in that all the daughters none of the sons of affected males will be affected, since a male gives his X-chromosome only to his daughters.

Chromosomal Aberrations

Genetic hearing loss may also be the rest of chromosomal abnormalities, such as a merical distribution errors that may consist of the abnormal presence (e.g. trisomy) [47, XX, -18] representing chromosome 18 in triplicate rather than in duplicate), absence (e.g., Turner syndrome [45, X] a chromosome. Chromosomal aberration may also present as structural errors in which *deletions*, *additions*, *duplications*, *transactions* and *inversions* may occur.

Chromosomal disorders are found in about 1 % of the total new born population. Down syndrome (trisomy 21) is the most familiar and common chromosomal abnormality, having an incidence of about **1:600** live births and producing a high incidence of conductive hearing loss and to a lesser degree, associated auditory sensory pathology.

Multifactorial Inheritance

Deafness due to multifactorial (polygene) inheritance refers to the additive effect of several minor gene pair abnormalities in association with nongenetic environmental interactive factors. As such genetic inheritance is difficult to establish.

In addition to hearing loss, a higher incidence of craniofacial birth defects may occur, including cleft lip and palate. For example, Pierre-Robin sequence is a

trait of micrognathia, cleft palate, and glossoptosis. A sequence is a multiple pattern of anomalies that, unlike a syndrome, result from a primary anomaly such as micrognathia.

Ethnic origin, gender, the number of affected relatives and their relationship in any one family, and the severity of the defect affect Multifactorial risk characteristics. Table 1 lists some common inherited hearing disorders based on single gene abnormalities, chromosomal aberrations, and disorders due to multifactorial inheritance.

Isolated Conditions

In most cases inherited hearing loss occurs as an isolated entity, independent of other changes in physical status or disease processes. Typically, there are no additional clinical signs or symptoms or other dysmorphic stigmata associated with this type of hearing loss, which often makes early identification of hearing loss problematic. However, about one-third of all genetic hearing loss accompanies syndromes having physical characteristics such as craniofacial anomalies or multiple congenital organ system malformations.

Congenital Hearing Loss

The term *congenital* is used to describe a condition or symptom whose onset occurred *at* (perinatal) or *before* (prenatal) birth. Congenital birth defects imply that during certain critical periods of the pregnancy changes in normal morphologic and functional development have occurred that are recognized at birth or manifest and progress later in life.

"Congenital hearing loss" is often reserved for severe-to-profound sensory auditory deficits. This definition is somewhat restrictive and should be expanded to include conductive as well as mixed hearing loss of all degrees of severity, since any hearing loss at birth is congenital by definition.

Congenital hearing loss may result from genetic and / or other factors such as prenatal viral infection, anoxia, trauma, and other perinatal insults of known or unknown origin. Therefore, congenital hearing impairment is not necessarily genetic. Further, a congenital syndrome may also have later onset hearing loss. For example, congenital syphilis (a non-genetic disorder) is present at birth because it is a prenatal event. However, hearing loss is delayed, since symptoms are usually not demonstrated until the teenage years.

It has been reported that from one-quarter to one-half present with associated sensory and /or conductive hearing loss that may be present at birth or delayed in its onset. The degree, severity, and acceleration of auditory corrosion vary considerable in delayed hearing impairment and its onset may be observed during the neonatal or early childhood period. Early identification through the use of electrocardiograph and auditory brainstem response screening has helped identify this potentially life-threatening condition.

**Classification System of Hearing Disorders by Type and Major System
Dysfunction (Modified from Bergstrom et al, 1971).**

*John .T. Jacobson, (1997) - A review of genetic hearing loss : The Hearing
Journal, 50: 6,10-21*

Autosomal Dominant	D
Autosomal Recessive	R
X-linked	X
Chromosomal	C
I. Craniofacial & Skeletal Disorders	
a) Sensory Hearing Loss	
Cleidocranial dysostosis	D
Diastrophic Dwarfism	D
Marshall Syndrome	D
Townes Syndrome	D
b) Conductive Hearing Loss -	
Apert Syndrome	D
Branchio otorenal Syndrome	D
Carpenter Syndrome	R
Fanconi's anemia Syndrome	R
Madelung deformity	D
Malformed low-set ears	R
Mohr Syndrome	R
Symphalangism	D
c) Sensory and / or Conductive Hearing Loss	
Achondroplasia	D
Crouzon Syndrome	D
Klippel feil Syndrome	R
Marfan Syndrome	D
Otopalato digital Syndrome	X

Pierre Robin Sequence	D
Pyle disease	D
Stickler Syndrome	D
Treacher Collins Syndrome	D
d) Progressive Sensory and Delayed Onset	
Spondylo epiphyseal dysplasia	
Van Buchem Syndrome	R
e) Progressive sensory and / or conductive hearing loss	
Albers Schonberg disease	R
Cokayne Syndrome	R
Engelmann Syndrome	D
Osteogenesis Imperfecta (Types I-IV)	
Paget disease	D
II. Cardio vascular System Disorder	
a) Sensory Hearing Loss	
Jarvell & Lange-Nielson	R
Dr. Nervous System Disorder	
a) Sensory Hearing Loss	
Noonan Syndrome	D
Richard Rundell Syndrome	R
Muscular Dystrophy	R
Myoclonic epilepsy	R
b) Progressive Sensory and delayed Onset	
Acoustic Neuromas	D
Fredrich ataxia	R

Herrmann Syndrome	D
Myoclonic Seizures	D
Sensory radicular neuropathy	D
Infantile muscular dystrophy —	R
IV. Renal Disorders	
a) Conductive Hearing Loss	
Branchio-Oto-Renal	D
Nephrosis, Urinary tract malformation	X/R
Oto-renal-genital syndrome	
V. Integumentary and Pigmentary Disorders	
a) Sensory Hearing Loss	
Albinism Syndrome	R/X
Ectodermal dysplasia	D
Hypo Pigmentation	D
Kerato Pachyderma	R
Leopard syndrome	D
Neuro fibromatosis	D
Onchyodystrophy	R
Partial albinism	-X/R
Pili torti	R
Warden burg Syndrome	D
VL Miscellaneous Somatic Disorders	
A) Sensory Hearing Loss	-
Trisomy 13	C
Trisomy 18	C
b) Conductive Hearing Loss	
Turner Syndrome	C

VII. Endocrine and Metabolic Disorders	
a) Sensory Hearing Loss Alstrom Hyper Prolinemia I Pendred Syndrome Sickle Cell anemia	R D R D
b) Sensory Progressive & Delayed Onset Alport Syndrome Amyloidosis, nephritis & Utricaria Hyper Prolinemia II Hyper Uricemia	D D D D
c) Progressive Sensory and / or Conductive Hearing loss Hunter Syndrome Hurler Syndrome	X R
VIII. Eye Disorders	
a) Sensory Hearing Loss CHARGE Association Hall Gren Syndrome Laurence-Moon-Biedl Syndrome Usher Syndrome	R R R
b) Conductive Hearing Loss Cryptophthalmia Duane retraction Syndrome	R D

c) Sensory and / or Conductive Hearing Loss Mobius Syndrome	R
d) Progressive Sensory & Delayed Onset Alstrom Syndrome Cockayne Syndrome Fehr Corneal Dystrophy Flynn-Aird Syndrome Noorie Syndrome Optic atrophy & Diabetes Mellitus Refsum Syndrome	R R R D D R R

Craniofacial & Skeletal Disorders

a) Sensory Hearing Loss

1. Cleidocranial dysostosis (FONS 1969)

- Hereditary autosomal dominant.
- External and middle ear anomalies include small auricle, atresia of the external auditory canal, small ossicles.
- Absence of manubrium of malleus, absence of long process of Incus, fixation of stapes foot plate and tympanic cavity.
- Aplasia of clavicle.
- Sensorineural hearingloss.

2. Diastrophic Dwarfism

- Craniofacial disorder.
- Recessive trait.

- Marked shortness of stature, characteristic hand deformity with short fingers and severe bilateral club foot.
- Auricles show cystic swellings in infancy that later develop in to cauliflower like deformities that may calcify .
- 25 % incidence of cleft palate.
- Congenital sensorineural hearing loss (Langer, 1965).

3. Marshall Syndrome

- Autosomal dominant transmission.
- Severe myopia.
- Congenital and Juvenile cataracts.
- Saddle nose defect.
- Various skeletal abnormalities.
- Early onset progressive moderate SN hearing loss.
- Ruppert et,al. (1970). noted moderate high tone sensorineural loss. While zellweger et, al. (1974) reported 30-60 dB SN hearing loss in the affected members.

4. Townes Syndrome (Fig 1)

- Autosomal dominant disorder.
- Malformation syndrome with characterised triad, anal atresia, triphalangia of the thumb, defective hearing (anus-hand-ear syndrome).
- Anorectal malformations ; anal atresia with fistulization, ventrally positioned anus, anal stenosis.
- Malformation of hand; pre-axial polydactyly, triphalangeal thumbs, broad thumbs, agensis of the thumbs, arthrogryposis of thumb joints, infrequently radius hypoplastic.

- Malformation of ear ; Microtia, satyr ears; lop ears, pre-auricular tags and fistulas, SN and Conductive hearing disorders with malformation of ossicles.
- Unilateral renal hypoplasia.
- Mandibular hypoplasia, cleft lips, palate.
- Wider spaced incisors .

- (O' Callaghan and Young, 1990).

b) Conductive Hearing Loss

1. Apert Syndrome (Acrocephalo syndactyly type 1) or Vogt Cephalo-Syndactyly

- Autosomal dominant disorder.
- Premature fusion of bones of skull.
- Malformation of hands and feet.
- High prominent fore head - swelling in the midline flattened back head.
- Flattened small nose and large lower jaw.
- Large and prominent eyes.
- Low set ears and congenital hearing loss is frequently present.
- Webbing of the skin between the fingers is present and fusion of bones in the hand.
- Learning disability occurs in and around 50 % of children, 50 % have normal intelligence.
- Unusual complications seen in large number of young people with this syndrome, is severe acne during the adolescent years.

- (Bergstrom et. al., 1972 ; Lindsay et. al., 1975)

2. Branchio otorenal Syndrome

- Autosomal dominant disorder.
- Ossicular anomalies, cochlear anomalies .

- Vestibular anomalies, bronchial clefts.
- Preauricular pits. Malformed auricles.
- Lacrimal duct stenosis.
- Renal anomalies.
- Abnormal resonance as seen in deaf speech may occur.
- Conductive, sensorineural mixed loss may be progressive, ranges from mild to profound loss.

- (Shprintzen, 1997).

3. Carpenter Syndrome

- Autosomal recessive disorder.
- Craniosynostosis, Polydactyly - Syndactyly have anomalies, small stature
- Cognitive impairment.
- Occasional skeletal anomalies.
- Occasional hernias, scoliosis.
- Hyponasality secondary to small nasal capsule.
- Abnormal oral resonance secondary to short neck.
- Conductive hearing loss.

- (Shprintzen, 1997).

4. Fanconi's anemia Syndrome (Renal tubular acidosis)

- A syndrome of many causes predominantly of recessive type.
- Exposure to toxic agents directly precedes most acquired cases.
- Clinical manifestations are dependant upon the causes of syndrome.
- Impaired renal tubular transport, growth retardation common.
- In infantile form, high frequency SN deafness is noted.
- In adolescent form, slowly progressive SN deafness noted during teen years

(Mc. Donough 1970, Walker 1971
Digweed and Zakerzewski, 1988).

5. **Made lung's deformity** (Dyschondnosteosis, 'Leri Weill Disease')

- Autosomal dominant transmission.
- Craniofacial skeletal disorder.
- Deformity of distal radius and ulna bones and mild dwarfism.
- Congenital bilateral conductive loss with abnormal ossicles and narrow external auditory canals (Nasif & Harboyan, 1970) .

6. **Malformed low-set ears syndrome**

- Craniofacial disorder with unilateral cum bilateral mild to severe conductive hearing loss associated with malformed low set ears (usually bilateral).
- Conductive loss usually worse in the most affected external ear.
- May be accompanied by mental retardation in 50 % of cases (Mengel et. al., 1969).

7. **Mohr Syndrome** (Oral-Facial digital II)

- Transmitted as recessive trait.
- Deformities of face, mouth and fingers.
- Characterized by cleft lip and lobulated tongue, broad nasal root, hypoplasia of the mandible, polydactyly and syndactyly. Oral deformities may cause speech problems.
- Conductive hearing loss associated with malformed ossicles (Rimoin & Edgerton 1967), (Anneren and Arvidson, 1984)

8. **Symphalangism (Brachy dactyly syndrome) (Fig 2)**

- A syndrome of malformation of hands and feet characteristic facies and defective hearing.
- Congenital limitations of movements at the proximal inter phalangeal joints of second to fifth finger with absence of normal articular crease ; possible limited movement at the elbow joints and finger, at the wrist and ankle joints in some cases with abnormal gait.

- Brachydactyly, possible absence of distal sequence of fingers (or toes) cutaneous syndrome (1 & 2).
- Unusual faces ; long and rather narrow face with long prominent nose, broad nasal bridge, Asymmetrical mouth with their upper lip (1).
- Conductive hearing impairment possibly first apparent in adolescence (ankylosis of auditory ossicles).
- Normal height but possible abnormal proportions because of short arms.
- Hereditary disorder, autosomal dominant considerable interfamilial variability.

C) Sensory and / or Conductive Hearing Loss

1. Achondroplasia (Chondrodystrophia Foetalis, Parrot Syndrome) (Fig 3)

A classic generalized skeletal dysplasia with disproportionate short stature, large head, and typical facial dysmorphism and characteristic X-ray findings

- Inherited as autosomal dominant disorder.
- Primordial disproportionate short stature the proximal parts of the extremities, more severely shortened than the trunk, average adult height for women 124 cms. ; for men 131 cm. Ulnar deviation of the hands, splayed finger, limited extensions at the elbows (3,5,6), genu valgum .
- Head too large for the body and occasionally also for age, especially the cerebral cranium, when shows striking growth in the first year of life. (Men=60cm, Women = 57cm) coarse facial features, depressed nasal bridge, prognathism and hypoplasia of the midface .
- Flat thorax, frequently belt shaped thorax, kyphosis, lumbosacral lordosis (4,5,7).
- Delayed motor development due to initial muscular hypotonia, normal mental development. Occasional hearing impairment. (Conductive or Sensorineural hearing loss).
- Large cranium with frontoparietal bossing and relatively short base.
- Small foramen magnum.

- Broad flat pelvis, narrow pelvic inlet, flat acetabula, long bones shortend but with normal width. Fibulae relatively too long
- (Reiser and Pauli, 1984).

2. Crouzon Syndrome (Craniofacial dysostosis) (Fig 4).

- Acrocepholy with high wide fore head, stature with pronounced bulging of anterior Frontanalle region flat occiput (1,3,5,6).
- Exophthalmos (with flat orbits) slight antimongoloid slant of palpebral fissures. Convergence of globes difficult or impossible divergent strabismus, possible ptosis.
- Maxilla hypoplasia with parrot beak nose, short upper lip high, narrow palate, narrowly spaced teeth.
- Impaired hearing
- Mild to moderate Mental Retardation.
- Reduced visual acuity
- (Dodge et. al., (1959), Baldwin, 1968).
- (Vulliamy and Normandale, 1966).

3. Klippel feil Syndrome (Brevicollis ; cervico-oculo acoustic dysplasia).

- Multifactoral inheritance.
- Craniofacial disorder and autosomal recessive inheritance .
- Involves fusion of some or all cervical vertebrae and is characterized by a short neck with limited mobility .
- Club foot and cleft palate.
- Neurological disturbances.
- Fusion of cervical vertebrae, abducens nerve palsy, occasional cleft palate, torticollis.
- Severe sensorineural or conductive hearing loss.
- May range from mild to profound.

- Narrow external auditory meatus and / or middle ear space .
- Deformed ossicles narrow oval window, niche.
- Underdevelopment of cochlea and vestibular structures .
- Absence of 8th cranial nerve and absence of semicircular canals.
- Central Nervous System involvement is also frequently reported.
- More common in females (Mc. Lay and Maran 1969; Stark & Borton 1973; Windle-taylor et. al., 1981; Miyamoto et. al., 1983). (Silva, 1982).

4. Marfan Syndrome

- Dominant inherited disorder of connective tissue.
- Arachnodactyly, scoliosis, joint hyper mobility, dislocated lenses and cardiac anomalies.
- Rarely deafness has been associated.
- Homocystinuria.
- Deafness attributed to numerous middle ear infection.
- Round window bulged towards the scala.
- Utriculoampullary space and endolymphatic duct were dilated.
- Number of these patients has syndrome of Keratoconus, myopia, marfanoid Habitus and Sensorineural deafness.
- Intelligence is usually normal.
- Hearing loss has been described and has not been severe.

- (Kelemen, 1965).

5. Otopalato digital Syndrome (Fig 5).

Hereditary disorder with mode of inheritance not yet definitely established, X-Linked recessive is probably the predominant type but X-Linked dominant and autosomal dominant with sex limited expression have been also suggested.

A malformation syndrome with typical facial dismorphism, signs of bones dysplasia, particularly in the form of frog hands and frog feet cleft palate and impaired hearing.

- Characteristic facies with broad prominent forehead, hyperteloniism, anmongoloid slant of palpebral Fissures marked supra orbital bulging, broad nasal bridge, flat midface and microstomia with down turned corner of mouth. Prominent occiput.
- Low set ears, Micrognathia and cleft palate .
- Broad and short distal phalange of hand and feet, particularly of the first ray, the shortness of which is due mainly to hypoplasia of metacarpal or first metatarsal and the proximal phalanx. Frequently linodactyly of little finger. Enlargement and limited mobility of large joints.

- (Brewster & Lachmam, 1985).

- Frequently moderate Conductive hearing loss. Tendency to otitis, Sinusitis & mastoiditis.
- Frequency mild Mental Retardation.
- Dental anomalies, slight shortness of strature, fusion and deformities of metacarpel and meta tarsal with additional ossification centres and ossicles.

- (Fitch and Jequier, 1983).

6. Pierre Robin Sequence (Cleft palate, Micrognathia and Glossoptosis)

- Dominant type of transmission.
- Craniofacial skeletal disorder.
- Cleft palate, smallness of jaw and chin and downward displacement or retraction of tongue.
- Ears may be low set.
- 20% of cases are associated with Mental Retardation
- Congenital computations, hip dislocation, Sternal anomalies, spina bifida, hydrocephaly and microcephaly.
- Cardiac and middle ear anomalies have been reported .

- Congenital conductive and / or sensorineural hearing loss.
- 50 % incidence of conductive hearing loss in a sample of 20 Pierre Robin sequence patients. Risk of occurrence is 1 in 30,000 (Williams et al, 1981).

7. Craniometaphyseal dysplasia (Pyle disease) (Fig 6).

A hereditary system defect of ossification with widening of metaphyses, thickening of skull bones and often impaired hearing.

- Hypertelorism with paranasal bony, ridges (1 & 2) and bulging of broad nasal bridge and the glabella (3) which together, with a large occipito frontally protruding cranium, produce a characteristic appearance.
- Narrowing of nostrils with mouth breathing.
- Eustachian tube obstruction.
- Compression of auditory and facial nerve is reported.
- Increased alkaline phosphate and other biochemical findings possible.
- Progressive conductive or sensorineural hearing loss.

Aetiology

Hereditary disorders with variable expression heterogenesis autosomal dominant from more frequent than perhaps a more severe autosomal recessive type.

- (Cole and Cohen, 1988) .

8. Stickler Syndrome (Fig 7).

- Autosomal dominant disorder with very varied expression of individual signs.
- Flat often symmetrical face with variables depressed nasal bridge and nose(1,4), epicanthic folds hypoplasia of mid-face or mandibles(3), cleft palate (hard or soft palate, sometimes with bifid uvula) frequently with fully expressed Robin triad(3,4).

- Early myopia of marked to extreme severity with changes of fund, possible glaucoma, cataract, retinal detachment and retinoschisis leading to blindness.
- Not infrequently, martanci habitus (1,2,4) moderately developed, hypotonic musculature and hyperextensibility of large (and possible also small) joints
- Hip & Knee joints most severely affected .
- The arthropathies are not constant and the last important sign.
- Conductive or sensorineural hearing impairment.
- Dental anomalies, possible development of kyphosis or scoliosis, thoracic deformities.
- Prolapses of mitrial valve frequent.

- (Temple, 1989).

9. Treacher Collins Syndrome (Fig 8).

A malformation syndrome with very characteristic facial dysmorphism.

Main signs

- Antimongoloid slant of the (possibly abnormally short) palpebral fissures with usually distinct coloboma (possibly only indentation) in the lateral half of the lower eyelids (from which the eyelashes may be absent), rarely also of the upper lids (1-4).
- Frontonasal angles often flat (1-3). Possibly aquiline and/or large looking nose, sometimes with narrow nostrils (1-4).
- Hypoplasia of the zygomata and of the upper and lower jaws with the cheeks appearing sunken (see especially 3a); narrow receding chin.
- Frequent macrostomia (1b) with high, narrow or cleft palate and dental anomalies.
- Usually considerable malformation of the external ear (microtia; stenosis or atresia of the auditory canal) (1-4). Frequently, defects of the middle and/or inner ear; these are more likely, the more severe the external ear deformity.

Possible atrophic areas of skin, blind fistulas or skin tags between the corner of the mouth and the ear (1c).

- The appearance has been described as fish or bird like facies (1 and 2).
- Frequent conductive hearing impairment or deafness.

Supplementary findings

Abnormal hair growth from the temples on to the lateral cheeks, towards the corners of the mouth (1a, 3b, 4a).

The facial anomalies can, exceptionally, be asymmetric or even unilateral. Malformations of the eyes such as microphthalmos or coloboma of the iris are unusual. Choanal atresia in isolated cases.

Diverse extracranial malformations, e.g. cardiac defects may occur. Intelligence normal as a rule (In case of doubt, allow for the patients psychological handicap and for the possibility of a hearing defect).

Manifestation : At birth; hearing impairment later, if present.

Aetiology

Autosomal dominant inheritance with complete penetrance but variable expression.

- (Opitz, 1993).

d) Progressive Sensory and Delayed Onset

1. Spondyloepiphyseal dysplasia (Fig 9).

- An autosomal dominant hereditary syndrome and disproportionate short stature with severe shortening of the vertebral column, hand shaped chest, deep lumbar lordosis a severe dysplasia of the epiphyses, especially these near the burst, praxella normally cranium, hands and feet; frequently in combination with myopia and retinal detachment.

Main signs

- Disproportionate short stature which shortening essentially of the vertebral column, short neck - compressed appearing trunk with barrel shaped chest and pectus excavatum lumbar hyper lordosis, possible kyphoscoliosis of the thoracic spine.
- Retards long extremities. Frequent waddling gait when severe hip displaced and marked coxa vara. Frequent genu valgum, normal sized hand and feet.
- Impaired vision because of myopia or retinal detachment in approximately 50 % of patients.
- Flat faced - occasional cleft lip.
- Delayed motor normal mental development.
- Sensorineural hearing loss

- (Reardon and Hall, 1994).

2. Van Buchem Syndrome (hyperostosis frontalis interna).

- Recessive cranio-facial skeleton disorder.
- Generalized osteosclerotic overgrowth of the skeleton
- Paralysis of cranial nerve 7 and sensorineural deafness are frequent
- Onset during puberty demonstrated by narrowing of skull foramina causing cranial nerve paralysis with visual and mixed type hearing loss .
- Lion like facial expression with square jaw (Fossum 1968).

e. Progressive sensory and / or conductive hearing loss

1. Albers Schonberg disease (disease of osteopetrosis) (Fig 10).

(Chalk bone disease, Ivory bone disease, Marble bone disease).

- Cranio facial and skeletal disorder .
- Recessive form associated with deafness.
- Brittle but paradoxically sclerotic thickened bones.
- Enlarged head.

- Retarded growth in 1/3 of cases .
- Visual loss note in about 80 % of cases which may lead to blindness .
- Mental retardation in 20 % of cases.
- Facial palsy unilateral or bilateral in 10 % . Geristen and Vossen (1994).
- 25 - 50 % of patients are reported to have moderate, progressive sensorineural or conductive hearing loss (Johnston et. al., 1968 ; Jones and Mulcahy, 1968 ; Myers and Stool, 1969).

2. Cokayne Syndrome (Fig 11).

A disorder manifesting as a rule from second year of life onwards and leading to sever dystrophic growth retardation with typical faces, microcephaly, mental retardation neurological and ocular defects and other anomalies.

Signs

- Sever growth deficiency, disproportionate because of excessive length of extremities and oversized hands and feet.
- Typical faces, narrow, sunken and too old with deep set eyes, thin nose, prognathism, derived cases.
- Increasingly apparent microcephaly.
- Progressive neurological defects.
- Ataxia some times tremor.
- Hearing impairment which may progress to deafness.
- Mental retardation, low visual acuity, retina pigments.
- Hypersensitive to less light with exanthemata and subsequent pigment changing and scarring.
- Disorder of water salt metabolism.
- Impaired sweating.
- Cryptorchidism.

- Progressive development of muscular contractions of large joints and increasing dorsal kyphosis.

- (Patton, Giannilli and Francis, 1989).

3. **Engelmann** Syndrome (Craniodiaphyseal dysplasia, Diaphyseal dysplasia)

- Inherited as dominant and / or recessive transmission.
- Bilateral fusiform enlargement of diaphyses of the long bones .
- Skull base may be sclerotic .
- Deafness is universal and may appear as progressive sensorineural mixed or conductive in nature (Nelson and Scott, 1969 ; Sparkes and Graham, 1972).

4. Osteogenesis Imperfecta (Type I **and** IV) (Fig 12).

Hereditary disorders with abnormal fragility of bones (frequently with secondary deformities of extremities, spine and thorax), small face with bulging forehead and temples, frequently short stature, laxity of joint capsules and ligaments, blue or less frequently, blue-white sclera, hypoplasia of dentin and enamel in some patients and hearing impairment (possibly with late onset).

Main Signs

- Increased fragility of bones (commonly called 'brittle-bone disease'), often especially of the proximal extremities with frequent secondary deformities of the limbs, spine and thorax and correspondingly reduced height (1-3,6).
- Small triangular face below a relatively large calvaria , bulging forehead with temples (1 and 2).
- Blue sclerae (not infrequently and also tympanic membrane) ; possible dentinogenesis imperfecta with increased disposition to caries and possible otosclerotic hearing impairment.
- Laxity of joint capsules and ligaments, possible tendency to dislocate. Tendency to develop hernias. Genu valgus, Pes planus.

Thin, translucent skin, possible bleeding diathesis. Formation of broad, hypertrophic scars.

- Patterson and Mc Allion (1983).

Supplementary findings

Radiologically, mineral-deficient, narrow, frequently bowed, long (tubular) bones with thin cortices (4-6) and flat or biconcave transparent vertebral bodies; delayed ossification of the calvaria with wormian bone mosaic like picture.

In some patients, marginal corneal clouding (embryotoxon, with blue sclera). far sightedness or other eye abnormalities.

Aetiology

This is a group of hereditary disorders, of which at least four show autosomal dominant transmission (types I A, B; FV A, B) with variable expression.

5. Otosclerosis

Autosomal dominant otosclerosis effects the bone homeostasis of the labyrinthine capsule resulting in abnormal resorption and redeposition of bone. This bone dysplasia, limited to the otic capsule, originates in the endochondrial bone layer.

Phenotypic Expression:

The foci of otosclerotic bone are symptomatically quiescent until the movement of the stapes is compared by invasion of the stapedovestibular joint (Schuknecht, 1974).

The primary symptom produced by the otosclerosis lesion is a conductive hearing loss, the magnitude of which is directly related to the degree of fixation of the stapes footplate.

- It also progresses and damages the inner ear to cause progressive SNHL (Schuknecht, 1974).

- Usually involves both the ears.
- Cawthorne (1955) found clinically unilateral otosclerosis in 13 % Larsson (1960) in 15 %, Guild (1944) reported histologically unilateral otosclerosis in 30 % and Hueb et al., (1991) in 24.4%.
- Low pitched tinnitus is usually present.
- Vertiginous spells or dizziness are uncommon.
- Exact age of onset is difficult to determine .
- Greatest risk period 11-45 years Morrison (1970).
- Albrecht (1922). concluded that otosclerosis is due to a simple dominant factor (Autosomal dominant).

6. Paget disease : (JUVENILE) (Hereditary hyperphosphatasia)

- Recessive skeletal disorder.
- Progressive skeletal deformities that become apparent during second or third year of life.
- May result in sporadic cranial nerve involvement.
- Progressive enlargement of head and long bones .
- Occasional progressive mixed type hearing disorder due to continued new bone formation at skull base (Thompson et. al., 1969).

F. CARDIO VASCULAR SYSTEM DISORDERS

a. Sensory Hearing Loss

1. Jervell and Lange - Nielsen syndrome : (Cardioauditory syndrome & surdocardiac syndrome).

- Autosomal recessive trait.
- Cardio vascular disorders affects 0.3 % of congenital deaf persons.
- Consanguinity is common .

- Profound congenital bilateral sensorineural deafness accompanied by electrocardiographic abnormalities; Fainting attacks and occasionally sudden unexplained death in childhood.
- Death, usually occur between 3 & 14 years of age in over half the cases of cardiac problems
- Hearing loss is usually symmetrical.
- Often erroneously diagnosed as a seizure disorders & thus improperly treated
(Jervell & Lange - Nielsen, (1957); Friedmann et.al. (1966); Wahl dick (1980) .

G. NERVOUS SYSTEM DISORDERS

a. Sensory Hearing Loss

1. Cerebral Palsy

- Recessive or sporadic trait.
- 1 of 330 babies is born with cerebral palsy.
- Paralysis due to a lesion of the brain usually suffered at birth.
- Characterized by uncontrollable motor spasms.
- Cerebral palsy involves paralysis, weakness, inco-ordination (or) other abnormality of motor functions due to pathology of motor control centers of the brain.
- Damage to the brain may occur during embryonic, fetal or early infantile life.
- Essentially non-progressive, clinical symptoms of the disorder include spasticity (40%), athetosis (40%), ataxia (10%), or combinations of these basic motor dysfunctions.
- Mental deficiency and convulsive disorders are common.
- Feeding problems, retard growth, eye difficulties such as strabismus and nystagmus.

- Developmental delay, orthopaedic problems, communication disorders and educational problems are often evidenced in varying degrees.
- Damage to the brain may occur during embryonic, fetal or early infantile life and may result from an antecedent disorder such as trauma, metabolic disorder or infection; destructive intracranial cerebral processes and/or developmental defects of the brain.
- Lesion may be in the cerebral cortex, basal ganglia (or) other sites in pyramidal or extrapyramidal system.
- Less frequently, cerebellar damage may be evident.
- Patient may have mild to moderate sensorineural hearing loss typically more severe in high frequencies.

1. Muscular Dystrophy

- Recessive or X-linked.
- Muscle wasting of various types classified by transmission mode, age of onset, damaged muscle set, rate of disease development, associated problems.
- Pseudohypertrophic muscular dystrophy usually begins prior to age 5 years and affects most body muscles including cardiac and pulmonary systems.
- Facio - scapulohumeral type affects face, shoulder and upper arm muscles ; slowly progressive with age and onset at 13-14 years.
- Limb girdle type initially affects muscles of hips and shoulders.
- Myotonic muscular dystrophy associated with diabetes mellitus and cataracts usually of late onset at age 30-40 or older.
- Severe infantile muscular dystrophy noted to be accompanied by sloping, sensorineural hearing loss of mild to moderate degree.
- Risk of occurrence is 1 in 100000; childhood form is usually noted during initial 3 years of life. Extremely rare in females.

- (Black et. al., 1971).

2. Myoclonic Epilepsy

- Dominant nervous system disorder with variable expressivity.
- Seizure disorder characterized by myoclonic movements that include jerking motions involving head, trunk and limbs .
- Slowly progressive ataxia.
- No mental retardation .
- Progressive sensorineural hearing loss of late onset (May and White, 1968).

3. Optic atrophy and Diabetes mellitus

- Autosomal recessive with onset in childhood of progressive visual impairment, diabetes mellitus.
- Onset prior to second decade, with childhood progressive sensorineural hearing loss (Stevens and MacFayden, 1972).

4. Noonan syndrome (Pseudo Ullrich-Turner syndrome) (Fig 13).

Probably heterogeneous malformation-retardation syndrome occurring in both sexes, (without chromosomal aberration) with characteristic faces, growth deficiencies, cardiac defects and multiple other (usually less severe) anomalies.

Signs

- Usually mild proportionate short stature.
- Not infrequently mild to moderate mental retardation occasionally hearing defects.
- Typical faces mainly characterized by hypertelorism, antimongoloid slant of palpebral fissures, epicanthes, ptosis, down turned corner of mouth and micrognathia.
- Low posterior hairline webbed neck of redundant skin of lateral neck. Low set ears with unusual rim; high palate .
- Shield chest with Pectus carinatum and can excavatum.
- Pulmonary stenosis.
- Frequently multiple pigment anomalies such as cafe - au-lait spots.

- Cryptorchidism ; Undescended testes ; possibly small testes (after puberty).
- Delayed puberties in same points. Fertility possible in both sexes.
- Occurrence of renal anomalies.

- (Mendez & Opitz, 1985).

5. Richards-Rundle Syndrome (Ataxia-hypogonadism syndrome)

- Recessive trait.
- Nervous system disorder, Ataxia, Muscle wasting in early childhood
- Progressive severe Mental Retardation.
- Absent deep tendon reflexes with failure to develop secondary sexual characteristics.
- Early onset of progressive severe SN loss; Horizontal Nystagmus. (Richard and Rundle, 1959)

6. Partial Albinism-Pie-baldness

Divided in to three integumentary-pigmentary syndromes by Konigsmark and Gorlin, 1976.

- Recessive pre-baldness and profound congenital sensorineural loss .
- Head hair upper chest and both arms show substantial depigmentation. Normal vision with blue irises.
- X-linked pigmentary abnormalities and congenital profound sensorineural loss. Similar pigmentary changes as seen in recessive type.
- Dominant pre-baldness ataxia and sensorineural loss 80 % have ataxia and mental retardation and 60 % have progressive sensorineural loss. (Woolf et. al.,1965).

b. Progressive Sensory and Delayed Onset

1. Acoustic Neuromas

Neurofibromatosis : Von Recklinghausen Disease: (Autosomal Dominant disorder) (Goodman and Gorlin, 1977).

- Von Recklinghausen (1882) described this syndrome as being characterized by abnormal cutaneous pigmentation and numerous tumors developing in association with elements of both the central and peripheral nervous system.

Cardinal features

- Cafe-au-lait spots:
More than 5 spots >1.5 cm. in diameter.
- Axillary freckling.
- Dysplastic tumors - cutaneous and subcutaneous.
- Slowly progressive diseases with physical manifestation often present at birth.
- Pigmentation changes occur in 95% of patients.

Areas of hypopigmentation

- 1 % have giant hairy nevus.
- Neurofibromas increase in number and size and grow with age.
- Seizures, macrocephaly and hydrocephalus are relatively rare CNS complications.
- Tumors can involve any nerve, but risk of sarcomatous degeneration is low.
- It is considered to be a primary disorder of neural crest derivation.
- Pheochromocytoma and secondary hypertension are present in 1-5 % of cases.
- Skeletal manifestations include scoliosis as the most common developmental anomaly.

Hearing:

- Marked by bilateral acoustic neuroma.
- Both peripheral and central form.

- Mostly acoustic neuroma (rare in children; Fienman and Yakovac, 1970).
- Typically acoustic neuroma reported in second decade of life.
- Unilateral acoustic neuroma in 4th decade.
- Bilateral acoustic neuroma is hallmark of central neurofibromatosis.

Other biologic manifestations of neurofibromatosis

- Facial nerve neurofibroma .
- Meningioma.
- Stapes fixation by tumors of the perilymphatic space.
- Middle ear neurofibroma of Jacobsons nerve and Arnold nerve.
- Plexiform neurofibroma of the external ear (Holt, 1978).
- Vestibular dysfunction due to ataxia and tinnitus (Hughes, Sismanis, Jackson; 1982).
- Bilateral sensorineural hearing loss often asymmetric.

2. Fredrich ataxia

- Hereditary spinal ataxia.
- Recessive spino cerebellar degeneration.
- The gene affected is situated on chromosome.
- Symptom develops only at puberty.
- Nystagmus or other disturbances of eye mannerisms are noticeable - optic atrophy.
- Deafness less commonly seen.
- Flat feet
- Breathlessness and palpitations are the symptoms most usually felt by the young persons.
- ECG changes become obvious - left ventricular hypertrophy and T wave inversion - as condition progresses.
- Diabetes develops in significant proportion (20%) of population.
- (Sylvester, 1972 & Shanon, 1981).

3. Herrmann's Syndrome

- Nervous system disorder.
- Dominant inheritance.
- Photomyoclonic and grandmal epilepsy.
- Later course of syndrome includes personality changes leading to severe dementia.
- Slurring of speech, progressive hemiparesis and mild ataxia, renal disease and diabetes.
- Age of detectability is third or fourth decade.
- Progressive sensorineural hearing loss of late origin (Herrmann et. al.,1964).

4. Sensory radicular neuropathy

- Dominant trait.
- Nervous system disorder.
- Onset in late teens or early adulthood of lightning pains that involves distal extremities with painless ulceration of feet.
- Progressive moderate - to - severe sensorineural hearing loss.
(Mandell and Smith 1960; Stanley et. al., 1975)..

H) RENAL DISORDERS

a) Conductive hearing loss

1. Nephrosis urinary tract malformation.

- Sex linked or recessive transmission.
- Renal disorder with congenital conductive hearing impairment.
- Characterized by renal anomalies, nephrosis, digital anomalies, bifurcation of uvula.
- Congenital moderate to severe conductive type hearing impairment (Winter et. al., 1968).

2. Oto-Renal genital syndrome

- Recessive disorder.
- Renal anomalies and internal genital malformation.
- Malformation of middle ear with low set auricles and stenotic external canals.
- Moderate to severe conductive hearing loss (Winter et. al., 1968 ; Turner, 1970).

I) INTEGUMENTARY AND PIGMENTARY DISORDERS

a) Sensory Hearing Loss

1. Albinism Syndrome

- Most form being transmitted in autosomal recessive manner.
- Tyrosinase being defective.
- Different types of Albinism.
- Pigmental naen on the body & hair in coloured peoples may be yellow instead of white.
- A type of Albinism can be part of the clinical pattern of two further syndromes - Wardenburg's syndrome which is associated with deafness & 'Chediak — Higashi' syndrome which also has blood & immunological problems associated with the condition.
- Eyes alone can be affected (Ocular albinism) and this type is thought to be inherited in an X — linked manner.

2. Ectodermal dysplasia ; Ectrosyndactyly, Ectodermal dysplasia and cleft palate syndrome; Lobstor-claw syndrome (Fig 14).

- Integumentary and pigmentary disorder sometimes accompanied by congenital progressive sensorineural and / or conductive hearing loss.
- Depressed vestibular function.
- Abnormality of middle and inner ears has been described.
- Dominant transmission with poor penetrance and variable expressivity.

- Peculiar lobster - claw deformity of hands and feet, nasolacrimal obstruction and cleft palate & lip.
- Microcephaly and / or mental retardation present in about 20 % of cases. (Preus and Fraser 1973 ; Robinson et al., 1973 ; Pashayan et. al., 1974, Rodini (1992).

3. Kerato pachyderma and Digital Constrictions

- Integumentary disorder.
- Dominant trait.
- Hyperkeratosis involving the palms, soles, Knees and elbows.
- Ring like furrows developing on fingers and toes.
- Mild to severe congenital sensorineural deafness, mainly for frequencies above 4000 Hz, which may be of slowly progressive.
- May include renal disease (Bitici, 1975).

4. Leopard Syndrome (Lentiginosis, Lentiginosis - Deafness - Cardiopathy Syndrome) (Fig 15).

A complex hereditary syndrome involving skin, cardiac and other manifestations and with relatively typical facial dysmorphism.

Main Signs

- Multiple lentigines of the skin (dark brown up to 8 mm diameter), most common on the back of the neck and upper trunk (3-6) face, scalp, palms, soles and genitalia may also be affected. Mucous membranes not involved.
- Cardiac anomalies, usually mild pulmonary stenosis or subaortic stenosis or hypertrophic obstructive cardiomyopathy, with various electrocardiogram changes (e.g. conduction disorders).
- Hypertelorism and 'coarse' faces; large ears, pouring lips, prominent lower jaw.

Supplementary Findings

Growth and skeletal abnormalities : short stature; possible anomalies of thoracic shape (Pectus excavatum or carinatum), Winging of the scapula, kyphosis and generalized connective tissue laxity.

Genital dysplasia (cryptorchidism, hypospadias) or delayed puberty. Sensorineural hearing impairment in some patients. Mild mental retardation found in a few patients.

Manifestation : Lentigines present at birth or appear in the first years of life, increasing continuously in number. Hearing impairment may be congenital or of early onset, when present. Cardiac disorder according to severity.

Aetiology

Autosomal dominant disorder. Variable expression. Several sporadic *cases*.

- (Voron, Hatfield, Kalkhoff, 1976).

5. Onchyodystrophy

- Recessive integumentary disorder.
- Rudimentary finger nails and toe nails.
- Triphalangeal thumbs.
- Congenital sensorineural hearing loss (Goodman et. al., 1969).

6. Pili Torti

- Recessive integumentary disorder .
- Dry, brittle, flat, twisted hair of scalp, eyebrows and eyelashes.
- Moderate to severe bilateral sensorineural hearing loss (Singh & Bresman, 1973).

7. Waardenburg Syndrome - Type I & II (Fig 16).

Syndrome of facial anomalies, partial albinism & possible deafness.

Main Signs

- Lateral displacement of inner corner of the eyes. "Dystopia canthorum resulting in short palpebral fissures (2 & 3) of the lacrimal ducts both in type I & II and broad high nasal root and bridge (1-3), eyebrows, pronounced medially, possible synophrys, strands of white hair above the mid forehead (1,4) & other signs of partial albinism, in some patients. Congenital Sensorineural loss.
- Faced appearance may be distinctive.
- Apart from a white forelock, partial albinism may be manifest as Pale blue, colouring , heterochromic of the iris, depigmented areas of skin ; pigmen free strands of hair else where or the head on pigmentation anomalies of the retina.
- A relatively small cranium, thick heavy scalp hair with low anterior hairline, relative hypoplasia of the alae nasi, protrusion of lower jaw & full lower lip may be present.
- Hyperopia marcis, Gun Ptosis ; cleft lip & palate, occasionally combined with Hirshprung disease (in type I & II).
- Relatively short stature, diverse skeletal anomalies of upper extremities.
- Occasional Mentally retardation.

Aetiology

Inherited disorder, heterogenesis, mode of transmission for both types autosomal dominant with considerably variable penetrance & expression. High personal age favours new mutation.

- (Silva, 1991).

J) Miscellaneous Somatic Disorders

b) Sensory Hearing Loss

1. Trisomy 13

- Extra chromosome 13.
- Sever cognitive impairment and brain anomalies .
- Cleft lip, palate, micrognathia.
- Heart anomalies, genital anomalies .
- Poly dactyly.
- Microphthalmia, Hypertonicity.
- Renal anomalies, holoprosencephaly.
- Incompatible with life Shprintzen (1997).

2. Trisomy 18

- Chromosomal aberration extra chromosome at 18th pair.
- Under weight with an under nourished appearance.
- Possible limpness at first soon becoming hypertonic.
- Microcephaly with triangular shape due to occipital prominence and receding chin.
- Skin is loose.
- Flexion of hand with overlapping of index finger over third "rocker bottom" feet, short sternum, small pelvis and agenesis of bones of the extremities.
- Congenital heart disease, renal abnormalities cleft lip and palate, deformed ears may also be present.
- Mental retardation usually profound.
- Due to non disjunction of one chromosome in its 17-18 group.
- Possibility of recurrence in same family is rare unless translocation is present.

- Middle ear anomalies include malformed stapes, deformed incus and malleus, exposed stapedial muscle in the middle ear cavity, absence of stapedial tendon, absence of pyramidal eminence, a split tensor tympanic muscle in separate bony canal.
- Audiometric testing shows failure to respond to sound.
- Abnormal course of facial & chorda tympani nerves and underdevelopment of facial nerve.
- Atresia of external canals.
- Decreased spiral ganglion cells, anomalies of cochlea, absence of utriculoendolymphatic valve and absence of semi circular canals and cristae.
- By one year 90 % die (Smith, 1962, Kos et. al.,1966 ; Keleman et. al.,1968 ; Chrysostomidou et. al., 1971).

c) **Conductive Hearing Loss**

1. **Turner Syndrome (Xo Syndrome) (Gonadal Dysgenesis)**

Main Signs

- Chromosomal aberration not inherited.
- Short stature.
- Ovarian dysgenesis resulting in amenorrhea and infertility.
- Congenital lymphedema of neck, hands or feet.
- Neck webbing.
- Left sided heart defect or co-arcuation of aorta.
- Low posterior hair line.
- Widely spaced nipples/broad chest.
- Cubitus valgus.
- Dysplastic nails.
- Pigmented nevi.
- Narrow maxilla/palate/ and or cleft palate.

- Relative micrognathia.
- Sensorineural hearing loss.(mild to moderate).
- Anatomical deformities of auricles are low set ears, elongated ears, cupshaped ears, and thick ear lobes.
- Sensorineural hearing loss associated with Turner's syndrome is degenerative rather than congenital (Anderson et.al.,1971).
- Speech and language problems of both non-verbal and verbal areas including auditory verbal short term memory, receptive language skills and speech production deficit may occur.

K) Endocrine and Metabolic Disorders

a) Sensory Hearing Loss

1) Hyper Prolinemia I & II

- Recessive disorder.
- A biochemical phenotype.
- No proven association with clinical disease, although identified frequently in pedigrees containing renal disease or convulsive disorders.
- Metabolic problems.
- Hearing loss has been described as sensorineural in some individuals affected with type I disease(Schafer et.al.,1962).

2) Pendred Syndrome (Goitre and profound deafness)

- Recessive endocrine-metabolic disorder.
- The goitre is usually apparent by age 8 years but may be noted in birth in some cases.
- Auditory manifestations are variable but usually demonstrate a moderate to profound sensorineural hearing loss.
- Hearing loss is usually detected in the first 2 years of life and is almost always symmetrical.
- Risk of occurrence is about 1 in 14,500.

- Fairly common disorder related to profound deafness(Batsakis and Nishiyama,1962;Fraser 1965; Ilium et.al.,1972).

3) Sickle Cell anemia

- Hereditary dominant disorder.
- Middle ear anomalies include resorption of the body and long process of incus and the head of stapes.
- Haemolytic anemia, extramedullary haemopoiesis and hyperplastic bone marrow.
- Sensorineural hearing loss.

- (Morgenstien and Manace, 1969).

b) Sensory Progressive & Delayed Onset

1) Alport syndrome(Hereditary nephritis with nerve deafness)

- Autosomal dominant inheritance.
- Renal disorder associated with deafness and ocular anomalies.
- Men are mostly affected than females.
- Progressive nephritis with uremia, ocular lens abnormalities such as cataracts.
- Progressive sensorineural hearing loss.
- Hearing loss occurs in 40-60% of cases; ocular defects in 15%.
- Hearing impairment is typically mild to severe, high frequency, usually bilaterally symmetrical.
- May occur alone or in combination with renal disease.
- Age of onset of hearing loss is in pre-adolescence (Bergstrom et al., 1973, Rintelmann1976:Johnson and Arenberg 1981).

2) Amyloidosis, nephritis and urticaria (Mukle-Wells Syndrome)

- Inherited as autosomal dominant

- Onset in teens of recurrent urticaria (Vascular reaction of skin with elevated patches and itching) with malaise and chills with onset of recurrent limb and joint pain.
- Amyloidosis (Starchy like substance in the blood) precedes nephropathy and renal failure.
- Progression of hearing loss parallels progression of renal failure, resulting in severe hearing impairment by 3 or 4 decade of life.
- Endocrine and metabolic disorder with progressive SN hearing loss of late onset.

3) Hyper Uricemia

- Endocrine metabolic problem.
- Dominant transmission with variable expressivity.
- Slowly progressive ataxia beginning in 2nd decade.
- Renal insufficiency.
- Cardiopathy, myopathy, and gout have been noted.
- Progressive sensorineural hearing loss of late onset, usually high frequency in nature, may progress to total hearing loss with vestibular abnormalities (Rosenberg et.al., 1970).

c) Progressive Sensory and / or Conductive Hearing loss

1) Hunter Syndrome (Muco polysaccharidosis type II) (Fig 17)

A Muco polysaccharide storage disease exclusively in males and leading to a relatively typical facial dysmorphism, early hearing impairment, hepatosplenomegaly, short stature and generally severe Mental Retardation.

Main Signs

- Coarse facial feature similar to, but not as pronounced as in Hurler's disease, with broad low nose, hypertelorism full cheeks, thick lips and tongue, widely spaced teeth and macrocephaly (4&5). Impaired hearing

beginning in early childhood. Usually no corneal clouding, irritability, Mental Retardation or dementia.

- Short stature after transiently normal growth in the first year or two of life, short neck
- Joint contractures, claw hands (3), induration usually nodular, of skin and cartilage.
- Pes cavus. Hernias (1&2), diastasis recti, protuberent abdomen (2).
- Chronic suppurative, rhinitis, Hepatosplenomegaly. Heart :Valvular defects, enlargement, cardiac failure. Changes of bone form and structure as in Hurler syndrome. However, less severe at a given age. Pseudoarthrosis of the femoral head Increased intracranial pressure from impaired circulation of the CSF, seldom progressive.
- Increased heparin sulphate and chondroitin sulphate is detectable in the urine.

- (Young & Harpes, 1982).

Aetiology

X- linked recessive disease. Decreased activity of enzyme iduminale sulphatase results in storage of muco-polysaccharide in the cells of various organs and thus to anomalies of their functions and morphologies.

2) Hurler Syndrome (Mucopolysacchridosis Type I-II) (Fig 18).

- An autosomal recessive muco-polysacchride storage disease which leads to the development of typical facial dysmorphism, short stature, dementia, corneal clouding and hepatosplenomegaly.
- Hearing impairment.

Signs

- Characteristic faces with low, flat nasal bridge, broad tip of nose hypertelorism, exophthalmos, corneal clouding; thick pouting lips (1-4) large tongue, widely spaced teeth, hypertrophy of alveolar processes and

gums (8), Macrocephaly (6), abundant, thick scalp hair (1&2), increasing dementia.

- Growth deficiency after initial normal growth in early infancy, short neck, gibbus (4,6).
- Joint contractures (3), claw hands (7), broad stubby feet Indurations of skin and cartilage.
- Protruding abdomen diastasis recti, hernias.
- Chronic purulent, rhinitis, abundant laungo like body hair.
- Valvular defects, enlargement failure.
- Progressive changes of bony structure and form as in dysostosis multiplex; osteoporosis with coarse trabeculations, thickened skull, broad ribs and clavicles, crudly formed scapulae, oval and partly hook shaped vertebral bodies; broadening and shortening of the long bones (5). Dysplasia of pelvis.
- Intracranial pressure frequently increased due to interference with circulation of the Cerebro Spinal Fluid as a result of muco-polysaccharide deposits in the meninges.

Aetiology

Autosomal recessive disease. The above mentioned muco-polysaccharide are not degraded because of the absence of alpha iduronidase but are stored in various organs which leads to functional and morphological anomalies of these organs.

L) Eye Disorders

a) Sensory Hearing Loss

1) CHARGE Association (Oley, Baraitser, Grant, 1988 ; Gilbert, 1996)

- CHARGE is an Acronym for colomaba of the eye; Heart disease; Choanal Atresia; retarded growth; Genital hypoplasia; Ear abnormalities.
- Autosomal dominant and recessive modes of inheritance have been described.
- One or number of structures of the eye are missing.
- Gap in Iris or similar defect in the retina or other vital structures of the back of the eye. Eyelids can also be affected.
- Fallot's tetralogy, patent ductus arteriosus or a ventricular septal defect
- Choanal Atresia- one nostril will be affected.
- Discharge from one nostril and other nostril will be obstructed.
- By 6 months of age slowness of growth observed.
- Small penis.
- Triangular shape ears or small ears mild to profound conductive or sensorineural hearing loss.
- Learning disability ranging from mild to severe seen.
- Lower jaw and or a cleft lip or palate are the commonest facial features.

2) Hallgren syndrome

- Recessive transmission.
- Eye disorder.
- Congenital sensorineural hearing loss.
- Retinitis pigmentosa, progressive ataxia and mentalretardation in 25% of cases.
- Some patients show later Psychosis.
- 90% have profounddeafness (Hallgren, 1959).

3) Laurence-Moon-Biedl-Bardet syndrome

- Recessive inheritance.
- Eye disorder with progressive sensorineural hearing loss.
- Retinitis pigmentosa, mental retardation, hypogenitalism and spastic paraplegia.
- Obesity and retinitis pigmentosa in association with Polydactyly hypogonadism and mental retardation(Weinstein et.al.,1969; Konigsmark &Gorlin, 1976).

4) Usher syndrome

- Recessive, genetic condition including congenital deafness and progressive loss of vision leading to eventual blindness.
- The hearing loss is bilateral, moderate to severe and sensorineural.
- Patient initially notices difficulty seeing at night during early teens or twenties; narrowing of visual field (tunnel vision).
- Signs and symptoms of retinitis pigmentosa.
- May have additional disorders such as mild retardation, vertigo, psychosis, loss of smell, abnormal electro encephalograms and epilepsy.
- Prevalence among profoundly deaf children has been estimated to be between 3% and 10%.
- Abnormal vestibular responses.
- Severe bilateral congenital deafness, where 10% had moderate(30-70 dB) sensorineural hearing loss, more marked in higher frequencies or profound deafness.
- No treatment for retinitis pigmentosa (Kloepfer et.al., 1966, McLeod et.al.,1971; Hicks &Hicks,1981).

b) Conductive Hearing Loss

1. Cryptopthalmia

- Eye disorder.
- Recessive transmission.
- Adherent eyelids that hides the eyes.
- Accompanied by external ear malformations.
- In its most severe form, unilateral or more often, bilateral extension of skin of the forehead completely covers eye or eyes to the cheeks.
- In less severe form, the upper or lower eyelid may be present.
- Laryngeal atresia has been reported.
- Cleft lip and palate are not uncommon .
- Hearing loss is of mixed type, with atresia of external auditory canal (Fraser, 1962 ; Ide and Wollschlaeger, 1969).

2. Duane - retraction Syndrome (Pfaffenbach et. al., 1972)

- Autosomal dominant inheritance.
- Some cases seem to be inherited recessively & to be X-linked.
- Thalidomide is also implicated in the etiology of this disorder.
- External and middle ear anomalies include microtia, atresia of the external auditory canal, fusion of the ossicles, lack of contact of the fused ossicles with the oval window, closure of the oval window by thin membrane .
- Ossicles mass that does not connect to the stapes.
- More frequent in females.
- Limitations or absence of abduction, restriction of abduction, retraction of the globe upon abduction and narrowing of palpebral fissure on adduction.
- Condition is usually unilateral.
- The hearing loss is said to be conductive.

c) Sensory and /or Conductive Hearing Loss

1. Mobius Syndrome (Fig 19)

(Autosomal dominant and autosomal recessive transmission , heterogeneity, pleiotropism, internal intra familial variability).

A clinical picture comprising congenital, generally bilateral cranial nerve palsy with malformations of extremities.

Main Signs

- Expressionless face, disorder of drinking, swallowing and speech, strabismus and ptosis of lips (1-3) due to congenital defect of following cranial nerves, most frequent facial and abducent, nerves, less frequently the Oculomotor and Hypoglossal nerves, Glossopharyngeal, Trochlear and Trigeminal nerve.
- Unilateral and bilateral club feet in 1/3 of patients.
- Various heart anomalies, usually symbrachydactyly, also with ipsilateral aplasia of the pectoralis muscle, terminal transverse defect, stiff index finger.
- Ear anomalies, ear of different sizes and protruding cartilage anomalies, deafness.
- Aplasia of Lacrimal puncta,
- Occasional MR (approximately 10 % of cases) mild in most cases.
- Microstomia, micrognathia, short palpebral fissures, bilateral epicanthus, hypertelorism, bifid uvula, cleft palate, rib defects, Klippel-Feil anomalies, hypogonadism..

- (Kumar, 1990).

d) Progressive Sensory and Delayed Onset

1. Harboyan Syndrome (Fehr's corneal dystrophy)

Autosomal recessive transmission

The combination of congenital corneal dystrophy and progressive SN loss was described in two of ten sibs from another first cousin mating and in one of ten sibs from another first cousin mating by the same father (Harboyan et al., 1971).

Characteristics

- Congenital dystrophy with slow progression.
- No external or middle ear abnormalities are described.
- Slowly progressive Sensorineural loss .
- Speech discrimination score - 90 % to 100 %.
- SISI and Tone decays were negative .
- Calorie vestibular tests are normal.

2. Flynn Aird Syndrome

- Dominant transmission with variable expressivity.
- Eye defects including myopia, cataracts and retinitis pigmentosa,
- Peripheral neuropathy with shooting pains, SN loss and weakness.
- Skeletal abnormalities including Kyphoscoliosis .
- CNS involvement including peculiar seizures and abnormal EEG findings.
- External, middle and inner ear abnormalities.
- Bilateral sensorineural hearing loss (slowly or moderately progressive).

3. Noorie's Syndrome (oculoacoustics cerebral degeneration)

- X-linked recessive.
- Progressive eye degeneration leading to total blindness.
- 1/3rd are severely MR and 1/3rd are mildly retarded and 1/3rd are of normal intelligence.

- Auditory impairment is progressive of late onset and usually bilaterally symmetric Sensorineural loss in one third of cases (Holmes, 1971).

4. Refsum's Syndrome

- Recessive mode of transmission .
- Onset in second decade with visual loss, night blindness due to retinitis pigmentosa.
- Progressive ataxia, muscle wasting, obesity, Ichthyosis and polyneuritis.
- Peripheral neuropathy.
- Sensorineural progressive hearing loss (50 %) with one side often worse than the other (Fryer et. al., 1971 ; Nance, 1973).

CHROMOSOMAL ABERRATIONS

Numerical

- Trisomy 13, 18 & 21 (Down)
- Turner

Structural

- Cri-du Chat
- Di George Sequence
- Prader Willi
- Wolfe-Hirsh horn

Multifactorial Inheritance

(Single or Multiple gene abnormality with possible non-genetic environmental factors)

- Cornelia de Lange
- Di George Sequence
- Golden haur
- Klippel Feil
- Pierre-Robin Sequence
- Wilder Vanck Syndrome

CHROMOSOMAL SYNDROMES (Robert J. Shprintzen, 1997)

I.3q +

- Duplication of 3q.
- Severe cognitive deficiency, full eyebrows, heart anomalies, CNS malformations.

- Upslanting eyes, microcephaly.
- Irregular skull shape, cleft palate, short neck.
- Minor hand anomalies, Early death is common.
- Conductive hearing loss, probable secondary to clefting and chronic infections.

II 4p - (*Wolf Hirschhorn Syndrome*) - Deletion of variable size at 4p16.

- Low birth weight, hypotonia, severe cognitive deficiency.
- Developmental delay, seizures, strabismus, and high arched eyebrows.
- Ptosis, Iris Coloboma, prominent nasal root craniofacial asymmetry, eartags, absent ear, heart anomalies, cleft palate & cleft lip.
- Micrognathia, Robin sequence, Kidney anomalies, Early death common.
- Conductive loss probably common.

III. 4q -

- Deletion of portion of long arm of chromosome 4.
- Cognitive deficiencies of variable severity heart anomalies, Short nose.
- Low set posteriorly rotated ears.
- Cleft palate and cleft lip, telecanthus, limited elbow extension.
- Overlapping toes, minor auricular anomalies.
- Early death common.
- Possible conductive hearing loss, secondary to chronic otitis media in cases with clefts.

IV.4q +

- Partial trisomy of long arm of chromosome 4.

- Cognitive deficiency, heart anomalies, renal anomalies.
- Microcephaly, posteriorly sloping forehead.
- Down turned oral commissures, minor auricular anomalies.
- Posteriorly rotated ears, umbilical hernia, inguinal hernia, minor hand & foot anomalies.
- Occasional conductive hearing loss.

V. 5P - : (*Cri-du-chat Syndrome*)

- Deletion of a segment of short arm of chromosome 5 at P¹⁴ ---• P¹⁵
- High pitched cry in infancy, small stature, severe cognitive deficiency, several hypotonia, microcephaly.
- Orbital hypertelorism, downslanting eyes, posteriorly rotated ears, ear tags, prominent nasal root.
- Micrognathia, heart anomalies, inguinal hernia.
- Dislocated hips, failure to thrive with feeding difficulty .
- Large bowel malrotation, small hands with joint contractures.
- Occasional cleft palate and / or cleft lip.
- Conductive hearing loss is common, secondary to chronic otitis media in most cases.

- (Niebuhr, 1978).

VL 6q-

- Deletion of a portion of long arm of chromosome 6.
- Severe cognitive deficiency, microcephaly, upslanting ears.
- Cleft palate, micrognathia, possible robin sequence, respiratory difficulties in infancy, hand anomalies, nail anomalies of finger with

nails growing cut of both the palmar & dorsal surface of the digits, heart anomalies.

- Possible conductive hearing loss secondary to chronic otitis media.

VII.6q +

- Trisomy of a portion of the long arm of chromosome 6.
- Severe cognitive deficiency, microcephaley, short stature, cleft palate and / or cleft lip, prominent fore head.
- Down slanting eyes, down turned oral commissures, low set ears, joint contractures, scoliosis, heart anomalies, genital anomalies .
- Possible conductive hearing loss secondary to chronic otitis media.

VIII. 7P -

- Deletion of a portion of short arm of chromosome 7.
- Variable cognitive deficiency, microcephaley, craniosynostosis, cranial asymmetry, low set ears, depressed nasal root, heart anomalies, genital anomalies, occasional cleft palate.
- Possible conductive hearing impairment secondary to CSOM in cases with clefts.

IX.7P +

- Trisomy of a portion of the short arm of chromosome 7.
- Severe cognitive deficiency, hypertelerism, micrognathia, cromosynostosis, choanal atresia, talipes equinovarus, occasional cleft palate.
- Possible conductive hearing loss secondary to clefting.

X.7q-

- Deletion of a portion of short arm of chromosome 7.
- Severe cognitive deficiency, small stature, prominent fore head, cleft palate and / or cleft lip, severe hypotonia, heart anomalies, micropenis, hypospadias, occasional holoprosencephaly.
- Possible conductive hearing loss secondary to clefting.

X.7q +

- Partial trisomy of long arm of chromosome 7.
- Cognitive deficiency, small stature, prominent fore head, short nose, cleft palate, early death is common.
- Possible conductive hearing loss secondary to clefting .

XII.8P +

- Trisomy of a portion of short arm of chromosome 8.
- Severe cognitive deficiency, absent corpus callosum.
- Heart anomalies, genital anomalies, cleft palate.
- Frontal bossing, depressed temporal region, round face, down turned oral commissures, short neck.
- Possible conductive hearing loss secondary to CSOM in cases with clefts.

XIII.9P-

- Deletion of a portion of short arm of chromosome 10.
- Cognitive deficiency, trigonocephales, hypertelorism, upslanting eyes, microstomia, ear lobe anomalies, heart anomalies, webbed neck,

micrognathia, omphalocele or umbilical hernia, inguinal hernia, arachnodactyly, occasional cleft palate.

XIV.9P +

- Trisomy of a portion of short arm of chromosome 9.
- Broad forehead, hypertelorism, large nasal tip, macrostomia.
- Large ears, short neck, cognitive deficiency, finger joint contractures.
- Minor skeletal anomalies, delayed bone age, delayed closure of anterior frontal, strabismus, heart anomalies.
- Occasional cleft palate and / or Cleft lip.
- Possible mild conductive hearing loss secondary to clefting & narrow external ear canals.

XV. 10 q +

- Trisomy of a portion of long arm of chromosome 10.
- Severe cognitive deficiency, heart anomalies, renal anomalies, small stature, cleft palate, micrognathia.
- Possible robin sequence, prominent fore head.
- Arched eye brows, epicanthi, finger contractures, cryptochidism .
- Possible conductive hearing loss secondary to chronic otitis media in cases with clefts.

XVI. 12 P + (12 P tetrasomy)

- Tetrasomy of portion of short arm of chromosome 12.
- Severe cognitive deficiency, respiratory disorders, small stature, hypotonia, sparse hair.

- Coarse facial features, high forehead, fleshy auricles, short neck, supernumerary nipples.
- Sensorineural hearing loss.

XVII. 14q +

- Trisomes of portion of long arm of chromosome 14.
- Cognitive deficiency, small stature, cleft palate, micrognathia, possible Robin sequence.
- Down turned oral commissures, hypogonadism, heart anomalies.
- Pulmonary anomalies.
- Possible conductive hearing loss secondary to chronic otitis media in case with clefts.

XVIII. 16q-

- Deletion of portion of long arm of chromosome 16.
- Cognitive deficiency, Small stature, hypotonia, microcephly, high forehead with metopic ridging.
- Occasional cleft palate, micrognathia.
- Possible robin sequence, small appearing eyes, short neck, polydactry, occasional heart anomalies.
- Possible conductive hearing loss secondary to clefting and CSOM.

XIV.18P-

- Deletion of portion of short arm of chromosome 18.
- Cognitive deficiency, small stature, microcephaly, maxillary deficiencies, telecanthus, strabismus.
- Down turned oral commisure, retrognathia, short neck, micropenis, cryptorchidism.

- Occasional cleft palate and cleft lip, occasional heart anomalies.
- Hearing normal except for cases with chronic otitis media secondary to clefting.

a) Numerical

1. Trisomy and 21 (Down's syndrome), Mongolism, Mongoloidism (Fig 20)

A malformation syndrome comprising mental retardation and very characteristic physical appearance.

Signs

- Flat face with mongoloid slant of the palpebral fissures, epicanthus, low nasal bridge, small nose and dysplastic external ears (1-8, 12-14) with short cranium and steeply sloping occiput (14). Macroglossia (Frequently with fissured tongue) dysodontiasis.
- Short opening neck with loose skin (more apparent in the young child). Relatively short stature. Short stubby hands and fingers with frequent clinodactyly of the little fingers and simian crease of the palms (15) 'Sandal gap' between the first two toes (13,16).
- Muscular hypotonia and generalized hypennobility of the joints with laxity of the ligaments (9-11), Atlanto-axial instability in 5-20%.
- MR-mod-severe.
- Of all Down patients 80 % develop microcephaly from the 6th month of life (More frequent in females) 20 % of patients are in the lower normal range in 20-50 % there is a reduction of cortical neurons area (10,17,22). Usually in the granular layers . Prenatal retardation of neurogenesis and prenatal and postnatal retardation of synaptogenesis .
- Cardiac defects in almost one half of the patients mild exophthalmos, strabismus, nystagmus. Small white 'Porcelain' spots in the still pale-

coloured iris of young infant; Occasional cataracts, myopia of greater than 5D in 25 % duodenal atresia or stenosis in 1-2 % of patients.

- Hypoplasia of pelvis with flaring of ilia and abnormally small angle between the ilium and the root of acetabulum on radiograph. Relatively small penis and frequent cryptorchidism (10).
- Tendency to localized redness of cheeks and nose (6), dryness of skin, cutis marmorata and constipation, above average frequency of thyroid dysfunction - (Cronk, Crocker, Pueschel, 1988).
- Hearing defects in 78 % of which more than 50 % are conductive hearing disorders, 15 % labyrinthine deafness, 10 % combined hearing defects.

Aetiology

- It is the expression of chromosomal aberration, namely, a trisomy of chromosome 21 or disturbance of genetic equilibrium caused by a three fold dose of the genetic material located in this chromosome.
- Increased maternal age.

- (Baird, Sadovnick, 1989)

b) Structural

1. DiGeorge's Syndrome (3rd & 4th pharyngeal pouch syndrome).

- Include immune deficiencies and hypocalcemia due to dysplasia of thymus and parathyroid, conotruncal heart defects and distinctive facial features including wide spaced eyes, a small chin and blunt tip of nose. There can be external and middle ear malformation and Mondini malformations are frequent.
- Due to deletion of a particular part of the long arm of chromosome 22, designated 22q11.2 although about 10% may be due to other causes, such as deletion of the short arm of chromosome 10.

It is possible that the cases of DiGeorge's syndrome with Mondini malformation have a cause other than deletion at 22q11.2.

- (Adkins and Gussen, 1974).

c) Multifactorial Inheritance

(Single or multiple gene abnormality with possible non-genetic environmental factors)

1. Cornelia de Lange Syndrome

Polygenetic multifactorial syndrome characterized by severe to profound mental and growth retardation, hirsutism, microcephaly, confluent eye brows often accompanied by anomalies of external ear including low set auricles and small external auditory canal.

- Severely malformed upper limbs, may have missing toes or finger and possible webbing between toes.
- Cardiac defects are common ; possible cleft palate accompanied by neonatal feeding and respiratory difficulties.
- Speech and language problems are severe and hearing loss attributed to conductive sensorineural and mixed etiologies has been reported.
- Prognosis is poor with diminished life expectancy (Silver 1964 ; Moore 1970 ; Fraser and Campbell 1978).

2. Golden Hair Syndrome (Golden hair anomalies, Golden hair - Gorlin syndrome, oculoauriculovertebral dysplasia) (Fig 21).

A very variable but relatively characteristic malformation complex of eye, ear, nose and in some cases, vertebral anomalies.

Signs

- Often marked facial asymmetries due to unilateral hypoplasia (2&4); usually prominent forehead (1&4), hypoplasia of zygomatic region and of mandible, receding chin.

- Epibular dermoid can lipodermoid (usually occurring bilaterally on lateral comeoscleral junction) Coloboma of the upper lid (usually unilateral)
Occurance also of the other ocular anomalies.
- One or more pre-auricular tags, unilateral or bilateral on a line between the tragus and corner of mouth. Blind fistules may also be located here. As a rule, microtia or other malformatons of external ear (7a).
- Frequent unilateral macrostoma due to a transverse molar cleft.
- Usually marked malformation(often hemivertebrae) of the (especially upper) spine; Frequently demonstrable only by radiograph occasionally scoliosis.
- Possible cleft lip/ or palate.
- Frequent dental anomolies.
- Possible conductive hearing defect.
- Occassionally MR.
- Lipoma of corpus callosum may occur.
- Cardiac pulmonary and other anomolies also possible.

Aetiology

- A causally heterogenous and complex developmental field defect in with the manifestation vary markedly in severity .Usually sporadic occurance (in some case based on in utero interfarence of blood supply).
- Evidence for autosomal dominant as well as for autosomal recessive inheritance.
- Majority affected are males.
- Sibling risk is about 6%..

- (Setzer and Ruiz - Castaneda, 1981).

OTHER SYNDROMES ASSOCIATED WITH HEARING LOSS

Prader willi syndrome

- Deletion of 15q 11-13 from paternal chromosome or paternal 15q11 disomy.
- Obesity, insatiable appetite, hypoplastic gonads.
- Cryptorchidism, hypotonia, cognitive deficiency.
- Small hands and feet.
- Delayed speech onset; articulatory impairment secondary to hypotonia.
- Hypernasality secondary to hypotonia which resolves with age.
- Occasional hearing deficit.

Wilder vanck syndrome (cervico-oculo-acoustic syndrome) (Fig 22).

A complex of anomalies including short neck facial anomalies and hearing impairment, occurring almost exclusively in females.

Main Signs

- Usually facial asymmetry, possibly with torticollis, uni or less frequently bilateral paralysis of the abducent nerve and bulbar retraction (Duane syndrome). Hypoplasia of the upper jaw, micrognathia, narrow or possible cleft palate.
- Unilateral or bilateral moderate to severe, conductive hearing impairment, sensorineural loss or combination of two. Occurrence of outer and inner ear malformation, Pre-auricular tags, malformed ears, atresia of external auditory canal, malformed or absent ossicles, hypoplasia of labyrinth.

Supplementary findings

- Mental development normal as a rule.
- Unilateral epibulbar dermoids may occur.

- Spina bifida occulta, Sprengel's deformity, hemivertebrae, anomalies of the ribs, kyphoscoliosis.
- Sex linked dominant inheritance.

Gorlin-holt syndrome (Fronto metaphyseal dysplasia).

This entity is thought to be due to failure to absorb secondary spongy bone, and a number of features distinguish it from cranio metaphyseal dysplasia.

- May be sporadic or may result from a rare autosomal recessive gene.
- Severe over growth of supraorbital ridges, especially laterally, agenesis of frontal sinuses.
- Hypodevelopment of mandible.
- Defective dentition.
- High arched palate.
- Decreased vision.
- Conductive or mixed hearing loss.
- Hirsutism, winged scapulae, flaring of iliac bones, a limited range of motion of joints.
- Poorly developed muscles and normal intelligence (Gorlin et al. 1976).

Saethre-Chotzen syndrome (Acs type IE, Acrocephalosyndactyly type Chotzen syndrome).

Inherited autosomal dominant condition.

A syndrome comprising acrocephaly, relatively characteristic facies, mild to moderate syndactyly of the hands and feet and possible mental retardation.

Main Signs

- Relatively mild acrocephaly with a broad forehead.

- Face often markedly asymmetric. Frequently low anterior hair line. Hypertelorism, broad flat nasal bridge, anti mongoloid slant of palpebral fissures, often highly arched eyebrows, possible mild exophthalmus.
- Ptosis (or blepharochalasis) strabismus. Tear ducts may be narrowed, dystopia canthorum.
- Beak like curve of the nose with deviated septum.
- Possibly low set ears.
- Hypoplasia of the maxilla, narrow palate, prognathism.
- Relatively short stubby fingers (frequently with inturned little finger); exclusively soft-tissue syndactyly between the proximal segments of digits II and III but also other digits.
- Normal number of fingers and toes; normal thumbs and big toes. Cutaneous syndactyly of the toes.
- Frequently MR also in combination with neurological or psychological anomalies frequently, mild hearing impairment, small stature.
- Possible Cryptorchidism (Friedman and Hanson 1977).

Pfeiffer syndrome Acs type V (Acrocephalosyndactyly type Pfeiffer).

Inherited as autosomal dominant condition.

- Acrobrachy cephalo.
- Face broad with a flat profile, hypertelorism, broad low nasal bridge, antimongoloid slant of palpebral fissures, high arched palate and small upper and in some cases, lower jaw.
- Halluces and thumbs stubby, broad and short and usually deviated, various degrees of soft tissue syndactyly, usually between digits II & III.
- Mild to moderate hearing impairment (Saldino et al. 1972).

Charcot-Marie-tooth syndrome; Nephritis & SN deafness (*Lemeux-Neemah syndrome*).

It is not clear whether the syndrome is transmitted in recessive or dominant mode.

Characteristics

- Characterized by Proteinuria and microscopic hematuria is present in all affected individuals.
- Distal muscle atrophy begins in childhood and is slowly progressive. Associated with progressive weakness, which produces difficulty in walking and in holding objects. Ackward gait with bilateral foot drop but no true ataxia. Triceps and biceps reflexes will be active, but knee & ankle jerks will be absent
- Hearing loss begins in childhood and is slowly progressive. In latter there will be moderate hearing loss more marked in higher frequencies.

Cowden syndrome

- Autosomal dominant disorder.
- Multiple hamatoma.
- Neuromas.
- Polyps, goiter.
- Breast lesions, papillomas on lips and tongue.
- Occasional sensorineural hearing loss.

Keutel syndrome (Fig 23).

Autosomal recessive disorder.

A characteristic syndrome of brachytelephalangism, abnormal cartilage calcification, impaired hearing and distinctive appearance.

Main Signs

- Abnormally short distal phalanges of fingers (4).

- Abnormal calcification of cartilage in the trachea bronchial tree, in the epiphyses of long bones and in the nose and ears (3).
- Hearing defect of mixed or conductive nature.
- Facies characterized by hypoplasia of mid-face with abnormally shaped nose (1&2).
- Increased susceptibility to infections of respiratory tract, bronchiectasis or bronchial asthma. Anomalies of the cardiovascular system MR and short stature. (Cormode, Dawson and Lowry 1986).

Hajdu-cheney syndrome (Idiopathic osteolysis, Hajdu-cheney type) (Fig 24).

A syndrome of characteristic facies, persistence of cranial suture and fontanelles hyperextensible joints increased tendency to fracture, premature loss of teeth and acroosteolysis or radiograph.

Main Signs

- Characteristic facies broad strikingly heavy eyebrows, maxillary and mandibular hypoplasia, broad philtrum, broad thin lipped mouth (1), coarse thick scalp hair.
- Cranial anomalies, persistence of fontanelles and sutures; eventual development of dolichocephaly without protruding occiput.
- Joint laxities, usually short stature with short neck, tendency to pathological fracturing carious teeth.
- Short broad tips of the fingers and sometimes of the toes, which may be tender or pointed and possibly associated with nail deformities.
- Coarse skin in some patients with hypertrichosis, hoarse voice common possible conductive loss possible defective vision or other age anomalies osteolysis in particular acro-osteolysis with formation of typical transverse clefts of distal phalanges of the fingers (3&4).

Aetiology

Autosomal dominant gene is apparently responsible predominantly sporadic occurrence (as new mutations).

Kearns-sayre syndrome- (multisystem disorder) *{Progressive external ophthalmoplagia plus}* (Fig 25).

A mitochondrial encephalomyopathy with chronic progressive external ophthalmoplagia and further neuro muscular defects, intra cardiac conductor defect tapetoretinal degeneration and characteristic appearance.

Main Signs

- Chronic progressive external ophthalmoplegia (1&2).
- Disorder of intra cardiac conduction or bundle branch block
- Pigmentary degeneration of the retina.
- Characteristic appearance, especially typical faces (1&2).
- Many different defects of the central and peripheral nervous system..
- Optic atrophy and hearing impairment and vestibular defect.
- Cerebellar ataxia, pareses and pyramidal signs.
- Myopathy of proximal skeletal musculature.
- Increased protein and some times cell count in the spinal fluid, electroencephalogram change.
- In some patients, signs of spongy degeneration of brain on computerised axial tomography.
- Poor intellectual development or MR.
- Electromyographic evidence of generalised myopathy, on muscle biopsy, characteristic ragged red fibres.
- Possible hypogonadism, hypoparathyroidism, diabetes mellitus and renal dysfunction.
- Considerable short stature.

- Lax posture, poor musculature, frequent secondary kyphoscoliosis, Hyper lordosis, frequent wasting and typical faces all contribute to the characteristic general appearance.

Aetiology

Mitochondrial inheritance has been postulated Mitochondrial deletion.

Autosomal dominant and recessive-heterogeneity (Norby, 1994).

Lacrimo-Anriculo-Dento-Digital syndrome (LADD syndrome) (Fig 26).

A syndrome of hypoplasia, aplasia or atresia involving the lacrimal system ear anomalies and hearing impairment, aplasia or atresia within the salivary system and anomalies of teeth and fingers.

Main Signs

- Epiphora or deficiency of tears as a result of atresia hypoplasia or aplasia of the lacrimal apparatus.
- Malformed external ears; possible hearing impairment
- Dryness of mouth with eating difficulties because of hypoplasia or aplasia of the large salivary glands or absence of duct openings.
- Possibly hypoplasia or aplasia of the teeth or other anomalies of dentition.
- Diverse anomalies of fingers; usually of the pre-axial rays.(e.g. hypoplasia of the thumbs, bifid thumbs).
- Irritation of ocular and oral mucous membrane possible candidiasis. Early development of dental caries, possible severe and leading to total loss of teeth. Additional renal anomalies optimal, mild facial anomalies.

Aetiology

Autosomal dominant disorder with less variable expression.

Short Syndrome

Autosomal recessive inheritance.

Main Signs

- Short stature with intrauterine growth retardation.
- Hyper extensibility of the joints or inguinal hernias.
- Deep set eyes megalocornea.
- Rieger anomaly.
- Delayed dentition.
- Slow weight gain after birth.
- Feeding problem in first two years.
- Recurrent infections, triangular face, telecanthus, broad nasal bridge, prominent forehead, head circumference around tenth percentile, hypoplastic alae nasi, micrognathia. deficient subcutaneous tissue, hearing impairment, delayed bone age, delayed development of speech, normal intelligence (Lipson, Cowell, Gorlin, 1989).

Hemifacial microsomia (Fig 27).

A clinical picture comprising unusual facial asymmetry with unilateral malformation of the ear and ipsilateral hypoplasia, especially of the mandibular ramus and condyle.

Main Signs

- Variable degrees of facial asymmetry caused by unilateral hypoplasia of jaw and receding chin (1-3).
- Pre-auricular tags or abnormality of external ear aplasia (2) in some cases.
- Mouth occlusion on the affected side.
- Possible hearing impairment.
- Anomalies of eye on affected side of the face.
- Radial anomalies (e.g. Triphalangeal thumb) could constitute a separate entity.

Aetiology

Sporadic occurrence as a rule (recurrence risk in first-degree relatives approximately 2-3%) (Rollnick & Kaye 1983).

Coffin-Lowry syndrome

- X-linked disorder.
- Narrow, rectangular protruding forehead appearing bitemporally compressed. Coarse, straggly scalp hair, prominent supra-orbital ridges, hypertelorism. antimongoloid slant of the palpebral fissures, pronounced eyebrows, thick upper eyelids. Sometimes ptosis, broad nasal bridge and short broad plug nose with a thick septum and alae, pouting lower lip, prognathism mouth usually open hypodontia, dysodontiasis and large fleshy ears.
- MR, (IQ usually below 50) in males.
- Frequently hearing defects.
- Increased susceptibility to seizures.
- Small stature, of varying degrees, height possibly below the 3rd percentile.
- Full forearms.Plumpish, lax, soft hands with tapered, hyperextensible fingers. Short halluces (Wilson and Kelly 1981).

Telfer syndrome

- Autosomal dominant transmission.
- Congenital piebaldness.
- Ataxia or co-ordination difficulties in about 80%.
- Mental retardation in about 80 %.
- Asymmetric SN hearing loss in about 60%.
- Hearing normal in one ear and other ear showing moderate deafness.
- Some exhibits mild loss in one ear & profound deafness in the other.
- Hearing loss appeared to be progressive.

Baller-Gerold syndrome (Fig 28).

Autosomal recessive inheritance with 1:1 sex ratio.

Signs

- Intrafamilial variability.
- Congenital deafness.
- Hydrocephalus seizures.
- Premature craniosynostosis depending on this, they may develop oxy cephalos palgiocephaly, clover-leaf deformities.
- Club hand, Oligodactyly with unilateral/bilateral aplasia or hypoplasia of the thumb; metacarpels and carpels are fused, hypoplastic or absent.
- Post axially bowed ulna and fifth finger clinodactyly not unusual.
- Facial dysmorphism.
- Epicanthus medialis, hypertelorism, prominent nasal bridge, low set ears with dysplastic helices, micrognathia, prognathia, cleft palate, bifid uvula choanal stenosis.
- Skeletal anomalies : lordosis, anomalies of lateral bodies, limited mobility of shoulder, elbow and knee joint fused ribs, abdominal anomalies.
- Cardiac anomalies: Ventricular septal defect, patent ductus arteriosus tetralogy of fallot, valvular aortic stenosis.
- Renal : pelvic kidney, renal ectopy, unilateral agenesis, hydronephrosis, rectovaginal fistula.
- Anal- ventrally displaced anus, cutaneous anal stenosis, perineal fistula.
- Neurological signs- Psychomotor retardation rare; secondary as a result of premature synostosis. Pofymicrogyria, thin or absent hypoplastic corpus callosum, hypoplastic rhinencephalon.

Freeman-Sheldon syndrome (craniocarpotarsal dysplasia, Whilsting face syndrome) (**Fig 29**).

Autosomal dominant, X-linked recessive transmission also possible Heterogeneti. A highly characteristic syndrome with mask like whilsting face, hypoplastic alae nasi, ulnar deviation of hands, fiesuar contractures of fingers and club feet

Signs

- Face round full cheeked mask like immobility with deep set, relatively widely spaced eyes narrow palpebral fissures with slight antimongoloid slant, convergent strabismus, wide, low set nasal bridge epicanthus, small nose with hypoplastic alae nasi, long philtrum and small mouth which is difficult to open with distinctive pursed lips as though whilsting.
- Ulnar deviation of hands and flexion contracture of fingers, especially the thumbs. Club feet wit contractures of toes.
- Transverse ridge across the lower fore head or supra orbital soft tissue furrow. Ptosis in some cases, high palate usually no cleft.
- Hearing impairment.
- Short neck, usually markedly short strature.
- Development of marked scoliosis (Wang& Lin 1987).

Langer-Giedian syndrome (Syndrome of Acrodysplasia with exostoses) (**Fig 30**).

A malformation retardation syndrome of short stature, unusual faces, sparse fragile scalp hair, multiple exosotoses, mild microcephaly and mental retardation.

- Typical facial dysmorphism : Large, prominent poorly differentiated ears, broad upward slanting eye brows, deepset eyes, bulbous nose with a broad septum and simple alae, long phillrum, long narrow upper lip, high palate mal occlusion receding chin.
- Fine scalp hair.
- Mild microcephaly and mild to moderate MR.

- Flaccid or loose, wrinkled skin and muscular hypotonia.
- Later maculopapular pigmented naevi especially on the upper half of the body.
- Multiple cartilaginous exostoses of long tubular bones (also possibly on short tubular bones, the shoulder blades, ribs and pelvis).
- Cone shaped epiphysis of hands and feet.
- Optic defect, SN hearing loss and delayed speech development.
- Increased susceptibility to infections.
- Generalized hyper extensibility of joints, abnormal nails (Brenholtz, 1989).

Antley-Bixler syndrome

Autosomal recessive inheritance.

A craniostenosis syndrome with severe midface hypoplasia proptosis, humeroradial synostoses and choanal atresia.

Main Signs

- Craniofacial signs: Branchy cephal, prominent forehead proptosis, mid face, hypoplasia, dysplastic ears, deep nasal bridge, choanal atresia/stenosis, craniosynostosis.
- Extremities : Camptodactyly long hands and fingers, multiple joints contractions impaired extension / flexion of elbow, supination possible in some cases.
- Stenosis of external auditory canal conductive hearing and inner ear disorder.
- Respiratory impairment due to choanal stenosis.
- Flat thorax flat pelvis, Rocking chair feet.
- Partial cutaneous syndactyly.
- Hypoplastic, labia, fused labia minora, large clitoris.
- Renal duplication, hydronephrosis uteroobstruction (Dawn De lozier-Blanchet 1989).

ABCD syndrome (Fig 32).

Autosomal recessive inheritance. An Autosomal recessive syndrome of neural crests with albinism, black block, cell migration disorder of neurons of gut and deafness.

Main Signs

- Occulo cutaneous albinism.
- Persistence of black strands of hair.
- Sensorineural defects.
- Total aganglionosis of large intestine, total absence of neurocytes and nerve fibres from the entire small intestine.
- Polycythaemia, absence of peristalsis, vomiting.
- High haematocrit.

Rubella syndrome (Fig 33).

- Infectious viral disorder.
- Manifestations are present at birth.
- Anomalous stapes with a rudimentary thickened head, neck, crura and foot plate.
- Cartilaginous fixation of stapes footplate.
- Persistence of mesenchymal tissue in the middle ear.
- Depression of Reissner membrane.
- Cystic dilation of stria vascularis.
- Rolling of rectorial membrane into inner sulcus.
- Haircell degeneration spiral ganglion cell loss.
- Collapse of saccular membrane with adherence to the saccular macula.

Associated features : MR, microcephaly, microphthalmia, retinitis, congenital cataracts, thrombocytopenia, cardiovascular deformities and deformities of the lower extremities. Sensorineural and conductive losses.

Tay-Sachs disease and Sandhoff's disease (Fig 34).

Tay-Sachs disease and Sandhoff's disease are autosomal recessive GM₂ gangliosidoses with hexosaminidase defects, rapid psychomotor deterioration, hypotonia to generalized paralysis and eventual spasticity, deafness, blindness, seizures and cherry-red spot of the macula.

Main Signs

- Increasing muscular weakness after the third month of life, startle reflex in response to noise, progressive psychomotor decline, loss of sitting and standing reflexes.
- After 18 months of age in Tay-Sachs patients, or earlier in Sandhoff's patients, progressive deafness, blindness, seizures, pareses, spasticity.
- Doll-like face with pale translucent skin, long eyelashes, fine hair and unusual pink facial coloring.
- Cherry-red spot in the macular region in over 95% of patients.
- Mild hepatosplenomegaly in Sandhoff's disease patients.

Supplementary findings

Vomiting, starting in early infancy and increasing; recurrent pneumonias; progressive macrocephaly after the 16th month of life, as a result of cerebral gliosis (probably less as a result of ventricular enlargement). Lipidosis of the cortical, automatic and rectal mucosa neurons with ballooning of the cytoplasm and peripherally displaced nucleus. Central demyelination. cortical gliosis. No pathological changes of the visceral organs in Tay-Sachs disease, slight hepatosplenomegaly in Sandhoff's disease.

Manifestation : Biochemically, after birth. Clinically, earliest signs between the third and six months of life.

Aetiology

Tay-Sachs disease is an autosomal recessive disorder caused by hexosaminidase - A deficiency.

Kniest-type Osteodysplasia (Fig 35).

An inherited disorder of disproportionate short stature with kyphoscoliosis, flat faces often with hearing and visual impairment and characteristic radiograph findings.

Main Signs

- Disproportionate short stature with short trunk wide thorax, marked lumbar lordosis and thoracic kyphoscoliosis and short extremities, which appear swollen at the joints and too long relative to the trunk(1). Final height between about 105 and 155 cm.
- Flat facies, possibly with widely spaced eyes and proptosis caused by flat orbits, flat nasal bridge and (in approximately 50% of patients) cleft palate.
- Frequently limited movement at the joints(especially marked at the hips); long fingers.
- Frequent hearing impairment (conductive or sensorineural defect), frequent high grade myopia with retinal degeneration and danger of glaucoma, cataract and retinal detachment with loss of sight.

Supplementary findings

Often umbilical and inguinal hernias. Radiologically, striking anomalies in shape and size of the pelvic and femoral bones. Platyspondyly with ventrally tapering vertebral bodies, short clavicles, marked changes of the long bones, broadening of the metaphyses in the form of honey combed, porous translucencies and delayed ossification (especially of the femoral heads).

Manifestation : At birth (short, deformed extremities, disorders of joint mobility) and later, delayed motor development.

Aetiology

Autosomal dominant disorder with extremely variable expression.

Fragile X syndrome

Fragile X syndrome is an inherited abnormality of the X chromosome that causes disabilities ranging from varying degrees of learning problems to mental retardation. Features commonly associated with the syndrome include: severe language delay, behavior problems, autism or autistic-like behaviors (including poor eye contact and hand flapping), Macroorchidism, large prominent ears, hyperactivity, delayed motor development, and poor sensory skills. Hearing loss has seldom been associated with fragile X syndrome. Fragile X syndrome affects approximately 1 in 1000 persons.

Most children affected with fragile X syndrome will have some form of speech or language delay. Because they do not speak in short phrases until 2½ years of age, these children should have routine auditory evaluation. The speech of fragile X children has been described as compulsive, narrative and preverbal. Fragile X speech has been described as "cluttered" and "mumbled" with poor topic maintenance; frequent tangential comments may occur. Syntax is usually appropriate for mental age; a high receptive vocabulary score is usually seen, although auditory memory and processing skills are weak (Paul, 1984).

Ramsay Hunt syndrome (*Herpes Zoster Otiticus*)

- Viral neuritis of the facial nerve that may also involve the fifth and eighth cranial nerves.
- Severe otalgia and vesicular eruption in the ear canal.
- Otalgia may persist for many weeks.
- In obscure cases of otalgia, a history should be sought about a vesicular eruption in and about the ear.
- Chorda tympani nerve function and stapedius muscle function should be checked.
- Occasionally hearing impairment seen.

CHAPTER-3

SUMMARY AND CONCLUSION

In recent years, general awareness of the importance of genetic influences on human health and disease has dramatically increased. Terms such as gene, chromosome and recombinant DNA are being discussed more frequently in relationship to clinical and research problems. The applied health sciences, especially those disciplines involved with speech language and hearing are no exception.

An attempt is made to tabulate the hearing disorder with associated symptoms and signs based on the type and major system dysfunction. Each syndrome is highlighted and the clinical features are listed along with pictures for some.

This project is not intended as a comprehensive review of all genetic syndromes involving hearing disorder. It does highlight those syndromes that are seen in many interdisciplinary clinics.

Hearing loss due to genetic defects is frequently undiagnosed, and many of those patients with a family history of hearing loss are never examined for possible hereditary deafness.

The aim of this project was to focus more attention on hereditary deafness and to aid in the diagnosis of specific types of genetic hearing loss. Thus this review of syndromes associated with hearing loss is meant to appeal to individuals

with diverse backgrounds: otolaryngologists, Audiologists, pediatrician, speech pathologists and geneticists.

Syndrome presented in this project exhibits variety of clinical features those can signal the experienced clinicians to alter approaches to management. Because there are so many multiple anomaly syndrome, it should be realized that approach to patients diagnosis and treatment in nearly as individual as the syndrome. It is therefore vital that speech language pathologists and audiologists not only be sensitive to the possibility of a syndromic diagnosis, but also be as knowledgeable as possible of the phenotypes expressed in more common syndrome so that proper care can be applied.

It is hoped that this review of syndrome in audiology will serve as a reference guide for speech and hearing professionals, students, teachers and practitioners in applied health science who are concerned in the diagnosis and rehabilitation of hearing disabled children. A glossary of generic and medical terms is included in the project to minimize the need to refer to other texts or dictionary. Pictures of some syndromes are given in the appendix.

BIBLIOGRAPHY

Adkins,W.Y,Jr, & Gussen,R. (1974). Temporal bone findings in the third and pharyngeal pouch (Di George) syndrome.Arch otolaryngol 100, 206-208.

Albrecht,W. (1922). Cited in Declaw, F. & Heyning, P.V. (1996). Otosclerosis. In A. Martini., A. Read., & D. Stephens. (Eds.), Genetics & Hearing impairment, (pp. 221-230). Tyne: Whurr publishers.

Anderson, H. (1971). Cited in Northern, S. L., & Downs, M. P. (1991). Hearing in children (4th Edn.). (pp. 373-374). London : Williams & Wiltons .

Anneren, G., & Arvidson, B. (1984). Orofacial digital syndrome I and II Clinical Genetics, 26, 178-186.

Baird, P. A., & Sadovnick, A. D. (1989). Life tables for Down's syndrome. Human Genetics, 82, 291-292.

Baldwin, J. I. (1968). Dysostosis craniofacialis of Crouzon. Laryngoscope, 78, 1660=1675.

Batsakis, J. G., & Nishiyama, R. H. (1962). Deafness with sporadic goiter : Pendred's syndrome. Arch Otolaryngol, 76, 401-406.

Bergstrom, L., & Stewart, J. (1971). Cited in Northern, S. L., & Down's, M. P. (1991). Hearing in children (4th Edn.). (pp. 364). London: Williams & Wilkins.

Bergstrom, L., Neblett, L. M., & Hemenway, W. G. (1972). Otologic manifestations of acrocephalosyndactyly. Arch Otolaryngol, 96,117-123.

Bergstrom, L. (1973). Cited in Northern, S. L., & Down's, M. P. (1991). Hearing in children (4th Edn.). (pp. 360). London : Williams & Wilkins.

Bergstrom, L. (1984). Congenital hearing loss. In J. Northern, (ed.) Hearing disorders. Boston : Little Brown & Co.

Bitici, O. C. (1975). Familial hereditary progressive sensorineural hearing loss with Keratosis and plantaris. *Journal of laryngology & otology*, 89, 1143-1146.

Black, F. O. (1971). Cited in Northern, S. L., & Down's, M. P. (1991). Hearing in children (4th Edn.). (pp. 368). London: Williams & Wilkins.

Brenholz, P. (1989). Cited in Wiedemann, H. R., Kunze, J. & Grosse, F. R. (1997). *Clinical Syndromes* (3rd Edn) (pp. 476). London : Times Mirror International publishers limited.

Brewster, Th. G., Lachmann, R. S. (1985). Oto-palato digital syndrome type II. *American Journal of Medical Genetics*. 20,249-254.

Cawthorne, T. (1955). Cited in Declau, F., & Heyning, P. V. (1996). otosclerosis. In A. Martini., A. Read & D. Stephens. (Eds), *Genetics and Hearing impairment* (pp. 221-230). Tyne : Whurr publishers.

Chrysostomidou, D. M. (1971). Cited in Northern, S. L., Down's, M. P. (1991). Hearing in children (4th Edn.). (pp. 373). London : Williams & Wilkins.

Cohen, M. M., Jr. (1977). Craniofacial anomalies and syndromes. In CD. Blue stone., S. E. Stool & S. K. Arjona. (Eds), *Pediatric otolaryngology*. (pp 32-33). London: W.B. Saunders Company.

Cole, D. E. & Cohen, M. M. (1988). A new look at craniometaphyseal dysplasia. *Journal of Paediatrics*, 112, 577-579.

Connode, E. J., Dawson, M., & Lowry, R. B. (1986). Cited in Wiedemann, H. R., Kunze, J., & Grosse, F. R. (1997). *Clinical Syndromes* (3rd Edn) (pp. 264) London : Times mirror International publishers limited.

Cronk, C, Crocker, A. C, & Pueschel, S. M. (1988). Growth charts for the children with Down Syndrome. 1 month to 18 years of age. *Paediatrics*, 81, 102-110.

Dawn de-lozier- Blanchet, C. (1989). Antley-Bixler syndrome from a prognostic perspective. *American Journal of Medical Genetics*, 32, 262-263.

Digweed, M., & Zakerzewski, S. (1988). Fanconi's anemia : *Human genetics*, 78, 51-54.

Dodge, H. W. Jr, Wood, M. W., & Kennedy, R. I. J. (1959). Craniofacial dysostosis: Crouzon's disease. *Paediatrics*, 23, 98.

Fienman, N. L. & Yakovac, W. C. (1970). Neurofibromatosis in childhood. *Journal of Paediatrics*, 76, 339-346.

Fitch, N., & Jequier, S. (1983). Cited in Wiedemann, H. R., Kunze, J. & Grosse, F. R. (1997). *clinical syndromes* (3rd Edn). (pp. 28). London : Times Mirror International publishers limited.

Foils, M. (1969). Ear malformations in Cleido cranial dysostosis. *Acta. OtolaryngoL* 67,483-489.

Fosmoe, R. J. (1968). Cited in Northern, S. L. & Downs, M. P. (1991). .Hearing in children (4th Edn.). (pp. 374). London : Williams & Wilkins.

Fraser, G. R. (1965). Cited in Northern, S. L. & Downs, M. P. (1991). Hearing in children (4th Edn.). (pp. 370). London : Williams & Wilkins.

Fraser, G. R. (1962). Cited in Northern, S. L. & Downs, M. P. (1991). Hearing in children (4th Edn.). (pp. 361). London : Williams & Wilkins.

Fraser, W. I. & Campbell, B. M. (1978). Cited in Northern, S. L. & Downs, M. P. (1991). Hearing in children (4th Edn.). (pp. 34). London: Williams & Wilkins.

Friedman, J. M., & Hanson, J. W. (1977). Saethre-Chotzen syndrome. *Journal of Paediatrics*, 91, 929-933.

Friedmann, I., Fraser, G. R., & Froggatt, P. (1966). Pathology of the ear in cardio-auditory syndrome of Jervell & Lange-Nielsen. *Journal of Laryngology & Otology*, 80,451-470.

Fryer, D. G., & Winckleman, A. C, Ways, P. O. (1971). Cited in Northern, S. L. & Downs, M. P. (1991). Hearing in children (4th Edn.). (pp. 371). London : Williams & Wilkins.

Gerristen, E. J. A., & Vossen, J. M. (1994). Autosomal recessive osteoporosis variability of findings at diagnosis & during the natural course *paediatrics*, 93, 247-253.

Gilbert, P. (1996). *The A-Z reference book of syndromes and inherited disorders* (Edn 2). (pp. 59-62). California: Singular publishing group, Inc.

Goldstein, J. L. & Fialkow, P. J. (1973). Retinal degeneration, Diabetes mellitus, obesity and sensorineural hearing loss.(Alstrom syndrome). In C. D. Bluestone, S. E. Stool, & S. K. Arjona. (Eds), Paediatric Otolaryngology. (pp.32-33). London : W. B. Saunders company.

Goodman, R. & Gorlin, R. (1977). Cited in Jung, J. H. (1989). Genetic Syndromes in communication disorders, (pp.87-94). Texas : Proed.

Goodman, R. M, Lackareff, S., & Gwinup, G. (1969). Hereditary congenital deafness with onchyodystrophy. Arch Otolaryngol, 90,474-477.

Gorlin, R. J., Pindborg, J. J., & Cohen, M. M. (1976). Cited in Bergstrom. Diseases of labyrinthine capsule. In C. D. Bluestone, S. E. Stool & S. K. Arjona, (Eds), Paediatric otolaryngology (pp. 611). London : W. B. Saunders company.

Guild, S. R. (1944). Cited in Declau, F. & Heyning, P. V. (1996). Otosclerosis. In A. Martini., A. Read. & D. Stephens. (Eds), Genetics and Hearing impairment. (pp.221-230). Tyne : Whurr publishers.

Hallgren, V. (1959). Cited in Northern, S. L. & Downs, M. P. (1991). .Hearing in children (4th Edn.). (pp. 364). London : Williams & Wilkins.

Harboyan, G., Mamo, J., Der Kaloustian, V., & Karam, F. (1971). Congenital corneal dystrophy. Progressive sensorineural deafness in family. Arch Ophthalmol., 85, 27-32.

Herrmann, C, Jr, Aguilar, M. J., & Stacks, O. W. (1964). Cited in Northern, S. L. & Downs, M. P. (1991). Hearing in children (4th Edn.). (pp. 364). London : Williams & Wilkins.

Hicks, W. M., & Hicks, D. E. (1981). Cited in Northern, S. L. & Downs, M. P. (1991). *Hearing in children* (4th Edn.). (pp. 374). London : Williams & Wilkins.

Holmes, L. b. (1971). Neme's disease ; an X-linked syndrome of retinal malformation, mental retardation and deafness. *Journal of Paediatrics*, 70, 84-92.

Hoit, R. G. (1978). ENT manifestation of Von Reckling Hausen's disease. *Laryngoscope*, 88,1617-1632.

Hueb, M. M. (1991). Cited in Declau, F. & Heyning, P. V. (1996). otosclerosis. In A. Martini., A. Read. & D. Stephens. (Eds), *Genetics and Hearing impairment* (pp. 221-230). Tyne : Whurr publishers.

Hughes, G. B., Sismanis, A., & Jackson, C. G. (1982). Management of bilateral acoustic tumors. *Laryngoscope*, 92, 1315-1359.

Ide, C. H., & WollSchlaeger, P. P. (1969). Cited in Northern, S. L. & Downs, M. P. (1991). *Hearing in children* (4th Edn.). (pp. 361). London : Williams & Wilkins.

Ilium, P., Kaier, H. W., & Hvidberg-Hansen, J. (1972). Fifteen cases of Pendred's syndrome. *Arch otolaryngol* 96, 297-304.

Jacobson, J. T. (1997). A review of genetic hearing loss. *The Hearing journal*, 50:6, 10-21.

Jervell, A., & Lanange-Nielsen, F. (1957). Cited in Northern, S. L. & Downs, M. P. (1991). *Hearing in children* (4th Edn.). (pp. 366). London : Williams & Wilkins.

Johnson, C. G., & Arenberg, K. (1981). Cited in Northern, S. L. & Downs, M. P. (1991). *Hearing in children* (4th Edn.). (pp. 359). London : Williams & Wilkins.

Johnston, C. C, Lowry, N., & Lord, T. (1968). Cited in Northern, S. L. & Downs, M. P. (1991). *Hearing in children* (4th Edn.). (pp. 358). London : Williams & Wilkins.

Jones, M. D., & Mulcahy, N. D. (1968). Osteopathia striata, osteopetrosis and impaired hearing. *Arch otolaryngol*, 87, 20-22.

Kelemen, G. (1965). Marian's syndrome and hearing organ *Acta otolaryngol*, 59, 23-32.

Keleman, G. (1968). Cited in Northern, S. L & Down, M. P. (1991). *Hearing in children* (4th Edn.). (pp. 374). London : Williams & Wilkins.

Kloepfer, H. W. (1966). The hereditary syndrome of deafness in retinitis pigmentosa. *Laryngoscope*, 76, 850-862.

Konigsmark, B. W. & Gorlin, R. J. (1976). *Genetic & metabolic deafness*. Philadelphia :W. B. Saunders company.

Kos, A. O. (1966). Cited in Northern, S. L. & Downs, M. P. (1991). *Hearing in children* (4th Edn.). (pp. 373). London : Williams & Wilkins.

Kumar, D. (1990). Cited in Wiedemann, H. R., Kunze, J. & Grosse, F. .R. (1997) *clinical syndromes* (3rd Edn) (pp. 570). London : Times Mirror International publishers limited.

Langer, L. O. (1965). Cited in Northern, S. L. & Downs, M. P. (1991). *Hearing in children* (4th Edn.). (pp. 360). London : Williams & Wilkins.

Larsson, A. (1960). Cited in Declau, F. & Heyning, P. V. (1996). otosclerosis. In A. Martini., A. Read & D. Stephens. (Eds), Genetics & Hearing impairment (pp. 221-230). Tyne : Whurr publishers.

Lindsay, J. R., Black, F. O., & Donnelly, W. N. (1975). Acrocephalo syndactyly. (Apert syndrome) Temporal bone findings. *Annal otol Rhinol Laryngol*, 84, 174-178.

Lipson, A. H., Cowell, C, & Gorlin, R. J. (1989). Cited in Wiedemann, H. R., Kunze, J. & Grosse, F. R. (1997). *Clinical Syndromes* (3rd Edn) (pp. 660). London: Times Mirror International publishers limited.

Mandel A. J., Smith, C. K. (1960). Cited in Northern, S. L., & Downs, M. P. (1991). *Hearing in children* (4th Edn.). (pp. 372). London : Williams & Wilkins.

Marden, P. M. (1964). Congenital anomalies in the newborn infant, including minor variation. *Journal of Pediatrics*, 64, 358.

Martin, F. N. (1975). *Introduction to Audology*. London: Printce HallInc.

May, D. L. & White, H. H. (1968). Cited in Northern, S. L, & Downs, M. P. (1991). *Hearing in children* (4th Edn.). (pp. 369). London : Williams & Wilkins.

Mc Donough, E. R. (1970). Fanconi anemia syndrome. *Arch otolaryngol*, 92, 284=285.

McLay, K, & Maran, A. G. D. (1969). Deafness and the Klippel-Feil syndrome. *Journal of Larngology and Otology*, 83, 175-184.

McLeod, A. C. (1971). Clinical variation in Usher's syndrome. *Arch Otolaryngol*, 94, 321-334.

Mendes, H. M., & Opitz, J. (1985). Noonan syndrome : a review. *American Journal of Medical Genetics*, 21, 493-506.

Mengel M. C. (1969). Conductive hearing loss and malformed low set ears as a possible recessive syndrome. *Journal of Medical Genetics*, 6, 14-21.

Miyamoto, R. T., Yune, H. Y., & Rosevear, W. H. (1983). Cited in Northern, S. L., & Downs, M. P. (1991). *Hearing in children* (4th Edn.). (pp. 366). London : Williams & Wilkins.

Moore, M. V. (1970). Speech hearing and language in De Lange syndrome. *Journal of Speech and Hearing Disorder*, 35, 66-69.

Morgenstein, K. M., & Manance, E. D. (1969). Temporal bone histopathology in sickle cell disease. *Laryngoscope*, 79, 2172-2180.

Morrison, A. W. (1970). The inheritance of otosclerosis. *Journal of Laryngology and Otology*, 84, 921-932.

Myers, F. N. & Stool, S. (1969). The temporal bone in Osteopetrosis. *Arch otolaryngol* 89, 44-53.

Nance, W. E. (1973). Cited in Northern, S. L. & Downs, M. P. (1991). *Hearing in children* (4th Edn.). (pp. 371). London : Williams & Wilkins.

Nasiff, R., & Harboyan, G. (1970). Madelung's deformity with conductive hearing loss. *Arch otolaryngol*, 91, 175-178.

Nelson, M. & Scott (1969). Cited in Northern, S. L. & Downs, M. P. (1991). *Hearing in children* (4th Edn.). (pp. 363). London : Williams & Wilkins.

Nicbuhr, E. (1978). The cri du chat syndrome. *Human genetics*, 44, 227. .

Norby, S. (1994). Cited in Wiedemann, H. R., Kunze, J. & Grosse, F. R (1997) *clinical syndromes* (3rd Edn) (pp. 584). London : Times Mirror International publishers limited.

O'Callaghan, M., & Young, I. D. (1990). Cited in Wiedemann, H. R, Kunze, J. & Grosse, F. R. (1997) *clinical syndromes* (3rd Edn) (pp. 644). London : Times Mirror International publishers limited.

Oley, C. A., Baraitser, M., & Grant, D. B. (1988). A reappraisal of CHARGE association. *Journal of Medical Genetics*, 25, 147-156.

Opitz, J. M. (1993). Acrofacial dysostosis : review. *American Journal of Medical Genetics*, 47, 660-678.

Pashayan, H. M. (1974). Cited in Northern, S. L. & Downs, M. P. (1991). *Hearing in children* (4th EDN). (pp. 362). London : Williams & Willrins.

Paterson, C. R., & Mc Allion, S. (1983). Cited in Wiedemann, H. R, Kunze, J. & Grosse, F. R. (1997) *Clinical syndromes* (3rd Edn). (pp. 422). London : Times Mirror International publishers limited.

Patton, M. A., Giannilli F., & Francis, A. J. (1989). Early onset Cockayne's Syndrome. *Journal of Medical Genetics*, 26, 154.

Paul, R. (1984). Fragile X-Syndrome : It's relation to speech and language disorder. *Journal of Speech and Hearing Disorders*, 49, 326-336.

Pfaffenbach, D. D. (1972). Congenital anomalies in Duane's Retraction Syndrome. *Arch ophthalmol*, 88, 635-639.

Preus, M., Fraser, F. C. (1973). The Lobster-Claw Defects with ectodermal defects, cleft lip- palate, tear duct anomaly and renal anomalies. *Clinical Genetics*, 4, 369-375.

Reardon, W., & Hall, C. M. (1994). Cited in Wiedemann, R. H., Kunze, J. & Grosse, F. R. (1997) *Clinical Syndromes* (3rd Edn). (pp. 280). London : Times Mirror International Publishers limited.

Reiser, C. A., & Pauli, R. M. (1984). Cited in Wiedemann, R. H., Kunze, J. & Grosse, F. R. (1997) *Clinical Syndromes* (3rd Edn). (pp. 268). London : Times Mirror International Publishers limited.

Richard, B. W, & Rundle, A. T. (1959). Cited in Northern, S. L. & Downs, M. P. (1991). *Hearing in children* (4th Edn.). (pp. 371). London : Williams & WilMns.

Rimoin, D. L. & Edgerton, M. T. (1967). Genetic & Clinical Heterogenity in the Oval-Facial Digital Syndrome. *Journal of Paediatrics*, 71, 94-102.

Rintelmann, W. F. (1976). Cited in Northern, S. L. & Downs, M. P. (1991). *Hearing in children* (4th Edn.). (pp. 359). London : Williams & Wilkins.

Robinson, G. C. (1973). Ectodactyly, Ectodermal Dysplasia and Cleft Lip-palate. Its association with conductive hearing loss. *Journal of Paediatrics*, 82, 107-109.

Rodini, E. S. (1992). Cited in Wiedemann, H. F., Kunze, J. & Grosse, F. R. (1997). *Clinical Syndromes* (3rd Edn). (pp. 448). London : Times Mirror International Publishers limited.

Rollnick, B. R., & Kaye, C. I. (1983). Hemifacial Microsomia and Variants. *American Journal of Medical Genetics*, 15, 233-253.

Rosenberg, A. L., Bergstrom, L., & Troost, B. T. (1970). Cited in Northern, S. L., & Down's, M. P. (1991). *Hearing in children* (4th Edn.). (pp. 365). London : Williams & Wilkins.

Ruppert, E. S. (1970). Hereditary hearing loss with saddle nose and myopia. *Arch otolaryngoL* 92, 95-98.

Saldino, R. M., Sternbach, H. L. & Epstein, C. J. (1972). Cited in Konigsmark, B. W., & Gorlin, R. J. (1976). *Genetic & metabolic deafness*, (pp. 222). London : W. B. Saunders company.

Schaefer, I. A. (1962). Cited in Northern, S. L. & Downs, M. P. (1991).. *Hearing in children* (4th Edn.). (pp. 365). London : Williams & Wilkins.

Schuknecht, H. F. (1974). Cochlear otosclerosis : Fact or Fantasy? *Laryngoscope*, 84, 766-82.

Setzer, E. S., Ruiz-Castaneda, N. (1981). Etiologic heterogeneity in the oculo auriculo vertebral syndrome. *Journal of Paediatrics*, 98, 88.

Shanon, E. (1981). Cited in Northern, S. L. & Downs, M. P. (1991). *Hearing in children* (4th Edn.). (pp.363). London : Williams & Wilkins.

Shprintzen, R. J. (1997). *Genetics, syndromes and communication disorders*. London: Singular Publishing group Inc.

Silva, E. O. (1982). Autosomal recessive. Klippel-Feil syndrome. *Journal of Medical Genetics*, 19, 130-134.

Silver, H. K. (1964). Cited in Northern, S. L. & Downs, M. P. (1991). *Hearing in children* (4th Edn.). (pp. 361). London : Williams & Wilkins.

Silverman, F. N. (1980). Cerebro-costo-mandibular syndrome. *Journal of Paediatrics*. 97, 406-416.

Singh, S. P. & Bresman, M. J. (1973). Cited in Northern, S. L. & Downs, M. P. (1991). *Hearing in children* (4th Edn.). (pp. 371). London : Williams & Wilkins.

Smith, D. W. (1962). The number 18 trisomy syndrome. *Journal of Paediatrics* 60,513.

Stanley, R. J., Puritz, E. M. & Birggaman, R. E. (1975). Cited in Northern, S. L., & Downs, M. P. (1991). *Hearing in children* (4th Edn.). (pp. 372). London : Williams & Wilkins.

Stark, E. W. & Borton, T. E. (1973). Klippel-Feil syndrome and associated hearing loss. *Arch otolaryngol*, 97, 415-419.

Stevens, P. R. & Macfayden, W. A. L (1972). Cited in Northern, S. L. & Downs, M. P. (1991). *Hearing in children* (4th Edn.). (pp. 369). London : Williams & Wilkins.

Sylvester, P. E. (1958). Cited in Northern, S. L. & Downs, M. P. (1991). *Hearing in children* (4th Edn.). (pp. 363). London : Williams & Wilkins.

Temple, I .K. (1989). Cited in Wiedemann, H. R., Kunze, J. & Grosse, F. R. (1997) *Clinical Syndromes* (3rd Edn). (pp. 370). London : Times Mirror International Publishers limited.

Thompson, R. C. Jr, Gaull G. E., & Horwitsz, S. J. (1969). Cited in Northern, S. L, & Downs, M. P. (1991). *Hearing in children* (4th Edn.). (pp. 370). London : Williams & Wilkins.

Von Reckling Hausen, F. (1882). Cited in Jung, J. H. (1989). *Genetic syndromes in communication disorders*. Texas : Proed.

Voron. D., Hatfield, H., & Karkhoff, R. (1976). Cited in Wiedemann, H. R, Kunze. J. & Grosse, F. R. (1997) *Clinical Syndromes* (3rd Edn). (pp. 364). London : Times Mirror International Publishers limited.

Vulliamy, D. G & Normandale, P. A. (1966). Cited in Northern, S. L., & Downs, M. P. (1991). *Hearing in children* (4th Edn.). (pp. 361). London : Williams & Wilkins.

WahL R. A., & Dick, M. (1980). Cited in Northern, S. L., & Downs, M. P. (1991). *Hearing in children* (4th Edn.). (pp. 366). London : Williams & Wilkins.

Walker, W. G. (1971). Cited in Northern, S. L., & Downs, M. P. (1991). *Hearing in children* (4th Edn.). (pp. 363). London : Williams & Wilkins.

Wang. & Lin (1981). Further evidence for genetic heterogeneity of whistling f ace or Freeman- Sheldon syndrome. *American Journal of Medical Genetics*, 28, 471-475.

Weinstein, R L., Kilman, B., & Scully, R E. (1969). Cited in Northern, S. L., & Downs, M. P. (1991). Hearing in children (4th Edn.). (pp. 366). London : Williams &Wilkins.

Wilson W. G., & Kelly. (1981). Early recognition of Coffin - Lowry Syndrome. American Journal of Medical Genetics. 8 215-220.

Williams, A., Williams, M, & Walker. C. (1981). Cited in Northern, S. L., & Downs, M. P. (1991). Hearing in children (4th Edn.). (pp. 370-371). London : Williams & Willans.

Windle-Taylor. P, Emery, P. J., & Phelps, P. D. (1981). Ear deformities associated with Klippel-Feil syndrome. Annal otol, 90, 210-216.

Winter, J. S. D. (1968). A familial syndrome of renal, genital & middle ear anomalies. Journal of Paediatrics, 72, 88-93.

Woolf; C. M., DoloWitz, D. A., & Aldous, H. E. (1965). Congenital deafness associated with Piebaldness. Arch otolaryngol, 82, 244-250.

Yost, W. A. (1994). Fundamentals of hearing. San Diego: Academic Press, Inc.

Young, J.D., & Harpes,P.S.(1982). Cited in Wiedemann, H. R., Kunze, J. & Grosse, F. R. (1997) Clinical Syndromes (3rd Edn). (pp. 132). London : Times Mirror International Publishers limited.

Zellweger, H. (1974). The Marshall syndrome : Report of a new family. Journal of Paediatrics, 84,868-871.

APPENDIX

Pictures of Syndromes associated with hearing loss

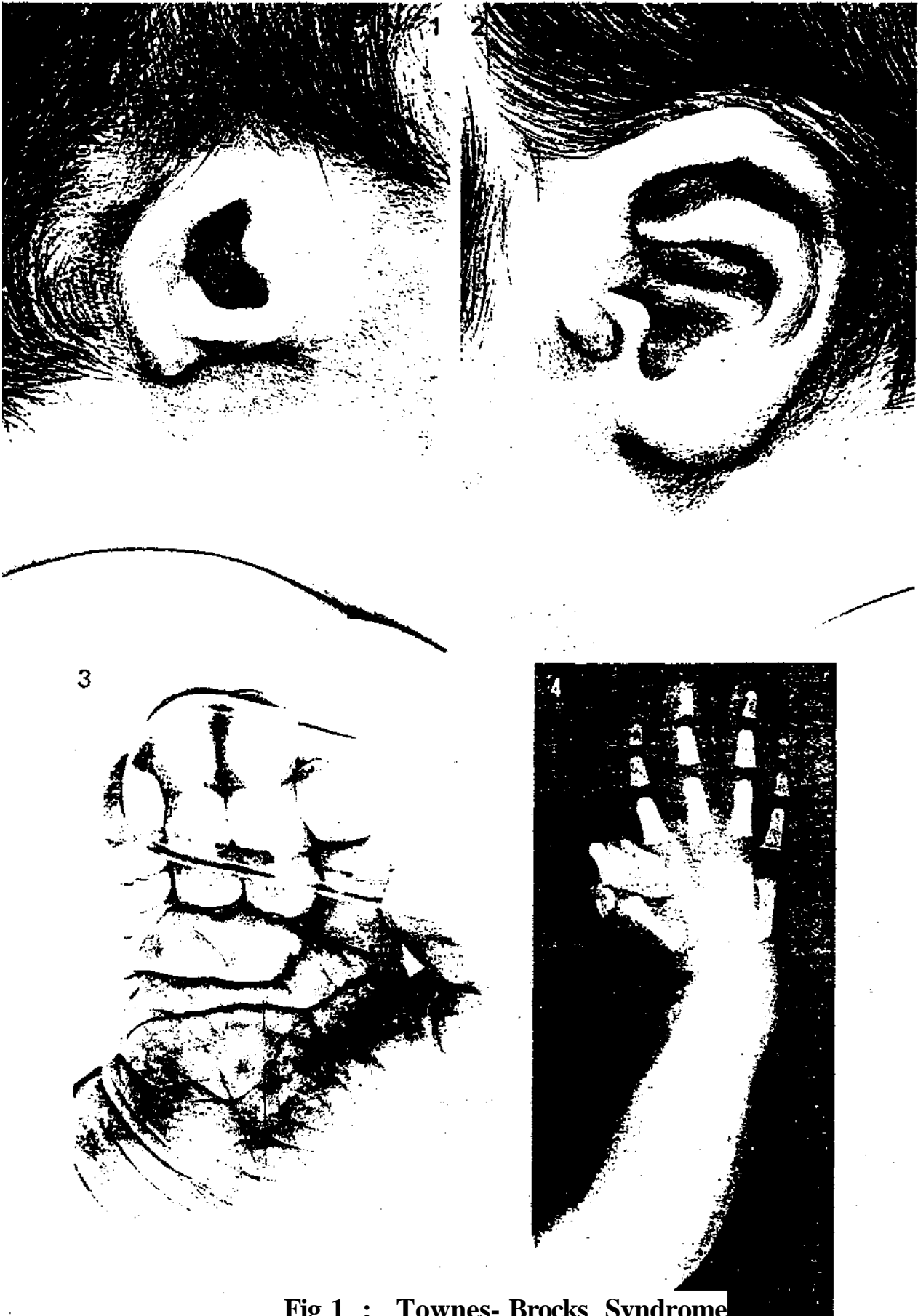


Fig 1 : Townes- Brocks Syndrome

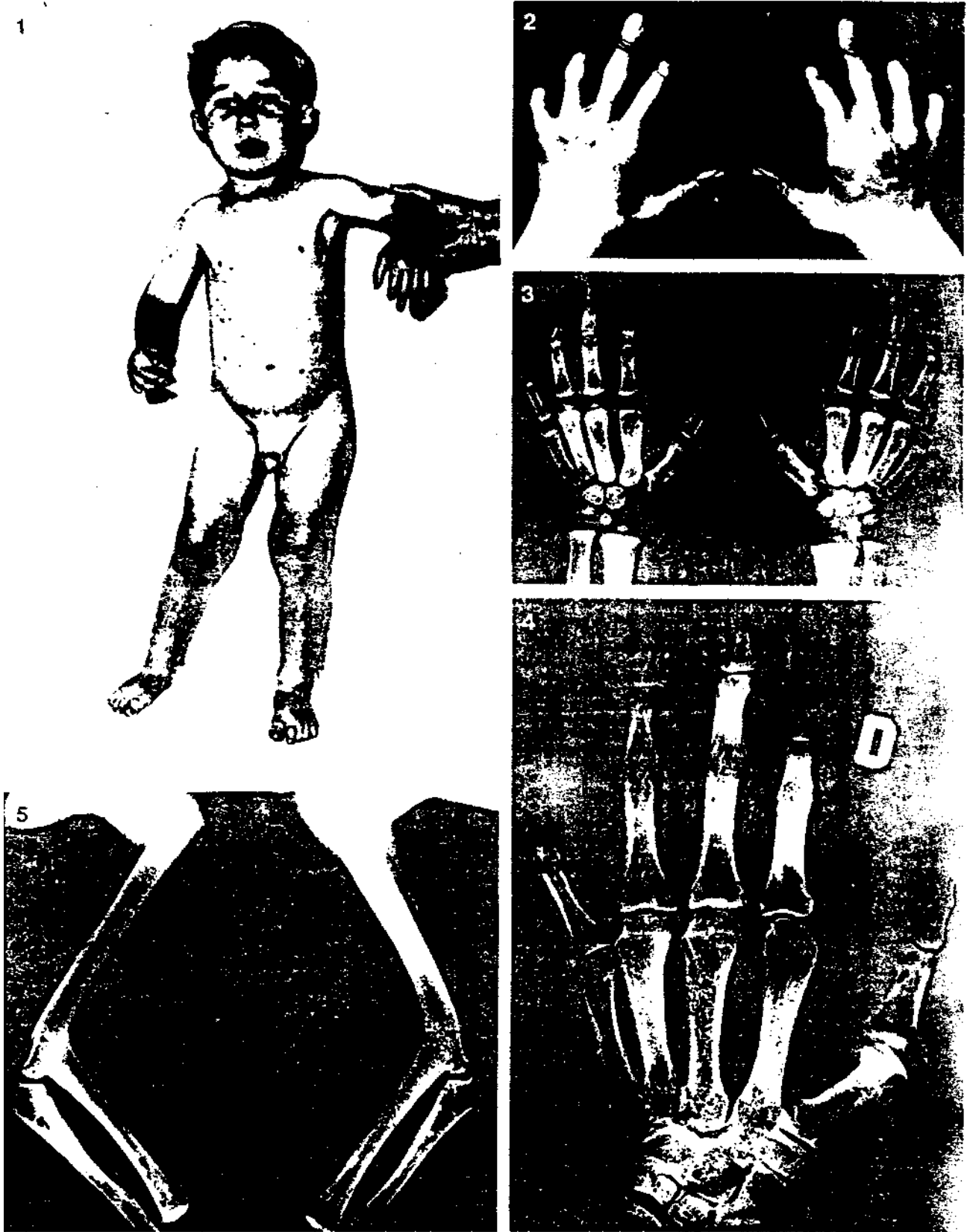


Fig 2 : Symphalangism Syndrome

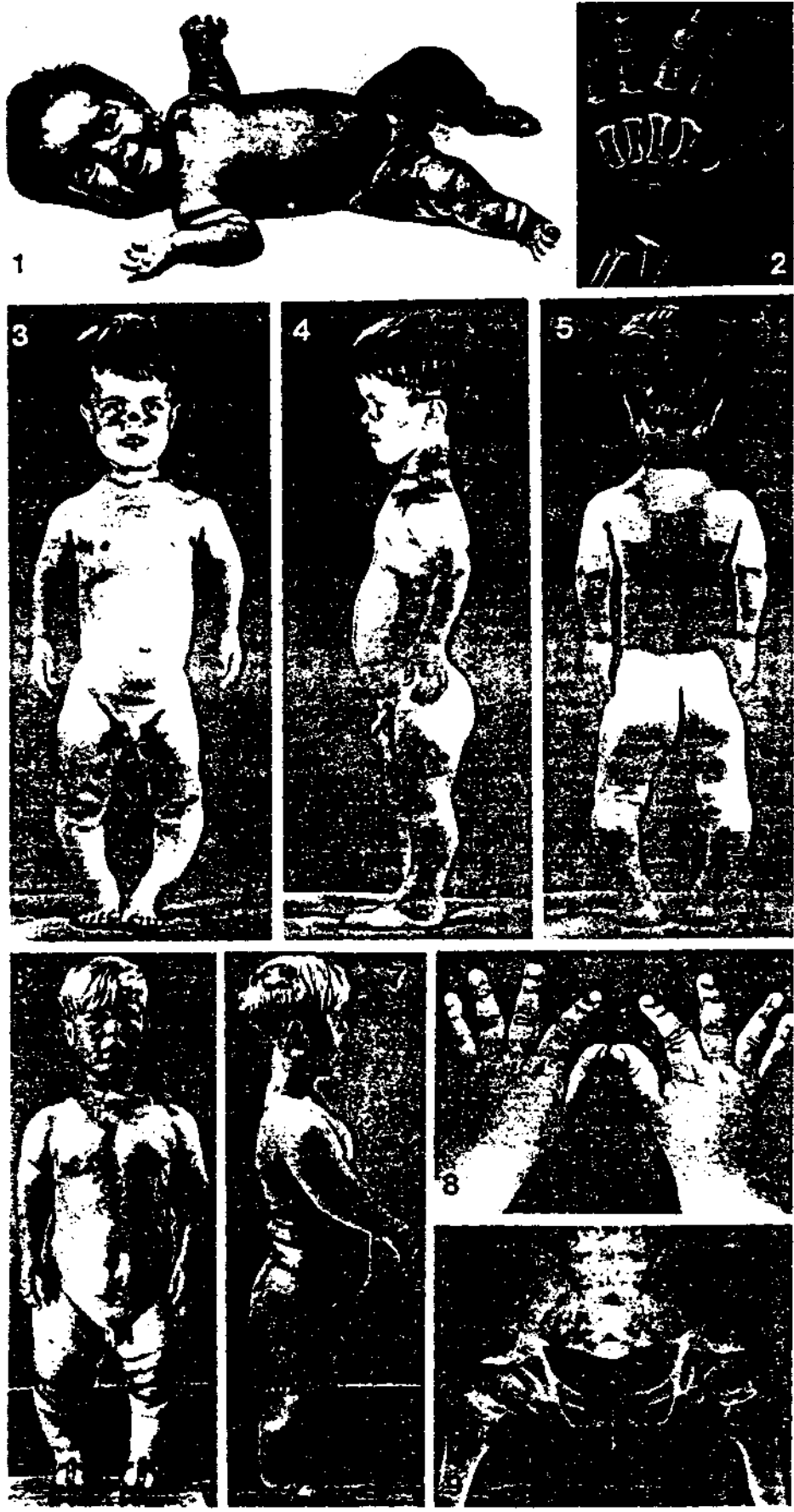


Fig 3 : Achondroplasia Syndrome

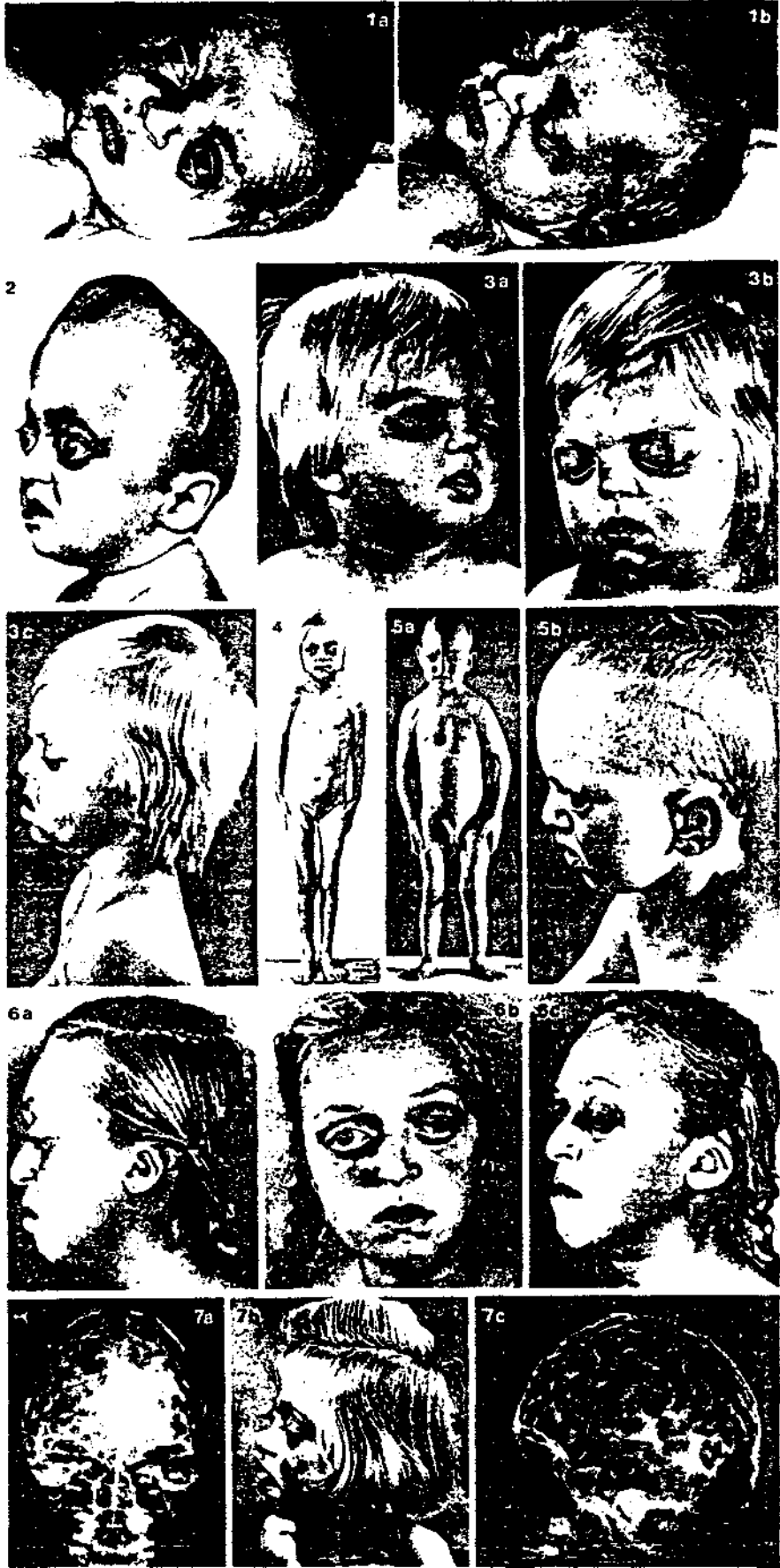

Fig 4 : Crouzon Syndrome

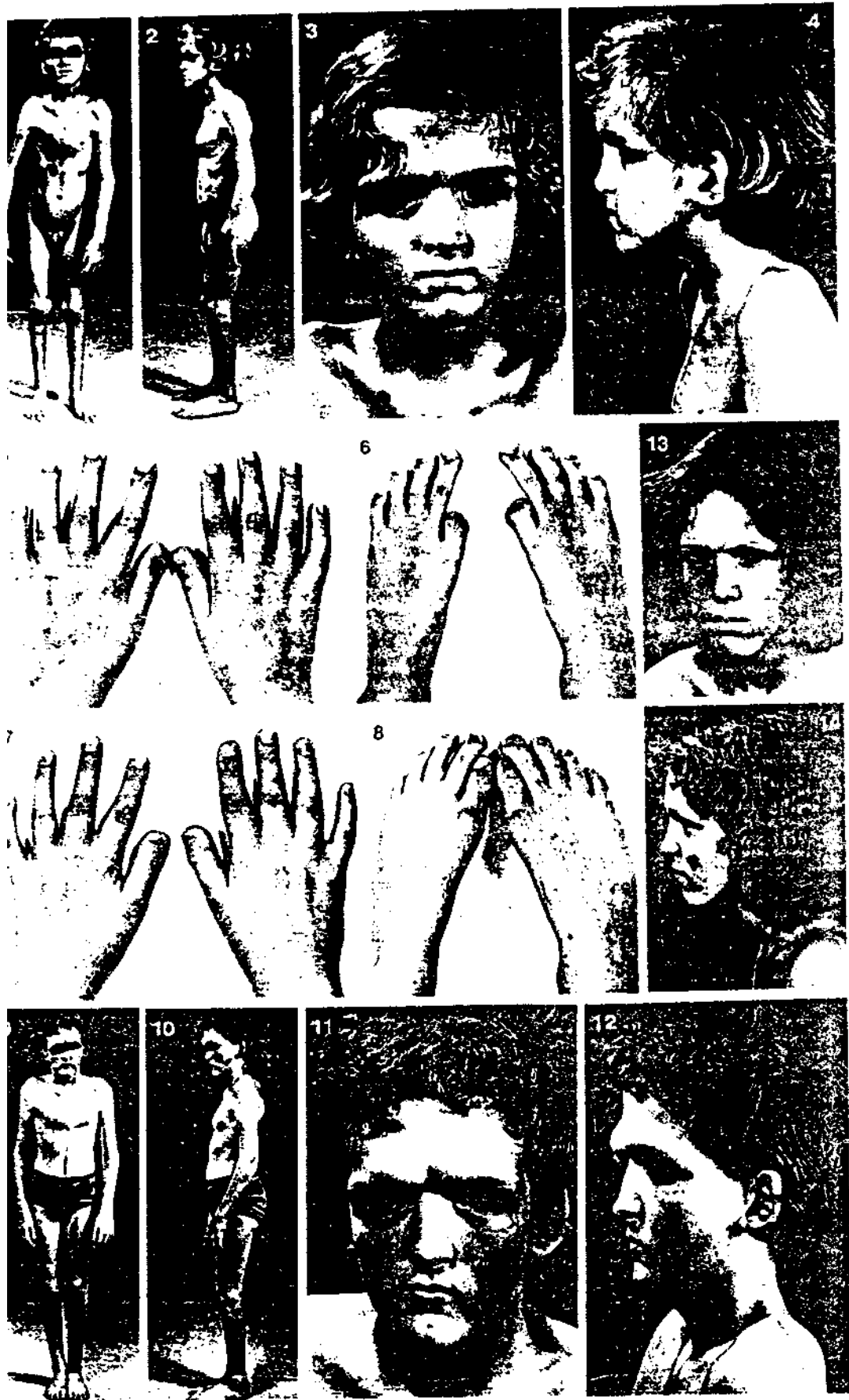

Fig 5 : Otopalato Digital Syndrome

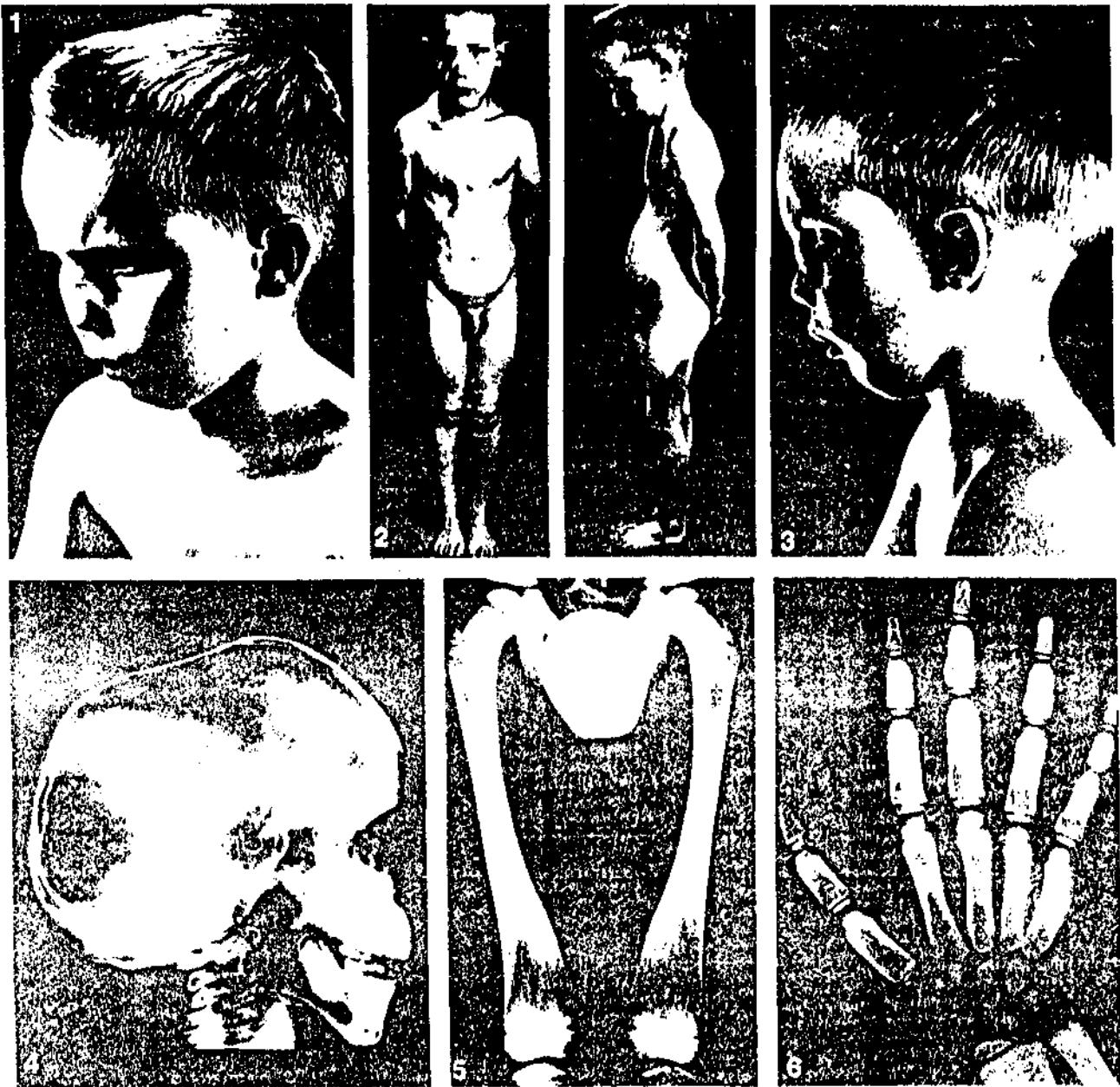


Fig 6 : Craniometaphyseal Syndrome



2



4



Fig 7 : Stickler Syndrome

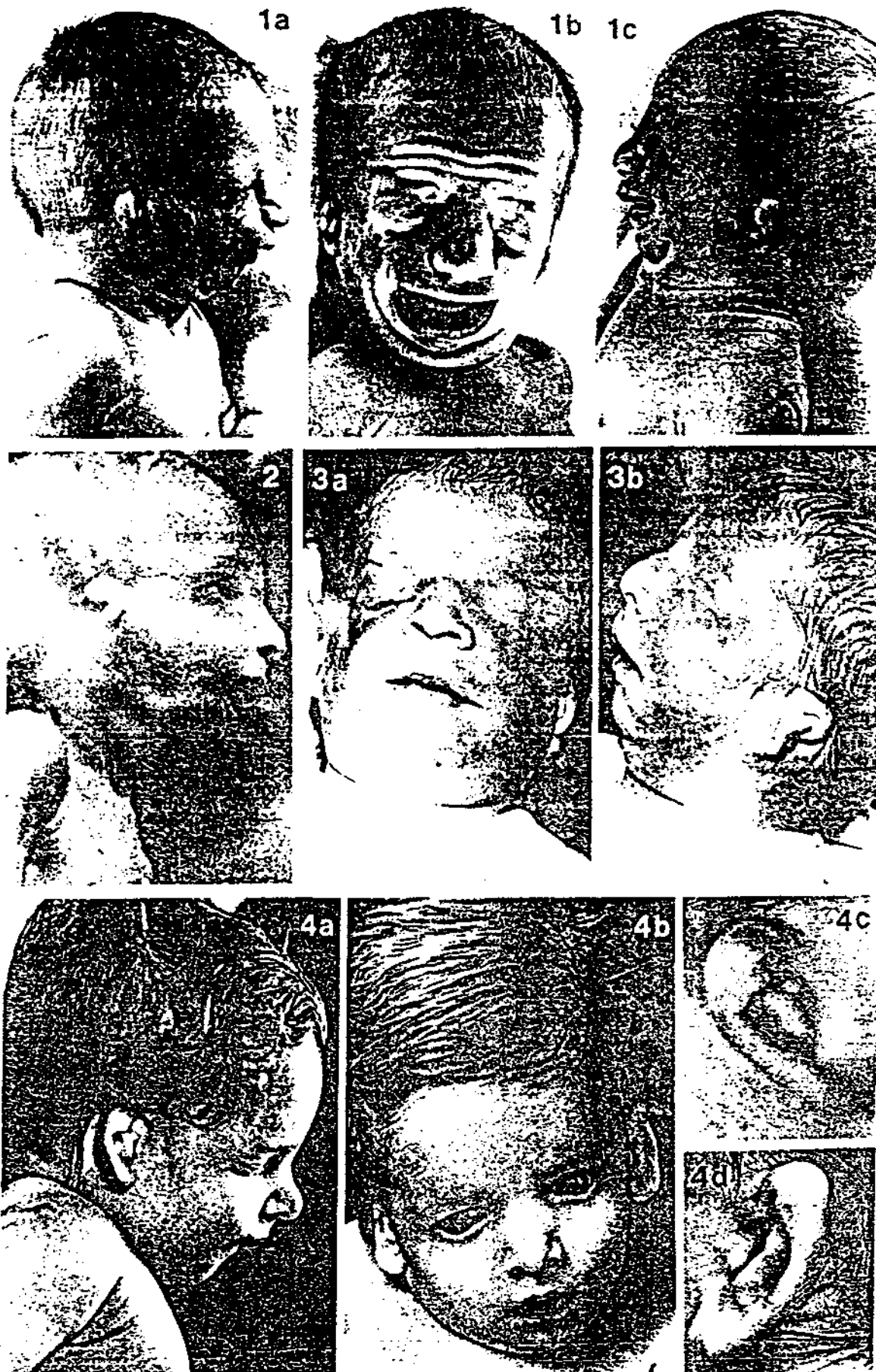

Fig 8 : Treacher Collins Syndrome

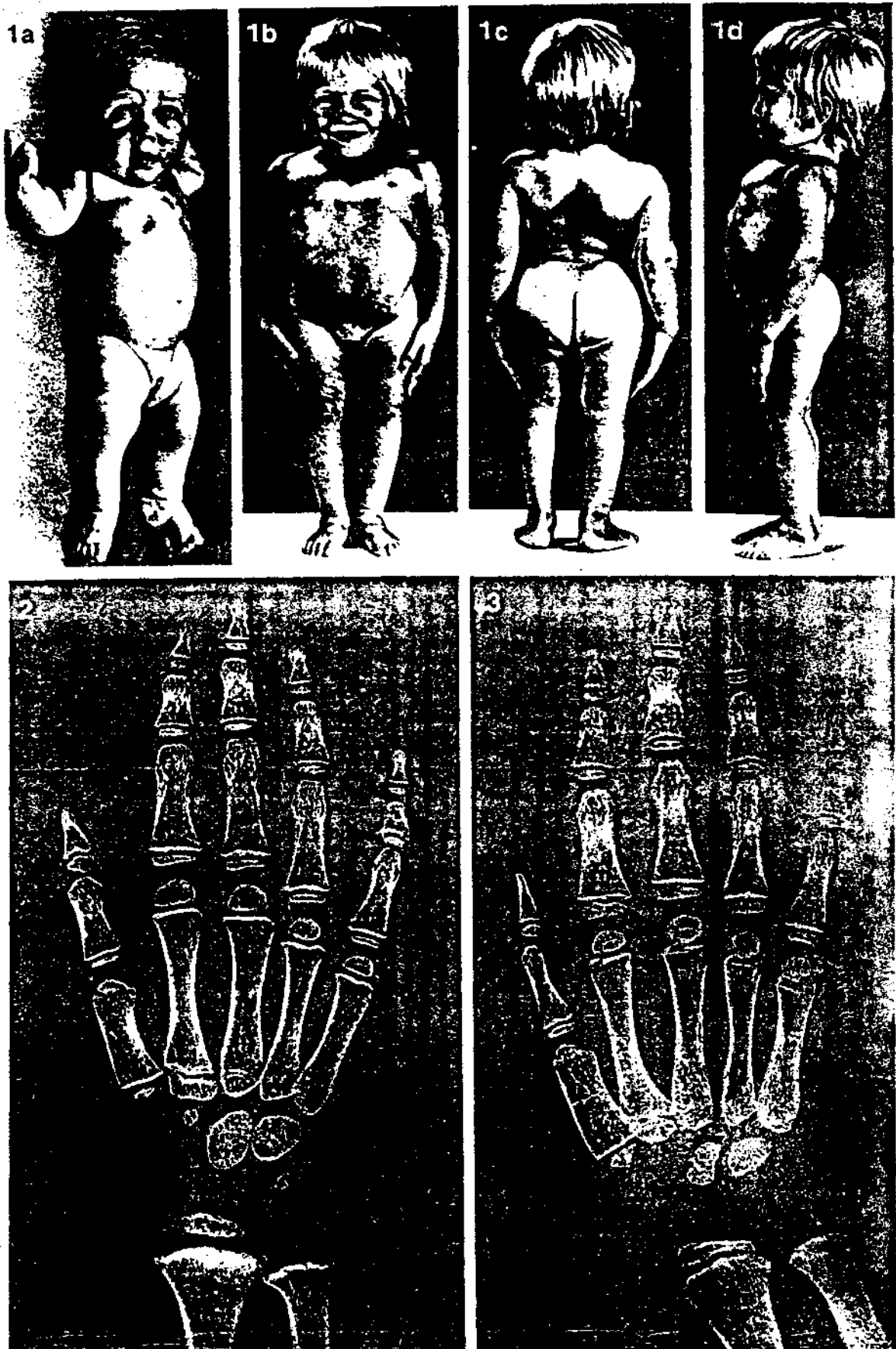


Fig 9 : Spondylo Epiphyseal Dysplasia Syndrome

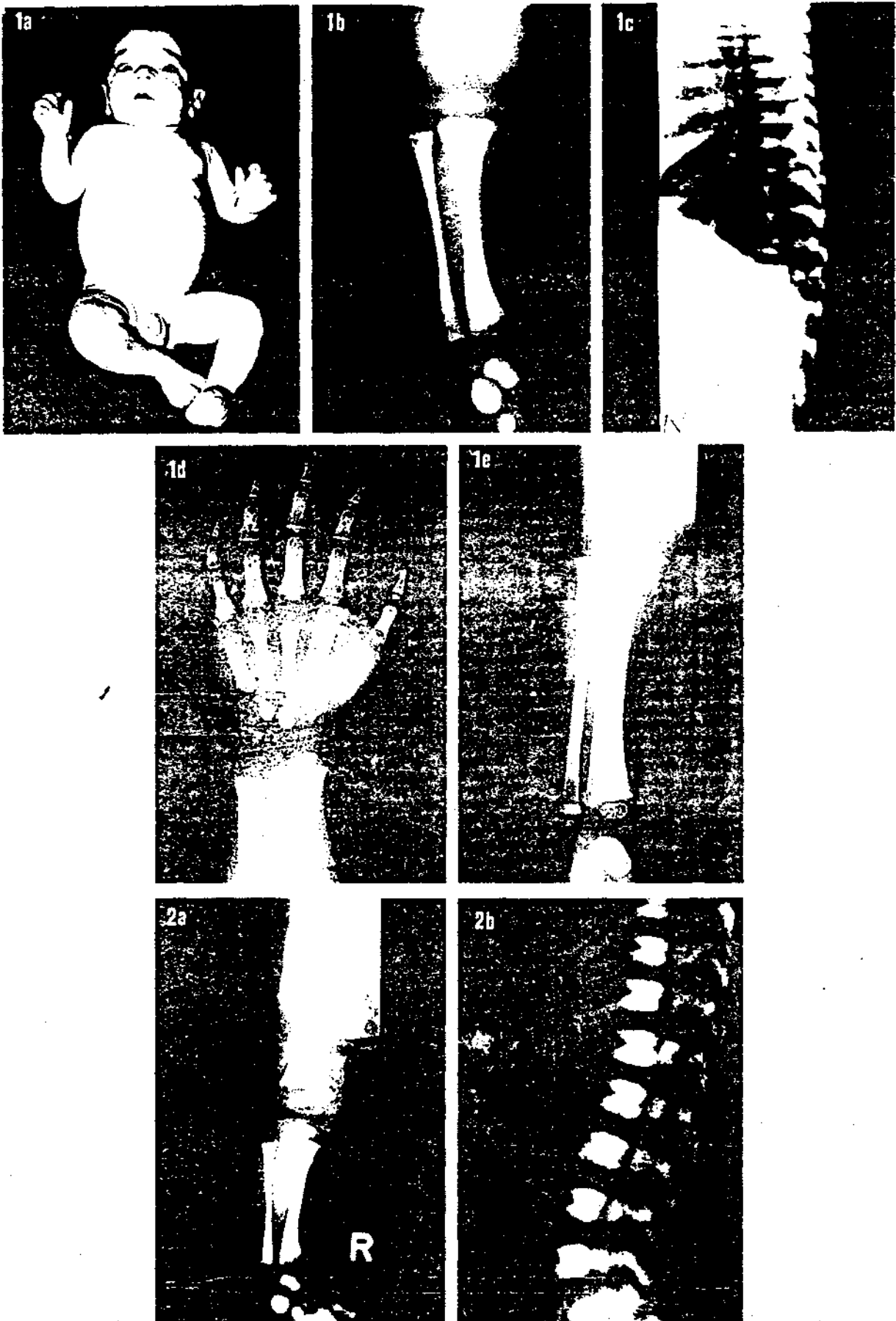


Fig 10 : Osteopetrosis Syndrome

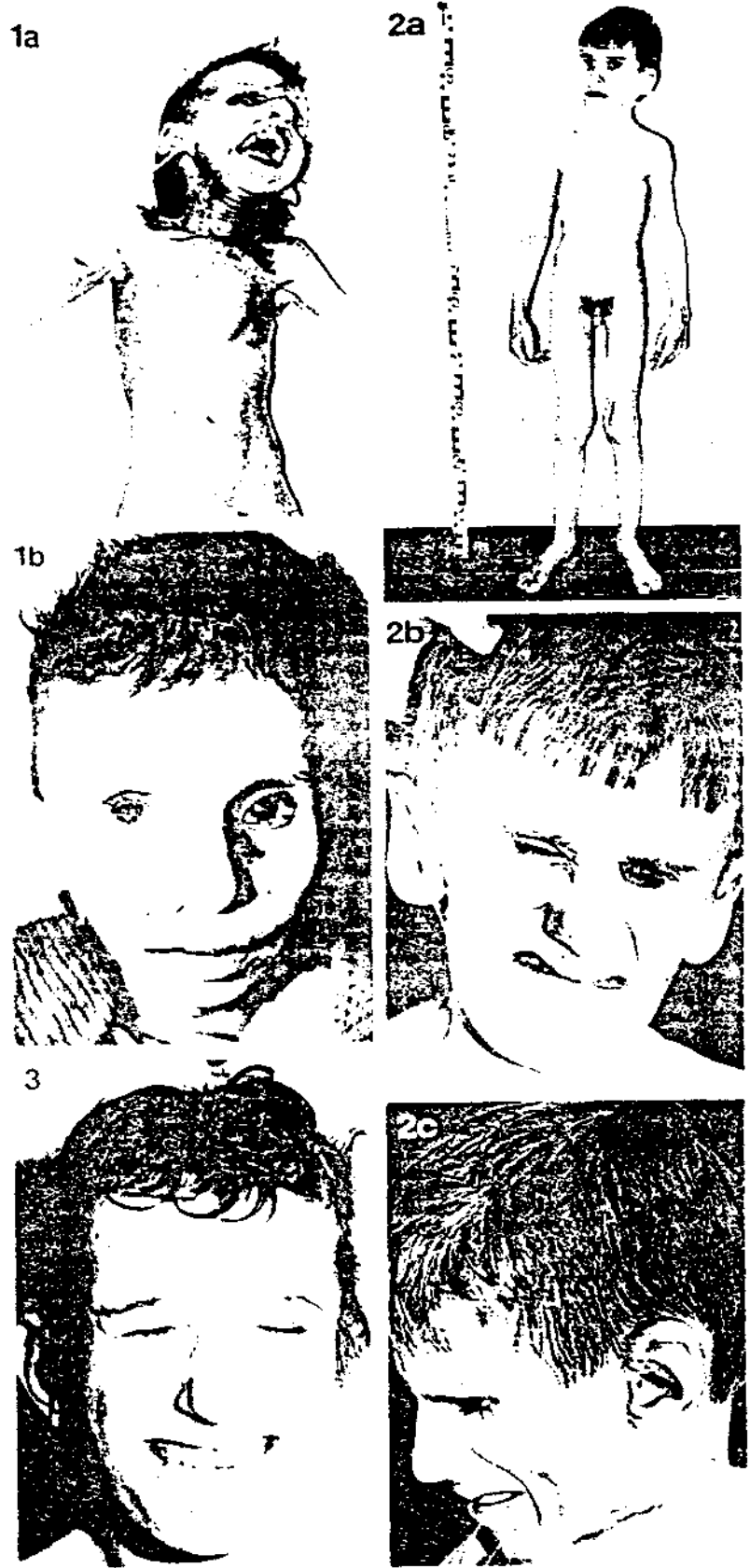


Fig 11 : Cockayne Syndrome

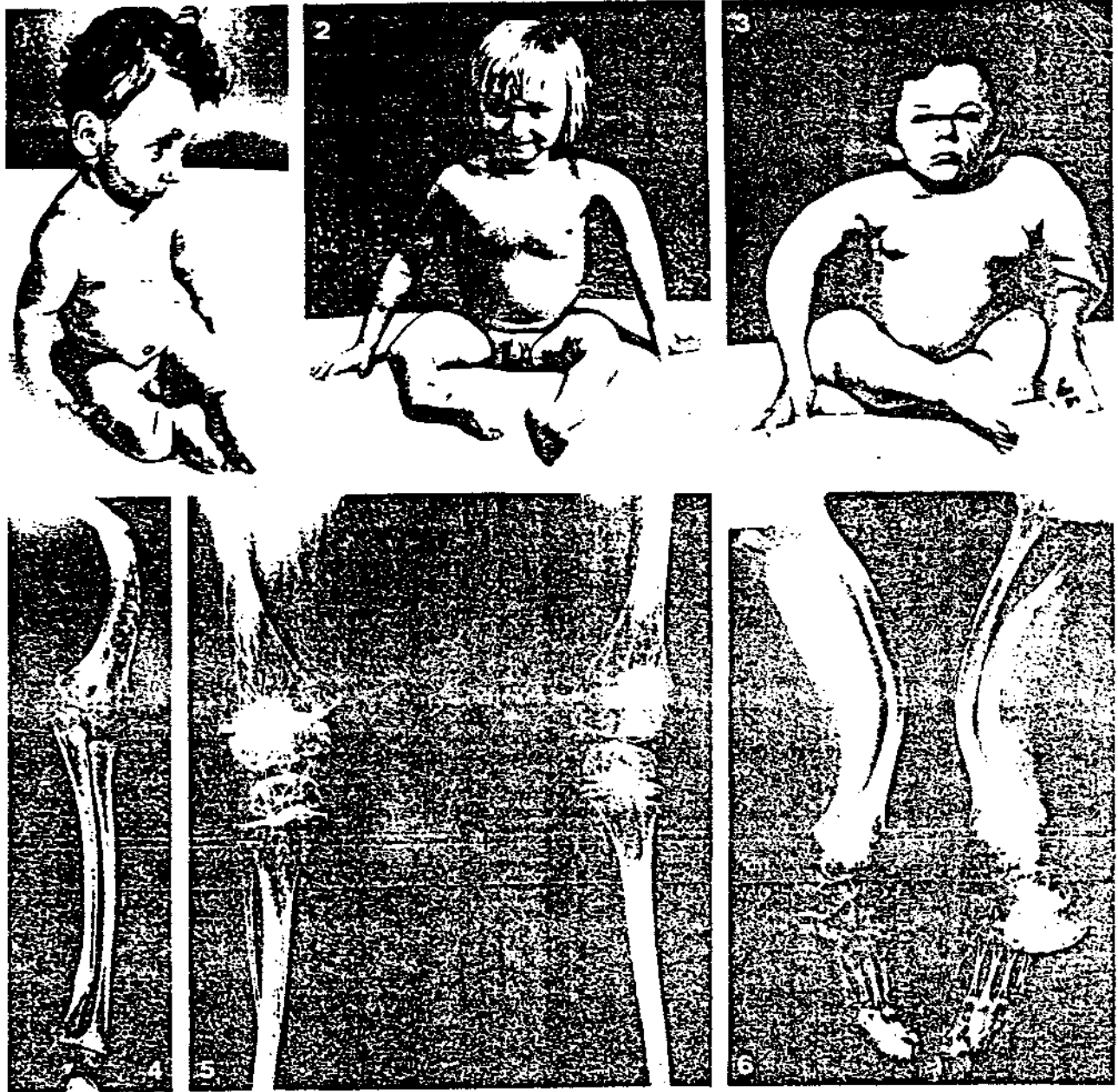


Fig 12 : Osteogenesis Imperfecta (Types I & IV) Syndrome

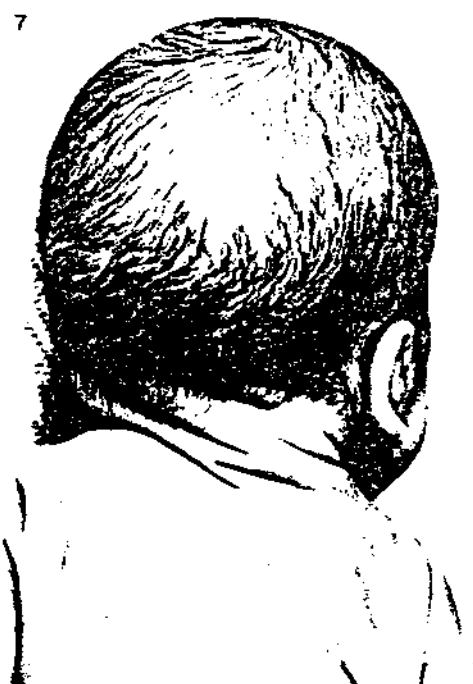
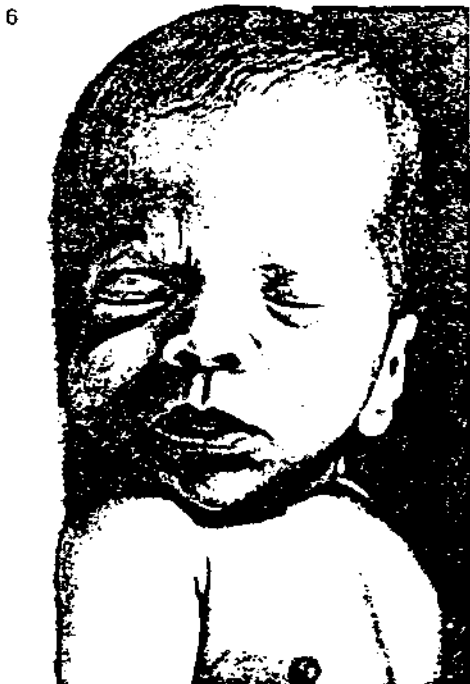
Fig 13 : Noonan Syndrome

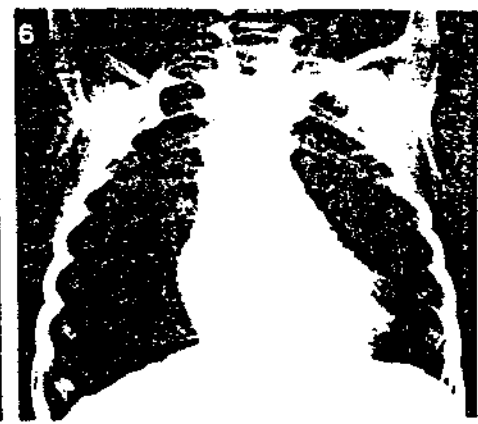
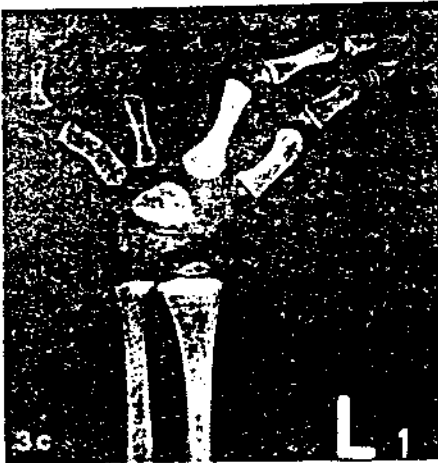
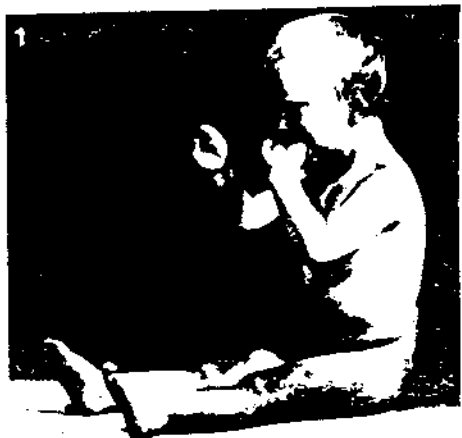

Fig 14 : EEC Syndrome

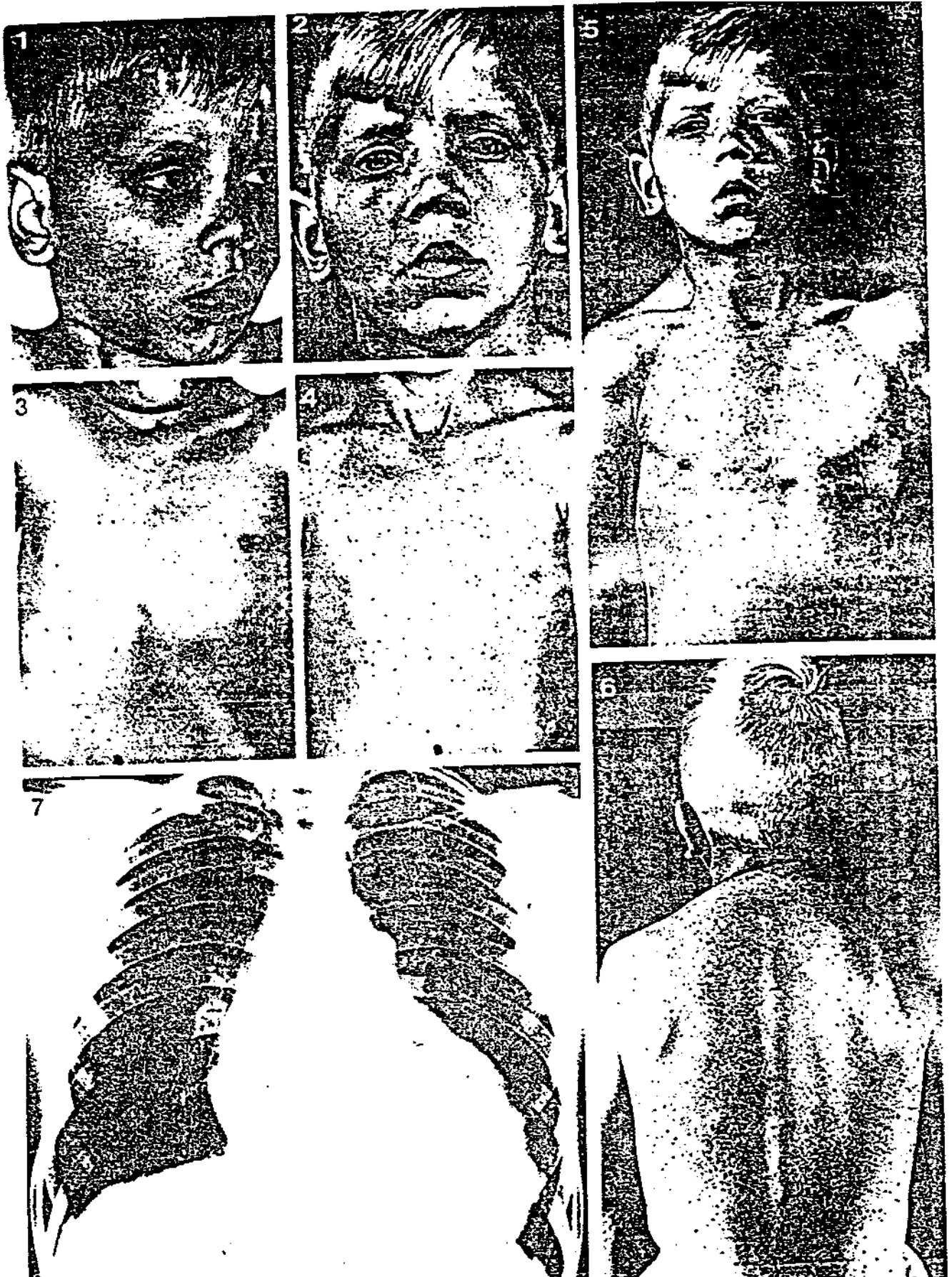


Fig 15 : Leopard Syndrome

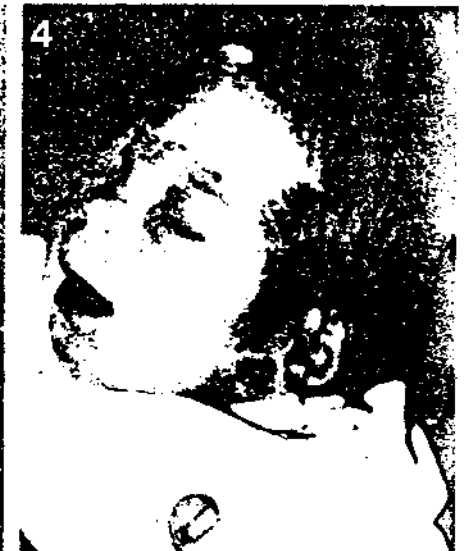

Fig 16 : Waardenburg Syndrome

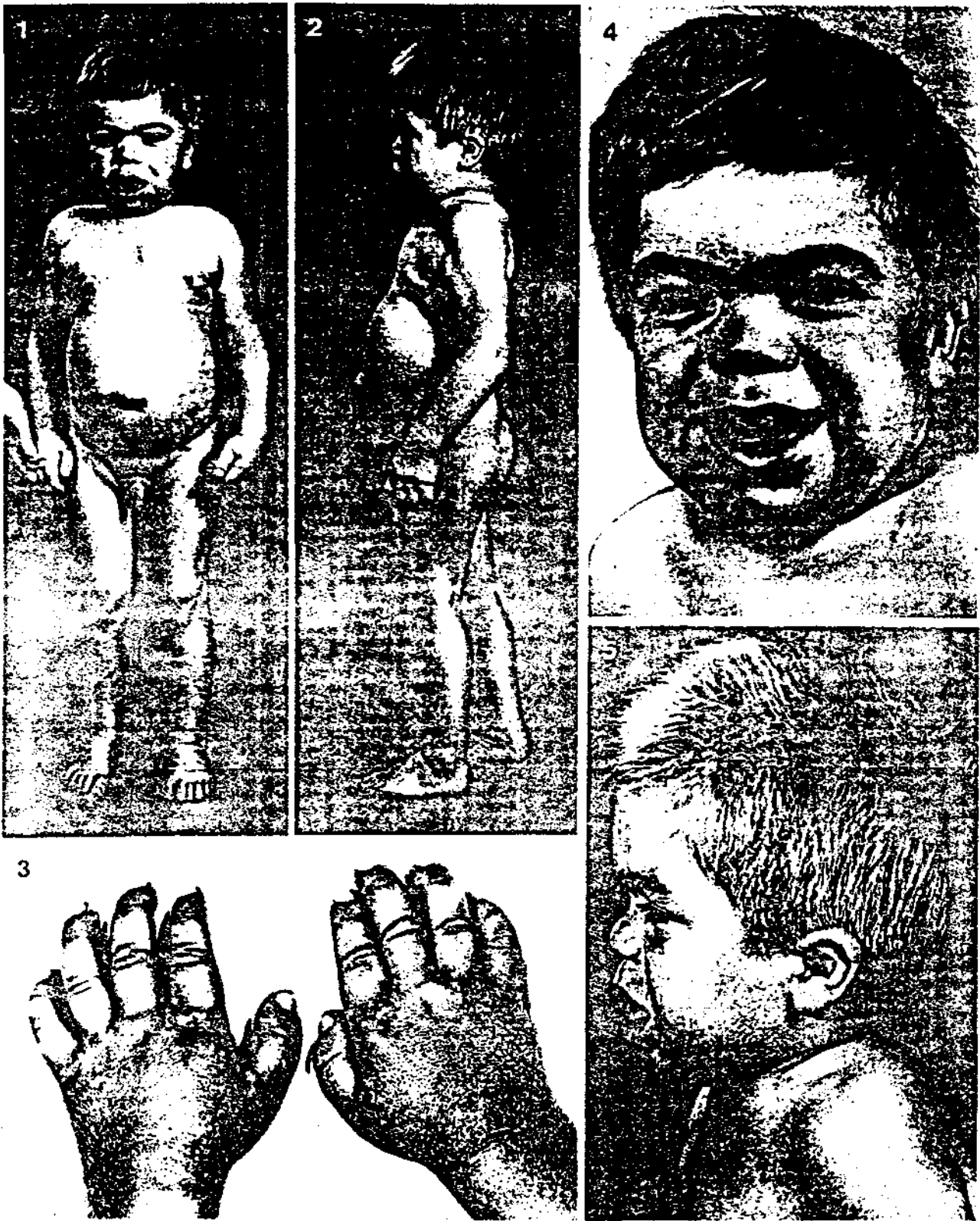

Fig 17 : Hunter's Syndrome

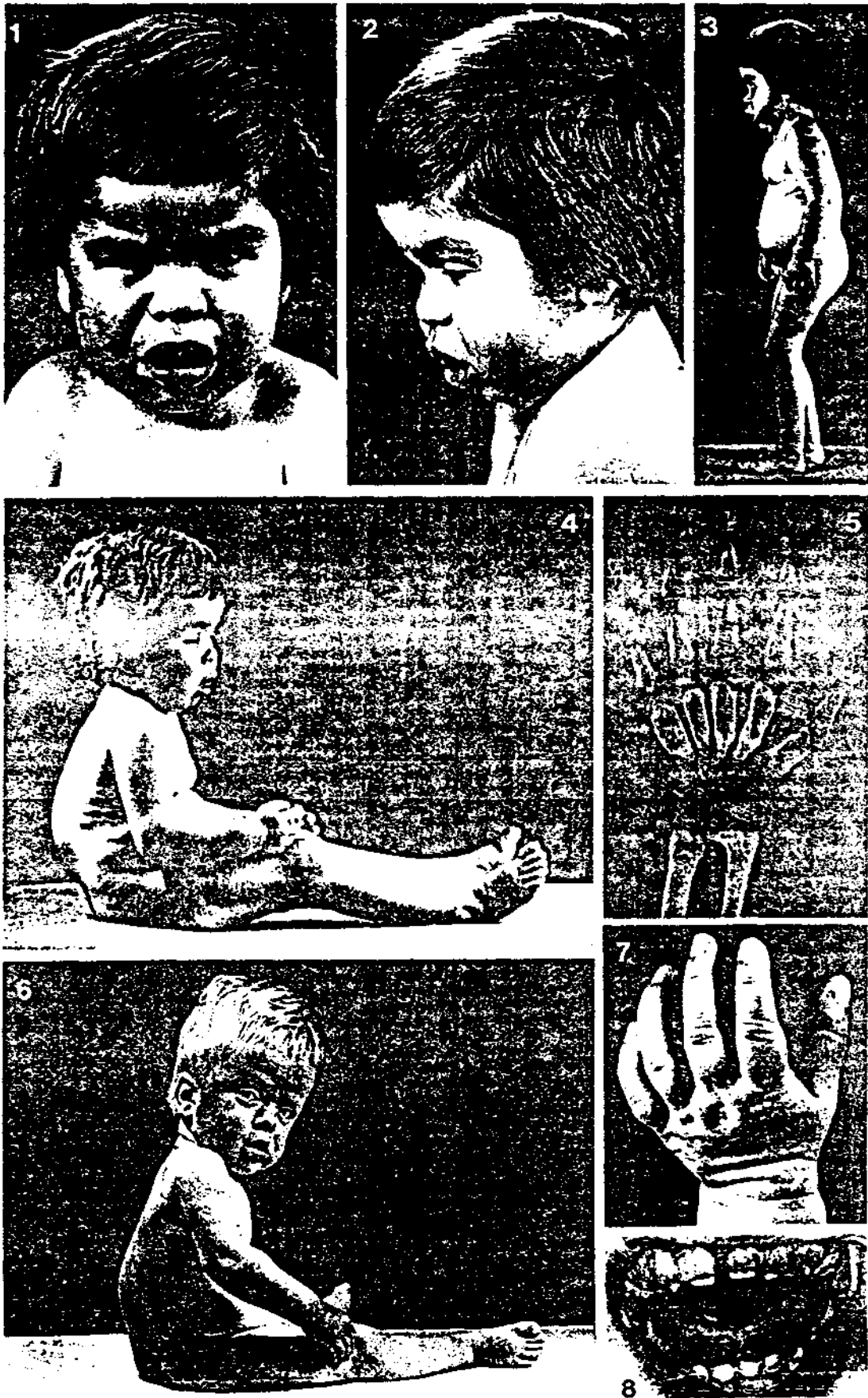

Fig 18 : Hurler Syndrome

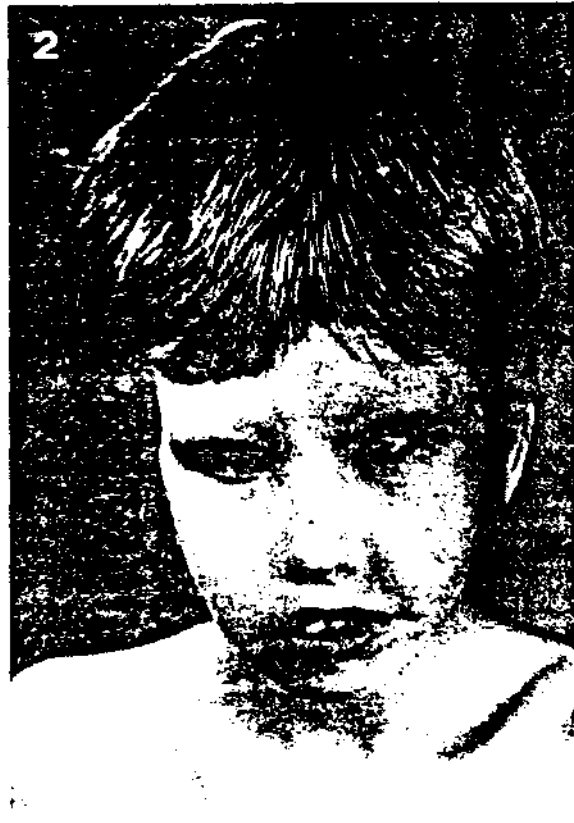
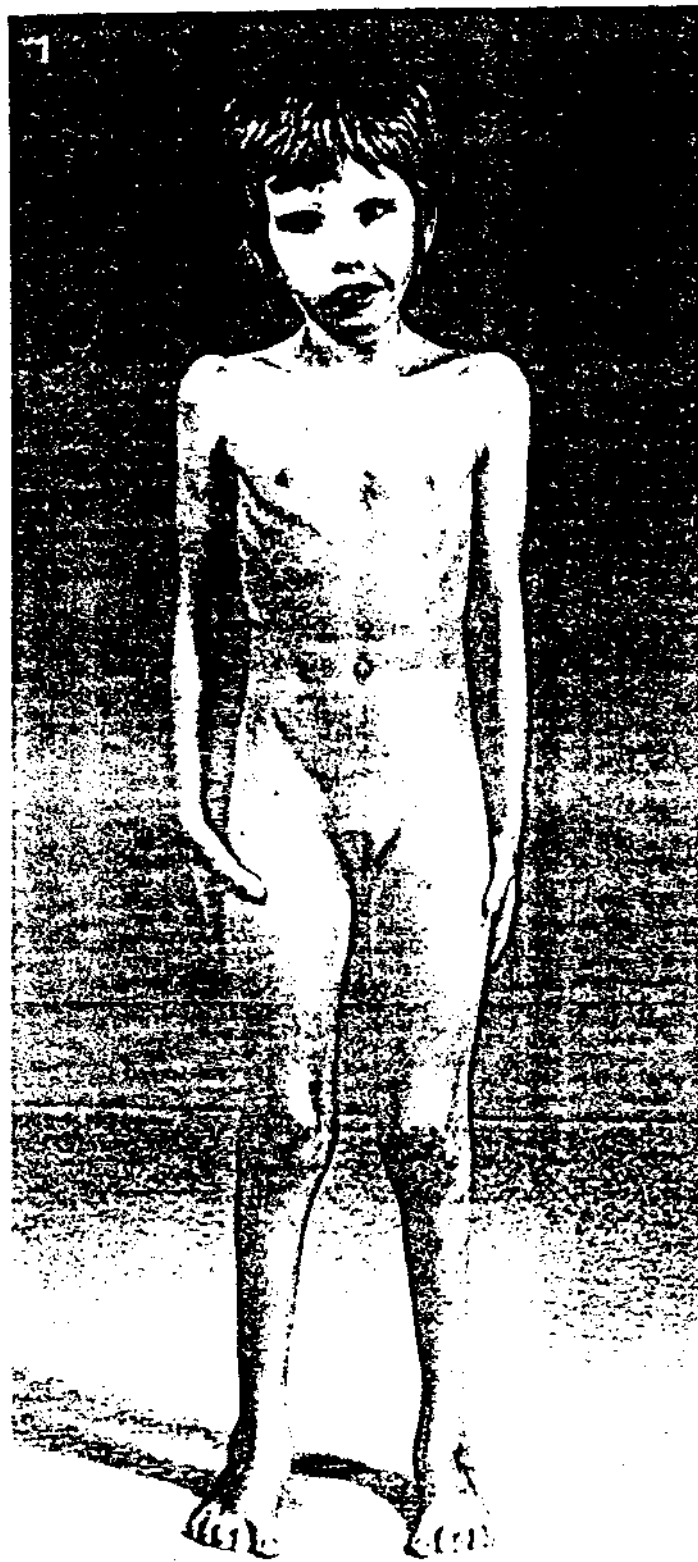
Fig 19 : Moebius Sequence Syndrome

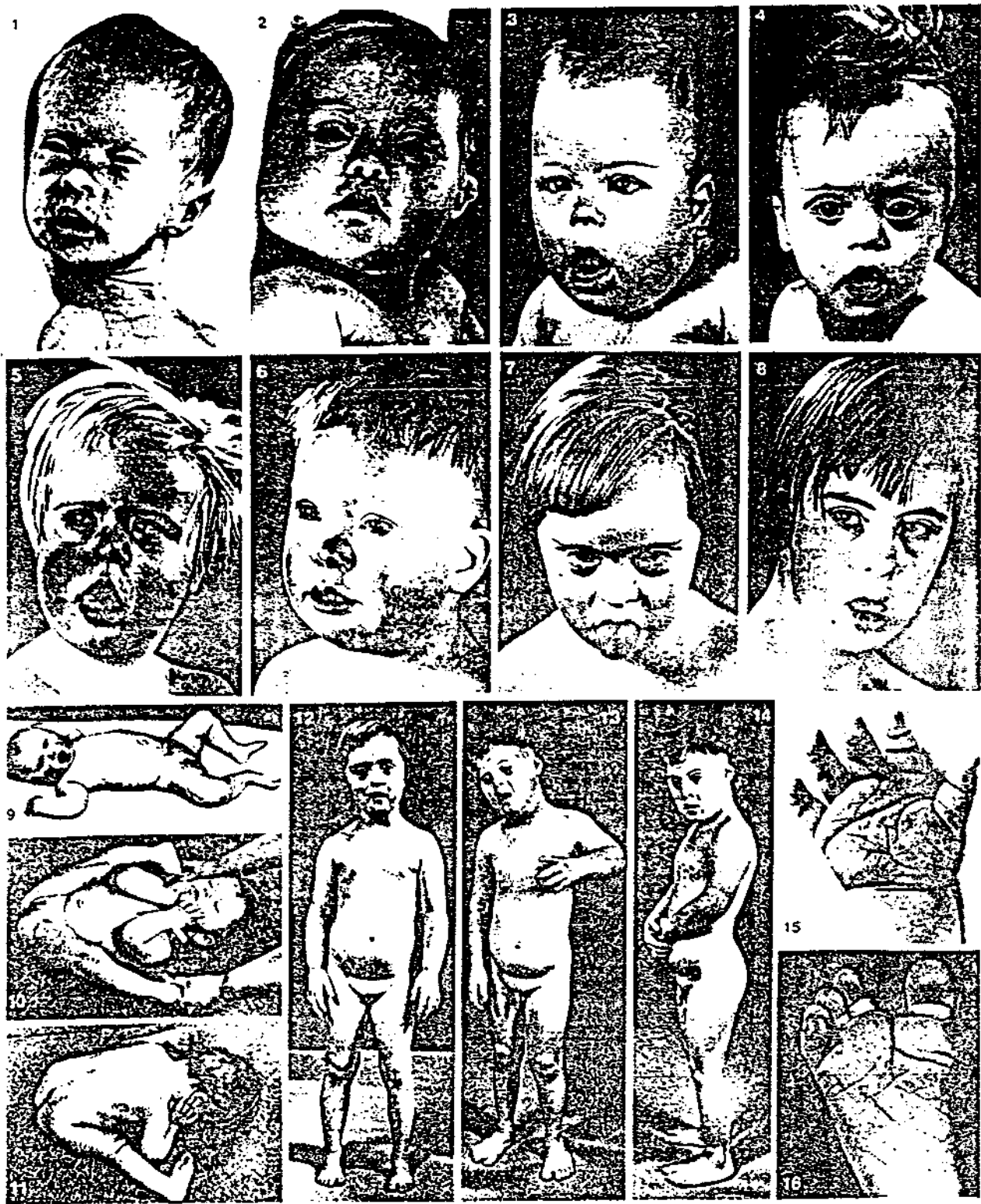

Fig 20 : Down's Syndrome

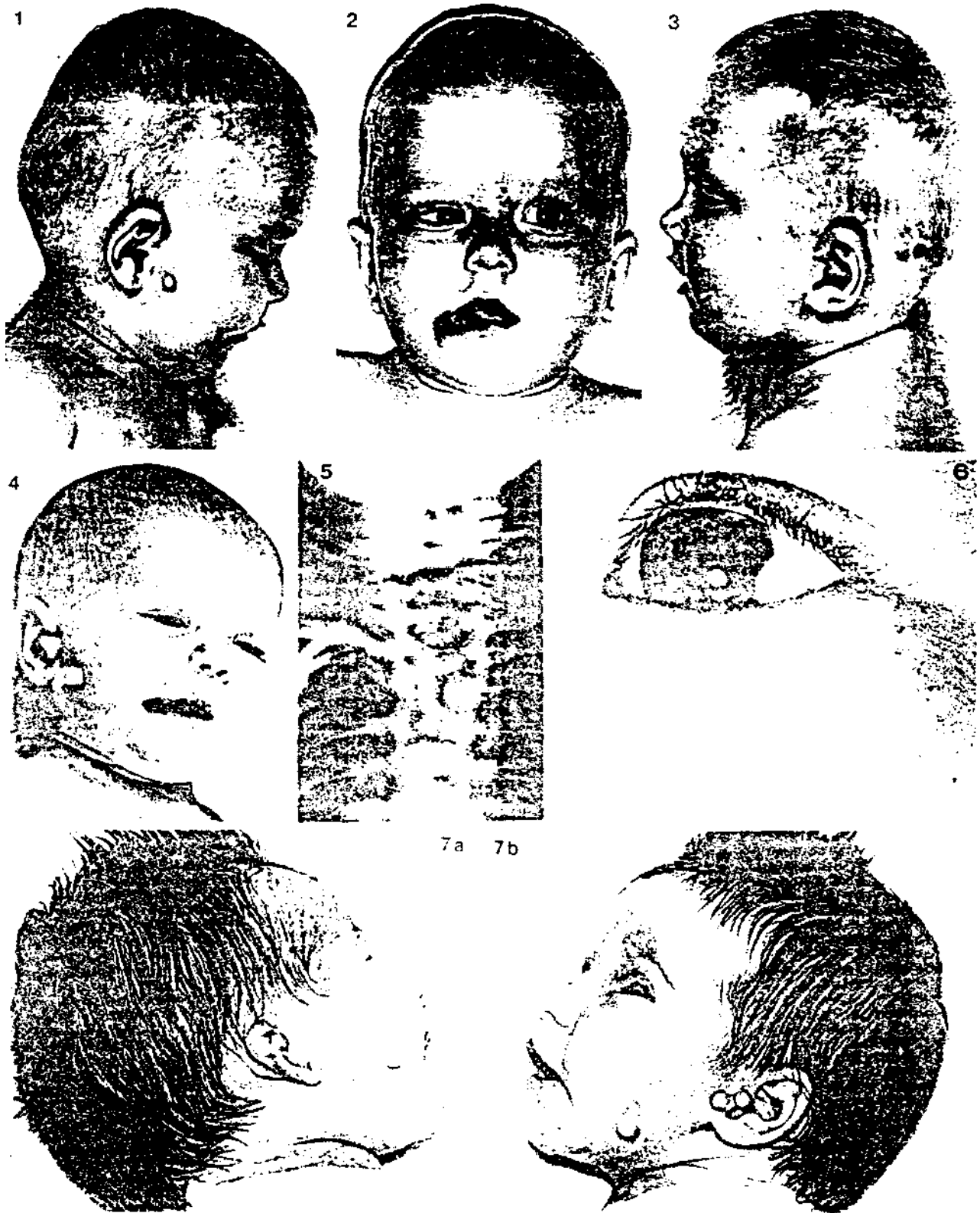

Fig 21 : Golden Har Syndrome

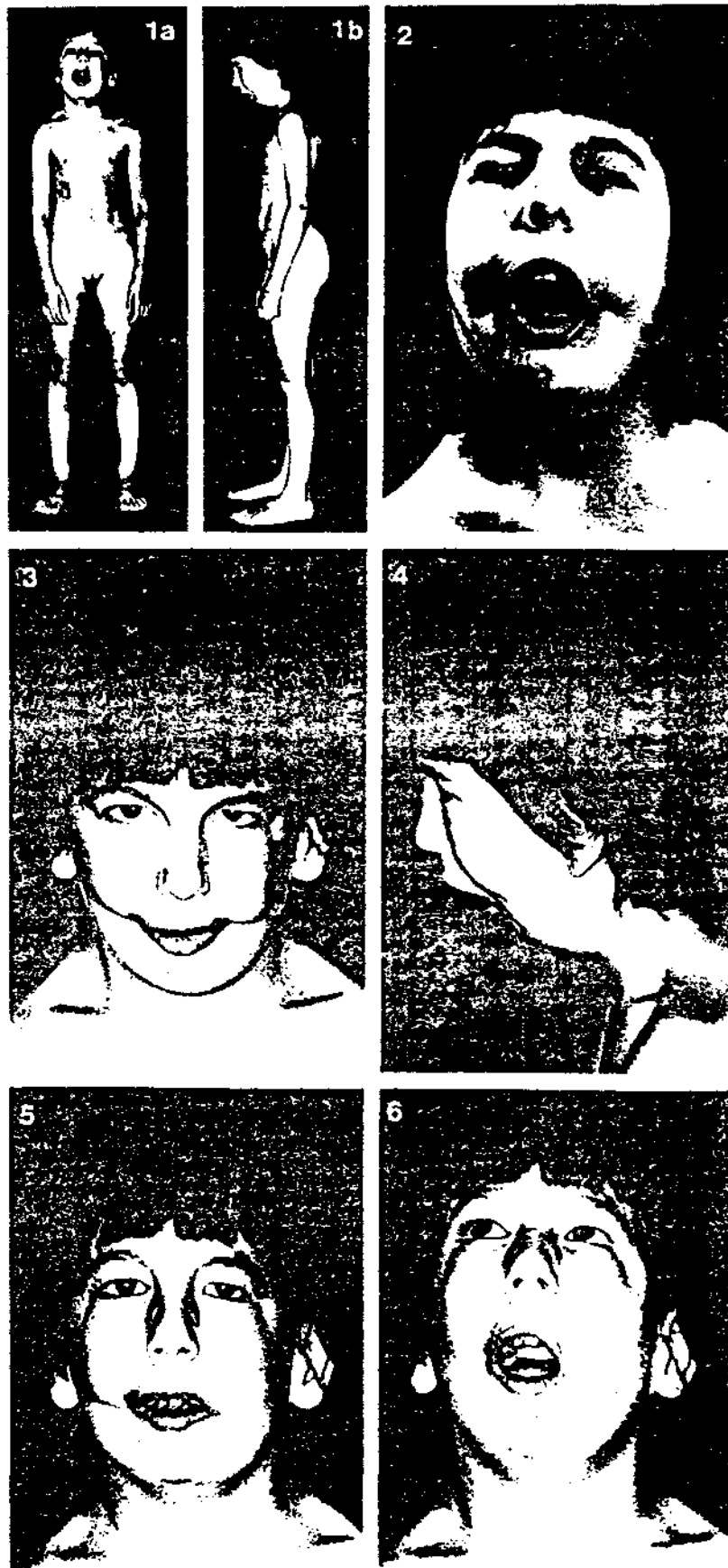


Fig 22 : Wilder Vanck Syndrome

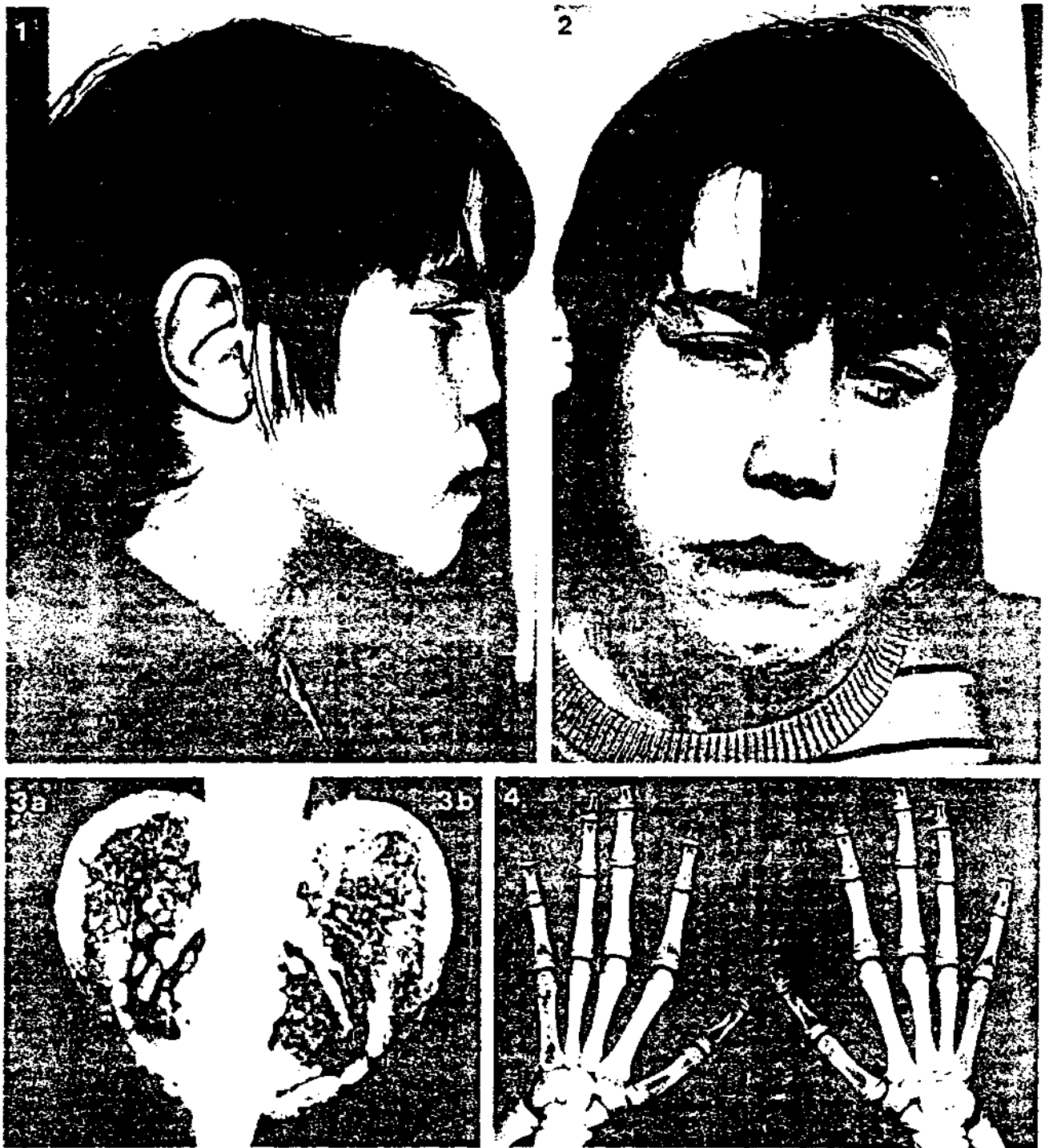

Fig 23 : Keutel Syndrome

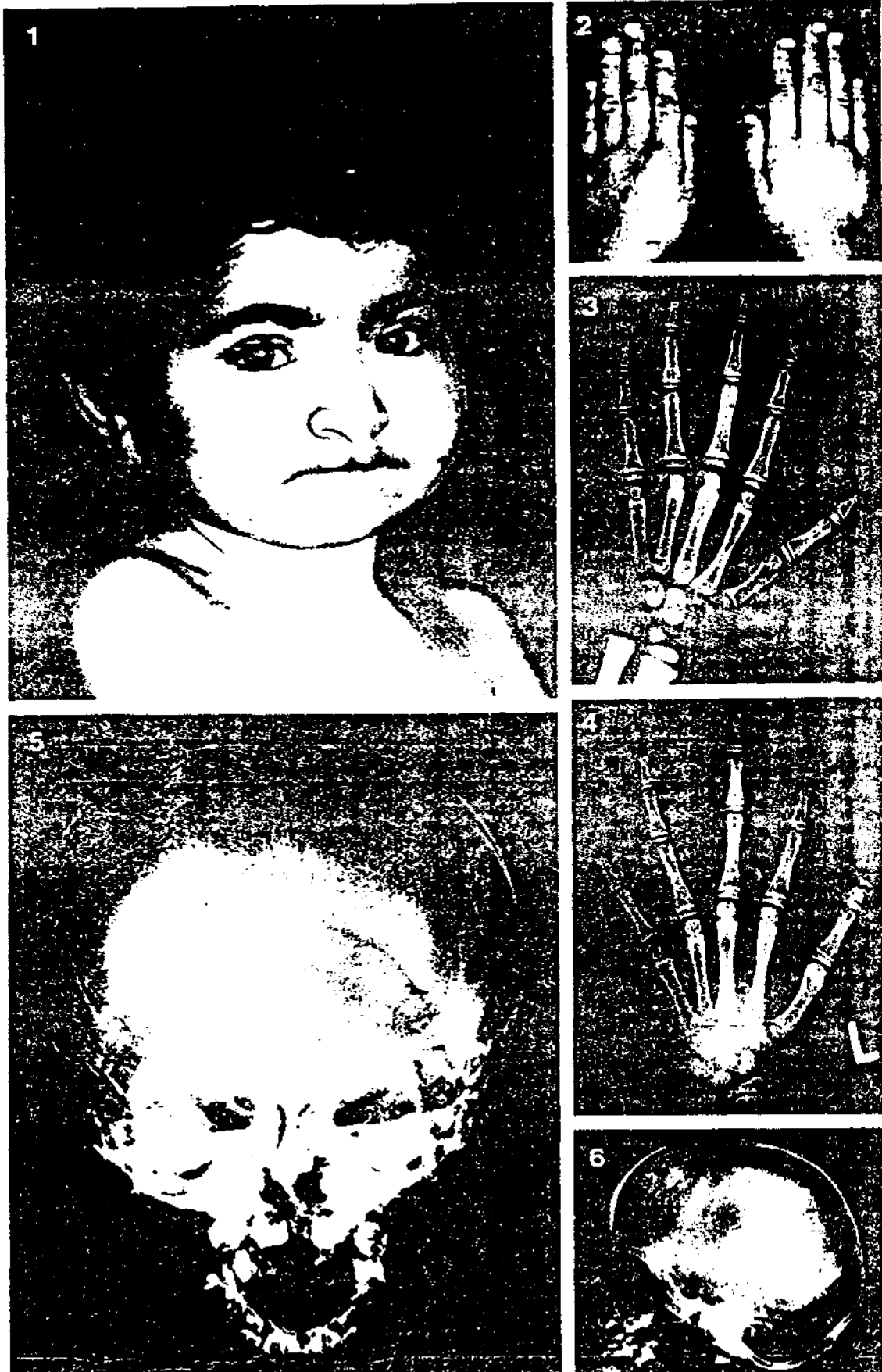


Fig 24 : Hajdu Cheney Syndrome

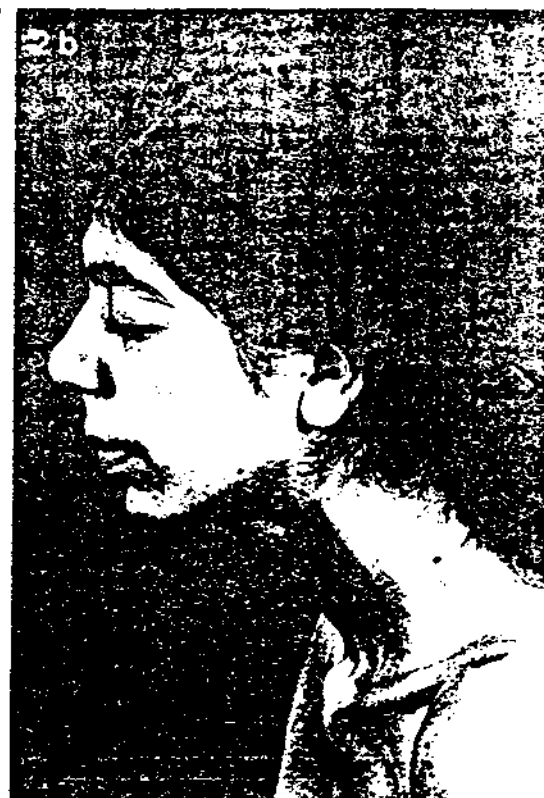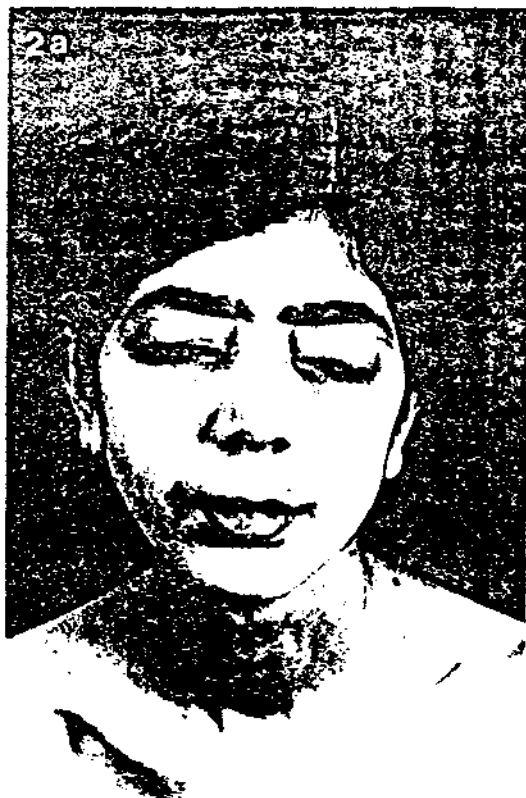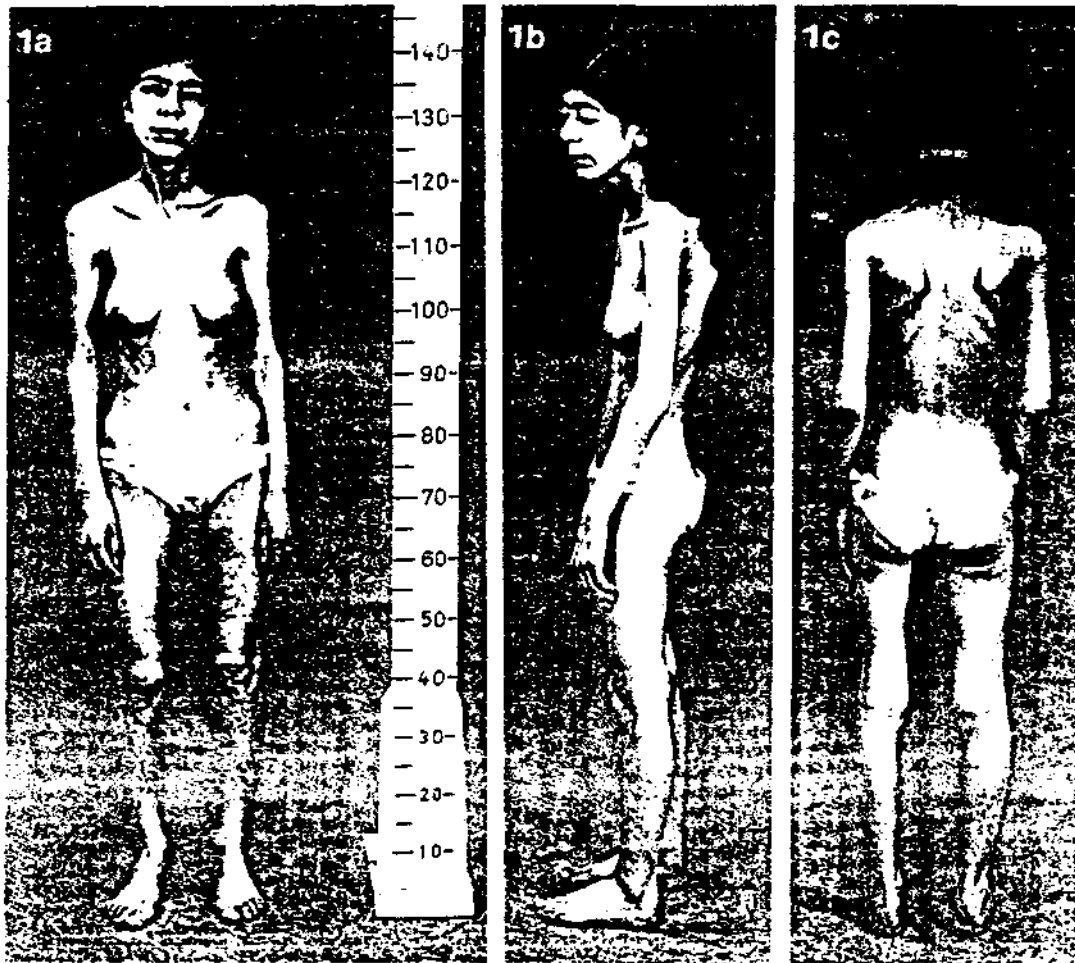


Fig 25 : Kearns Sayre Syndrome

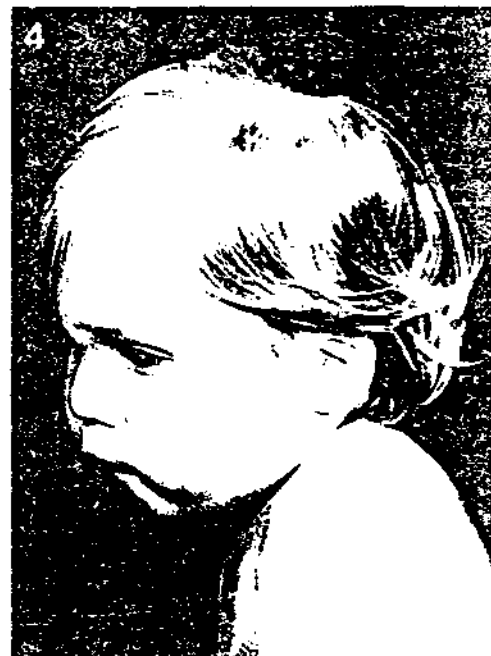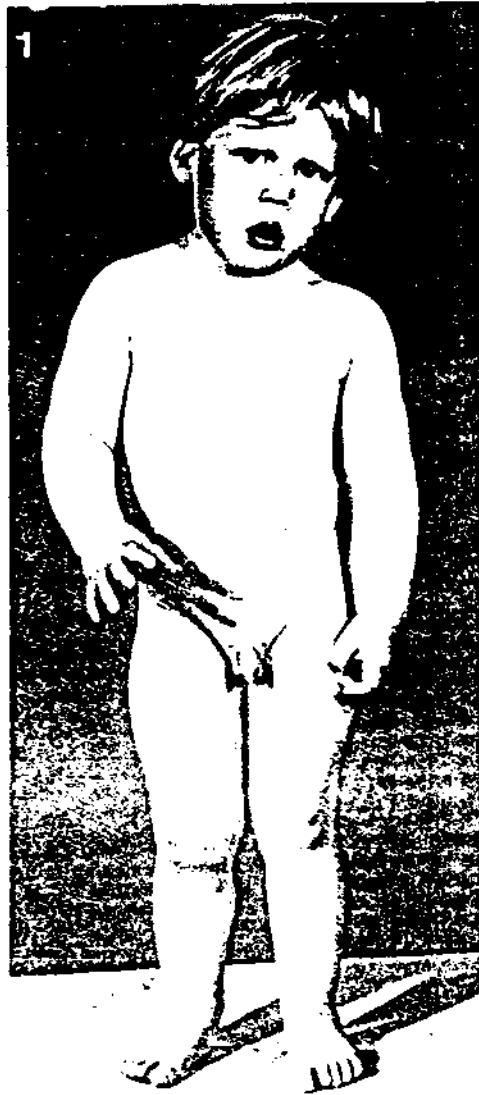


Fig 26 : Lacrimo-Auriculo Dento Digital Syndrome



Fig 27 : Hemifacial Microsomia Syndrome

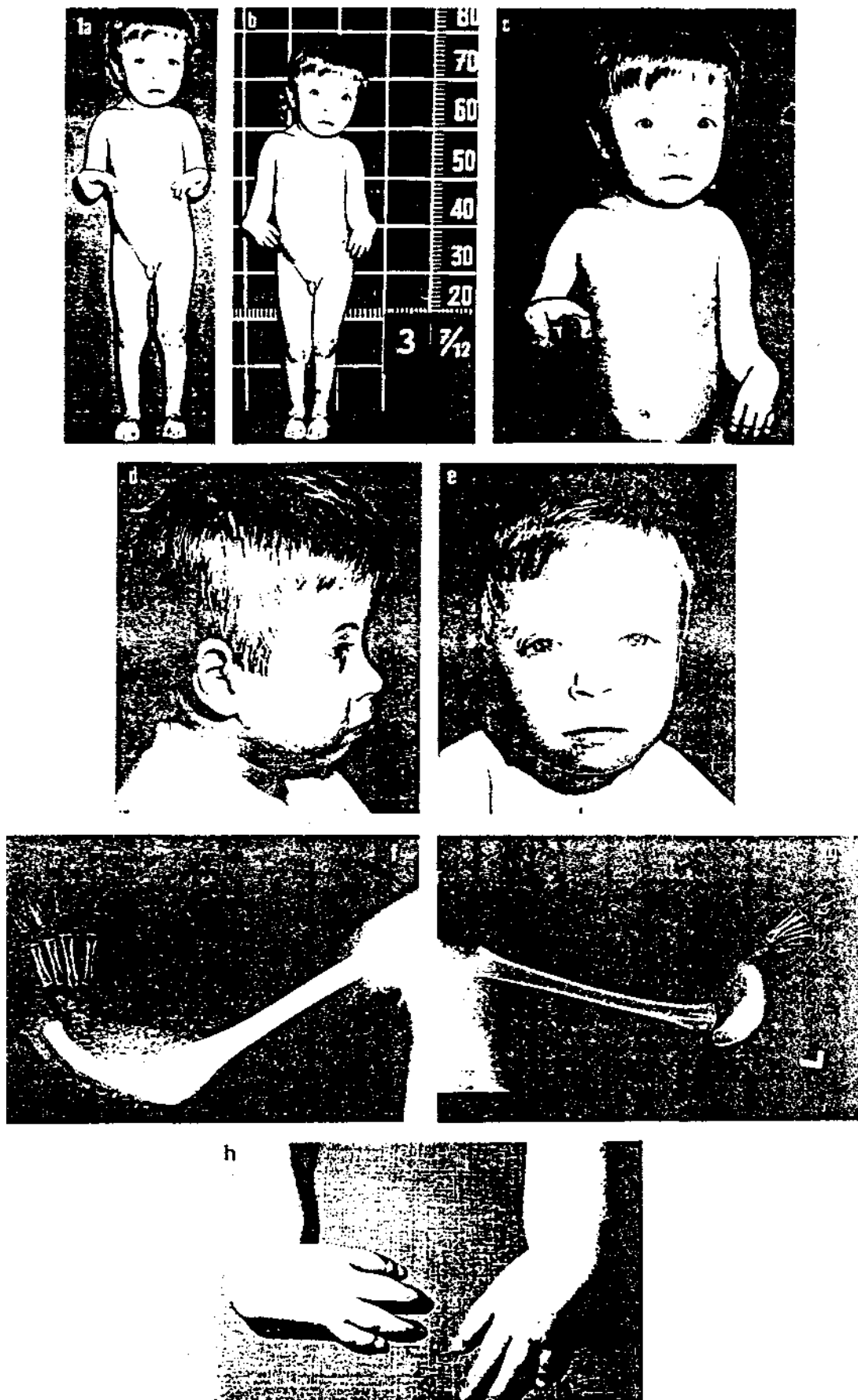


Fig 28 : Bailer - Gerold Syndrome

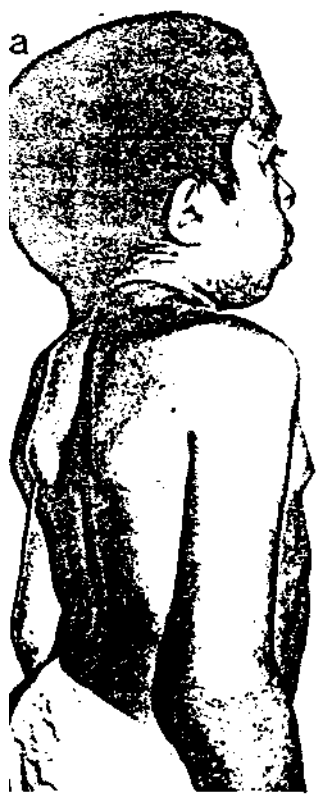
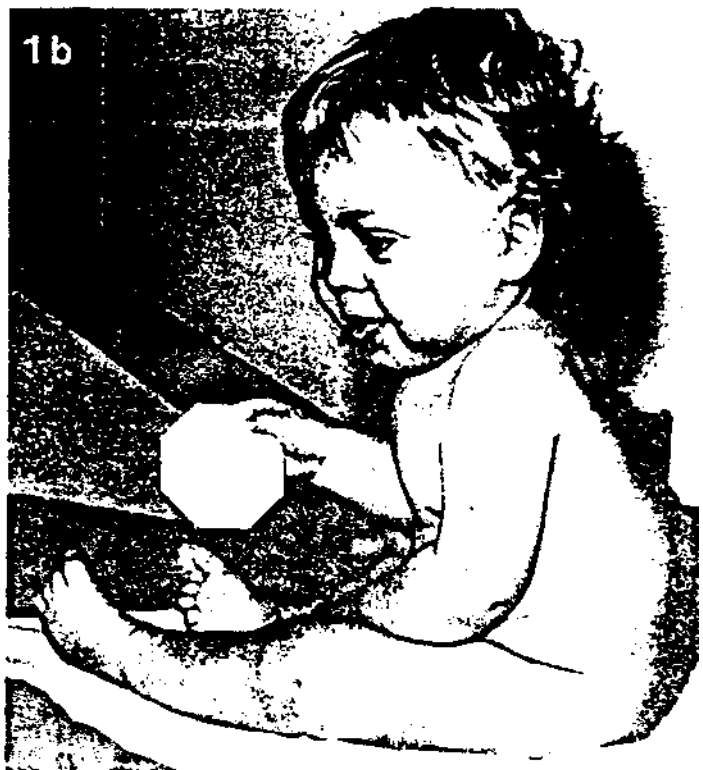

Fig 29 : Freeman Sheldon Syndrome

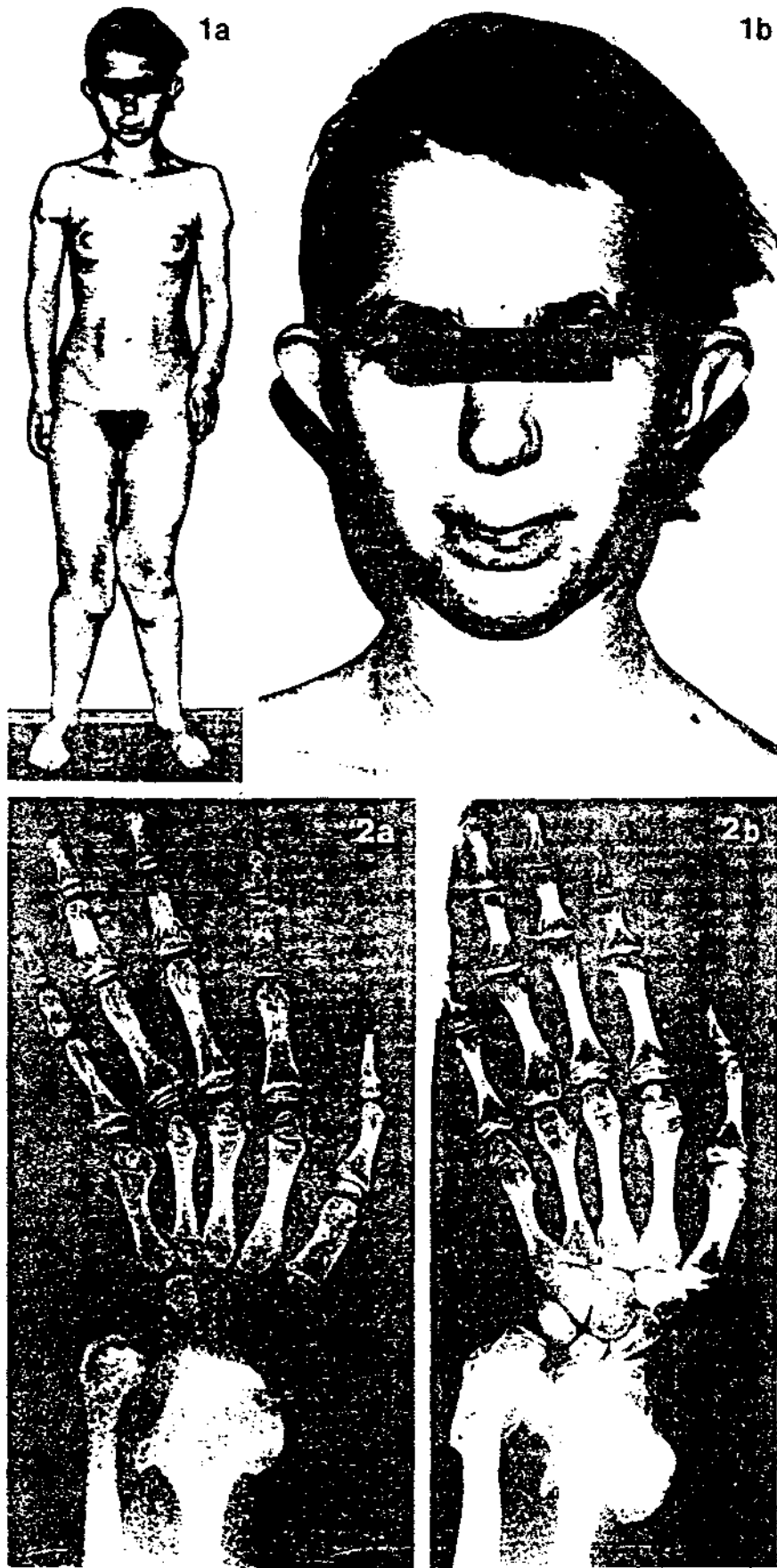


Fig 30 : Langer Giedion Syndrome

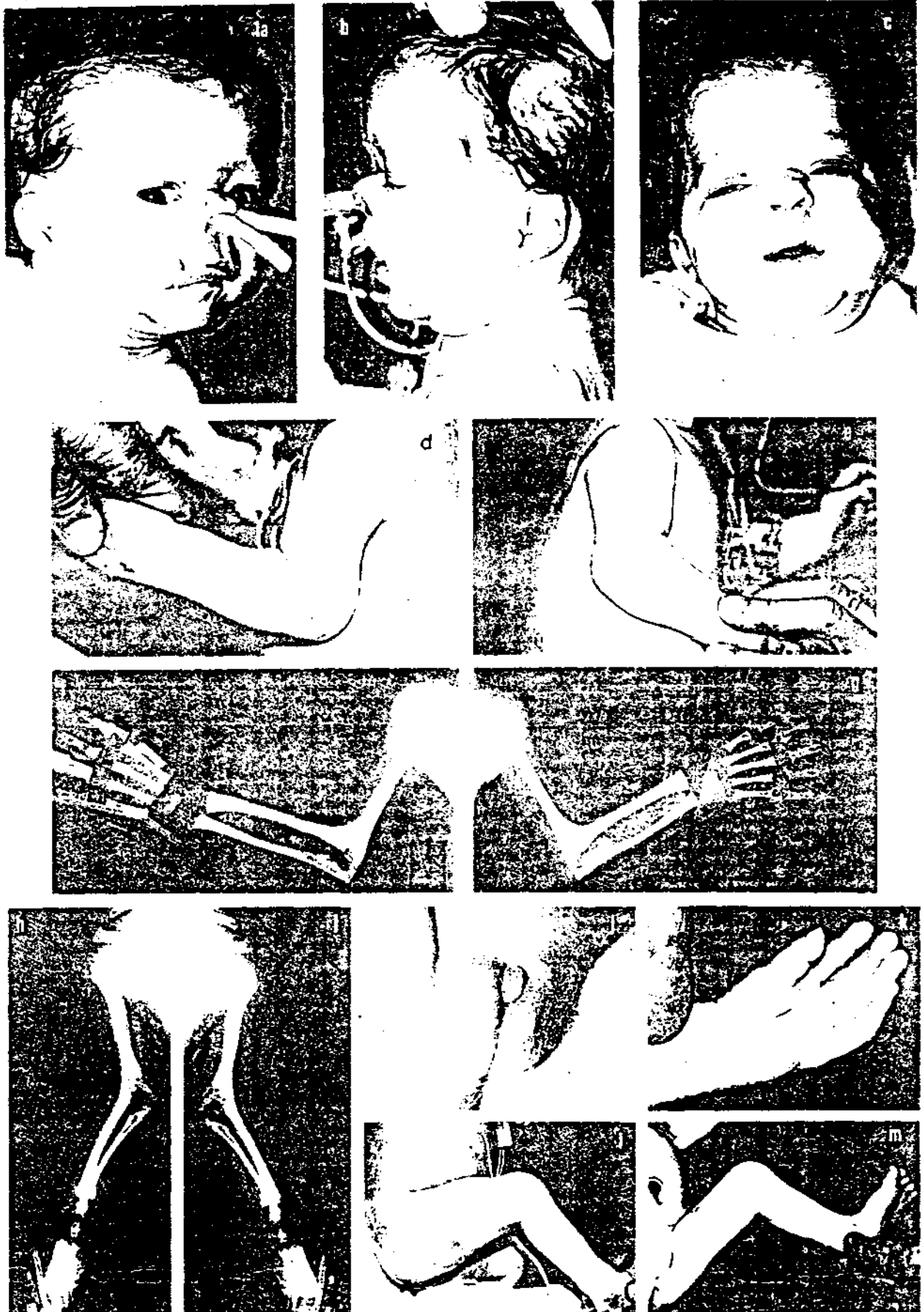


Fig 31 : Antley Bixler Syndrome

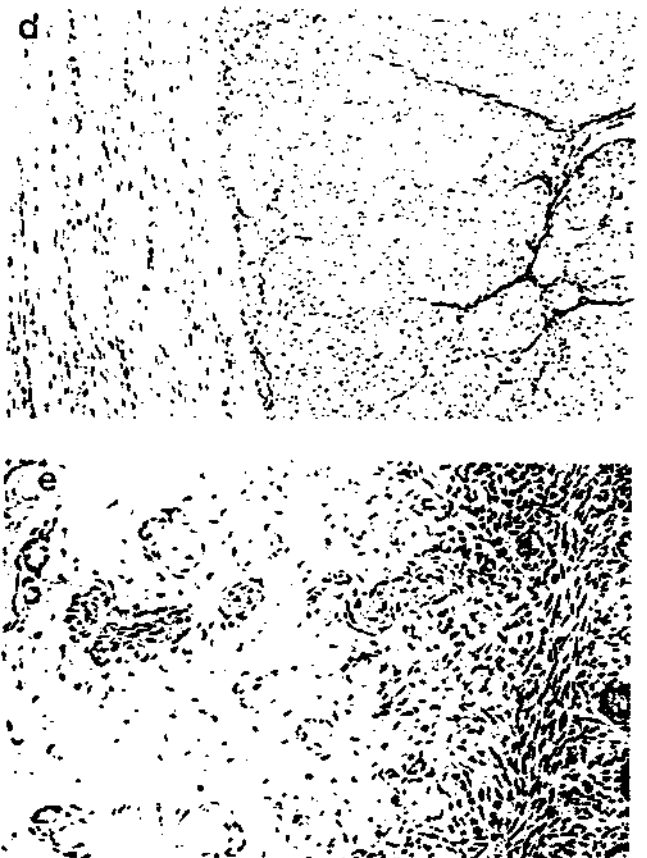
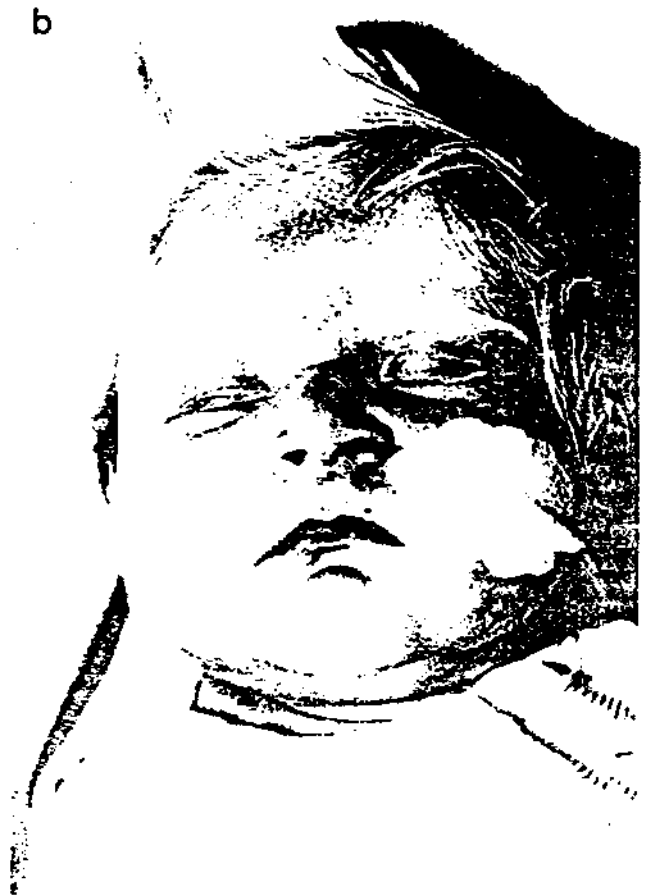

Fig 32 : ABCD Syndrome

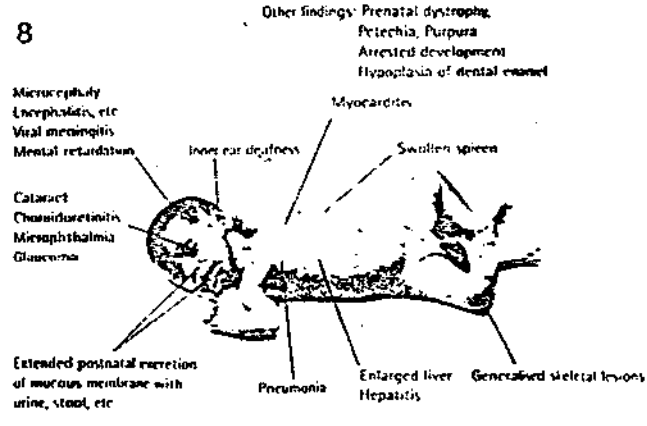
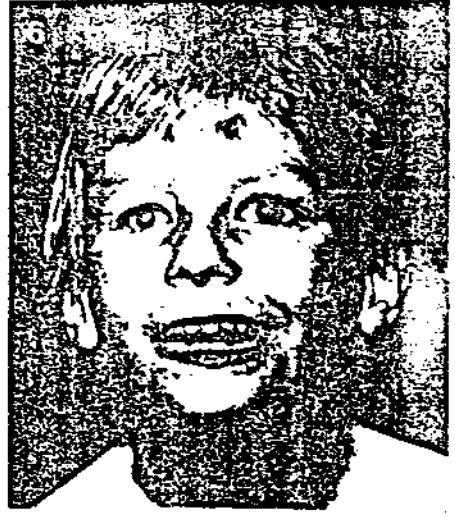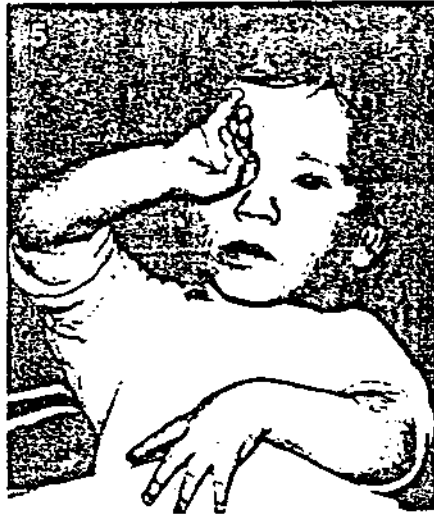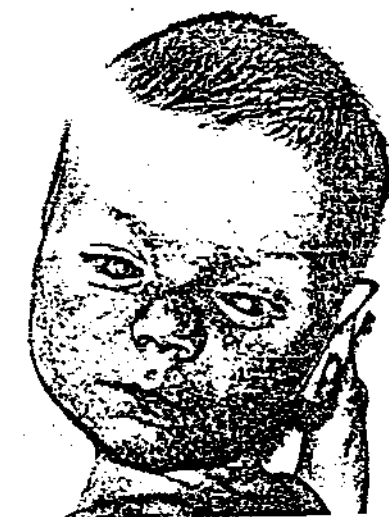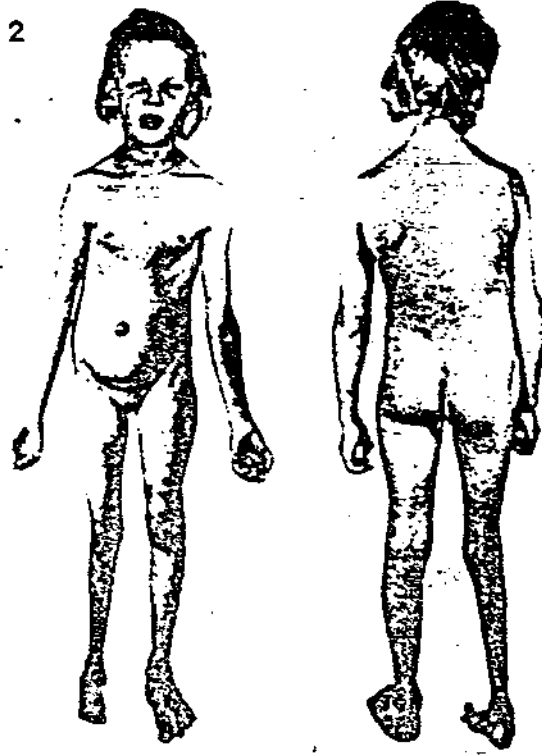


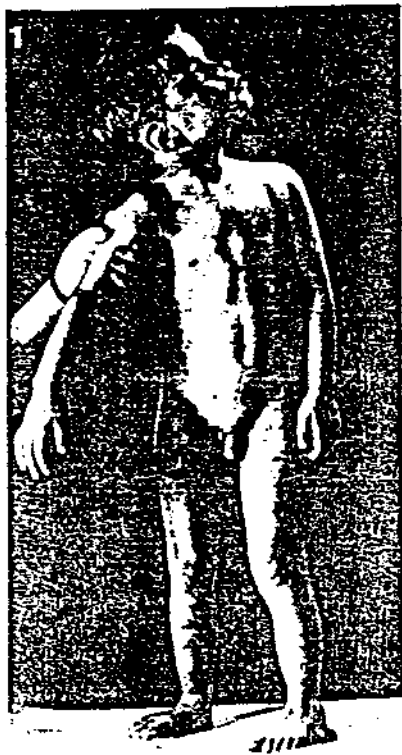Fig 33 : Rubella Syndrome

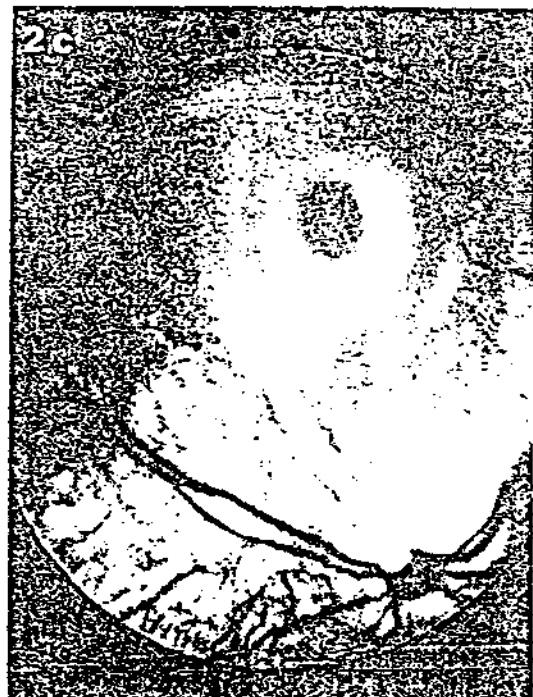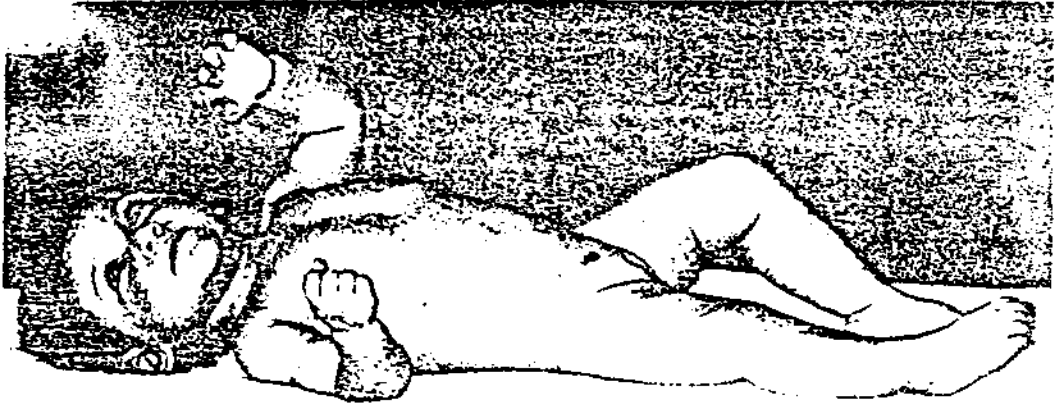



Fig 34 : Tay-Sach's Disease Syndrome

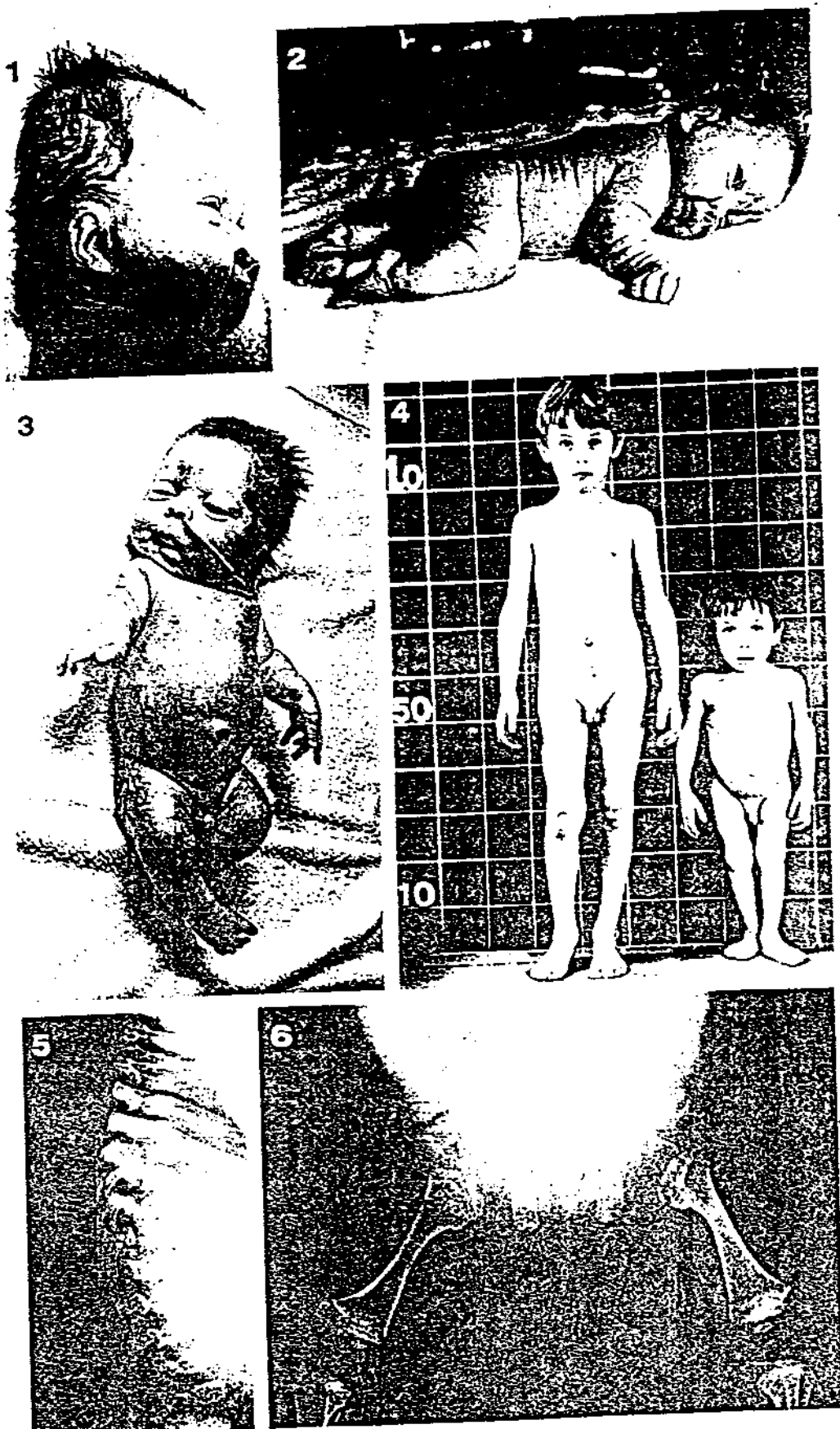

Fig 35 : Kniest Syndrome

Glossary of Genetic and Medical Terms

Abducens Palsy - a paralysis of the sixth cranial nerve.

Acentric chromosome - a chromosome that possesses no centromere for spindle fiber attachment

Achondroplasia - one of the more common forms of dwarfism.

Acrocentric chromosome - a chromosome in which the centromere (or spindle fiber attachment point) is close to one end of the chromosome.

Allele - a gene situated at a particular locus on a particular chromosome may exist in more than one form; the different forms of a particular gene are called alleles of that gene. Different alleles of the same gene produce different effects during development

Alzheimer's disease - presenile dementia usually associated with sclerosis or neurofibrillar degeneration.

Anenorrhea - lack of menstrual periods.

Amniocentesis - needle puncture of the uterus and amniotic cavity to allow amniotic fluid to be withdrawn by syringe. The term is often (loosely) applied to the whole procedure of prenatal diagnosis by culture and analysis of amniotic fluid cells or amniotic fluid.

Anencephaly - a form of spina bifida in which the brain fails to develop.

Aneuploidy - the occurrence of a chromosome number different from the usual number and not an exact multiple of the haploid number. An individual subject may be aneuploid, as in Down syndrome, or occasional cells within an otherwise diploid individual may be aneuploid.

Ankylosis - stiffening of a joint.

Anosmia - the inability to smell.

Arthropathy - a disease involving joints.

Association - the occurrence of two or more genetic traits together in the same individual. Association may be due to two linked genes, multiple (pleiotropic) effects of the same gene, or to the random association of two non linked genes in the same individual.

Ataxia - loss of coordinated muscle movements.

Atresia - severe underdevelopment of an opening or passage resulting in pathologic closure.

Autosomal linkage - the linkage of two genes on an autosome.

Autosome - any chromosome other than a sex chromosome.

Banding - the techniques of staining chromosomes in a characteristic pattern of cross bands, thus allowing individual identification of each chromosome pair. Giemsa banding (G banding) and Quinacrine fluorescence banding (Q banding) are best known banding techniques.

Brachycephaly - Shortness of the anterior to posterior diameter of the skull.

Brachydactyly - shortness of the fingers.

Brushfield spots - the hypopigmented spots that can be seen in the irides of certain individuals with Down syndrome.

BSEER (Brainstem Evoked Response Audiometry) - averaging responses produced by the auditory nerve and the brainstem following the onset of tone bursts. This procedure may be used to measure hearing activity.

Oantbus - the corner of the eye slit.

Carriers - individuals carrying a gene and capable of passing it on, but who do not themselves show the full effects of the gene because : (1) the individuals may be heterozygote for a recessive gene or for a gene that produces only slight effects in single dose; (2) the gene may be a late acting one, the subject being examined before the gene has expressed itself ; and (3) the effects of the gene may be masked by other genes called modifier genes, or by environmental modifiers.

Centromere - the constricted region of a chromosome where spindle fibers attach during cell division.

Cholesteatoma - amass (i.e., tumor) of skin- like tissue which invades the middle ear and the mastoid spaces. The growth of the tumor may be caused by a perforation of the tympanic membrane or chronic otitis media.

Chorion Frondosum - the part of the fetal membranes that develop into the fetal part of the placenta.

Chorionic villas sampling - a relatively new prenatal diagnostic technique which involves obtaining tissue from the developing area of the placenta known as the chorion.

Chorioretinitis - inflammation of the choroid membrane and retinal structure of the eye.

Chromosomes - structural elements of various sizes found in the nucleus of a cell and containing the major part of the hereditary material (the genes). The main chemical components of a chromosome are proteins and DNA. They are capable of self-duplication, thus ensuring that identical genetic material is handed to each of the daughter cells resulting from cell division.

Clinodactyly - abnormal incurving of the fingers.

Contraction of the aorta - a narrowing of the aorta, the major artery leading from the heart.

Coloboma - a clefting defect of the eye which may involve iris, choroid, or retinal structures.

Condyle - the rounded articular surface of a bone.

Congenital - present at birth. No necessary connotation as to genetic or nongenetic causation (e.g., the rubella syndrome is congenital but nongenetic).

Consanguineous union - union between biologically related individuals, that is, individuals having one or more ancestors in common. Various degrees of consanguinity are recognized.

Cranio synostosis - premature fusion of the cranial sutures.

Cryptorchidism - undescended testes.

Cubitus Valgus - observed bending of the extended lower arm to the outside of the upper limb axis due to a difference in elbow joint anatomy.

Cutis morata - a marbled appearance of skin usually due to an abnormality in vasculature.

Cytogenetics - a branch of genetics dealing with the cytological basis of heredity, that is, with the study of the chromosomes, particularly during the cell division and the relationship of chromosome variation to the genotype and phenotype of the individual.

Cytomegalic inclusion disease - significant problems that are the result of cytomegalovirus infection in utero. Characteristically, inclusion bodies can be demonstrated with certain cells after infection.

Deletion - the loss of a segment of a chromosome.

Dentinogenesis imperfecta - opalescent dentin due to a hereditary defect of dentin formation.

Diploid - possessing a double set of chromosomes, one set of which was derived from the mother and one set from the father (synonym : $2n$).

Dizygotic twins (dizygous or DZ twins) - twins resulting from the fertilization of two ova by two spermatozoa (synonym: fraternal twins).

DNA (deoxyribose nucleic acid) - the main chemical component of the genetic material in chromosomes. The Watson-Crick theory of DNA structure provides a basis for understanding both how chromosomes replicate themselves and how genetic "information" is stored in the genetic material. The DNA molecules are composed of nucleotides in the form of a chain. Each nucleotide contains an organic base (adenine, guanine, thymine, cytosine), a sugar (deoxyribose), and a phosphate. The specific nature of the genes is based on the specific nature of the genes is based on the specific sequence of base pairs in the molecule.

Dominant gene - a gene that expresses its effect even when it is present only in single doses, that is in the presence of a different (recessive) allele. Dominance may be complete when the full effect of a gene is produced in single dose, or incomplete (partial) when gene produces an easily detectable effect in a single dose but a more marked effect in a double dose.

Duplication - the occurrence of a chromosome breakage and reunion of noncorresponding ends (unequal crossing-over).

Dysmorphic - abnormality of form or shape.

Dysplasia - abnormal development of tissue.

Ectodermal - those parts of the body derived from the outer layer of cells in an embryo (e.g., skin, hair).

Ectrodactyly - congenital absence of one or more digits of the hands or feet.

Empirical risk - the prediction of the probability that a genetic or congenital abnormality will recur in a family in which it has already occurred. The empirical

risk figures are based upon the study of the reproductive history of couples who have borne a child who is malformed or otherwise disabled.

Epicanthal folds - the folds of skin sometimes seen on the inner aspect of the palpebral fissure and may overlap the inner canthus. Commonly seen in the Asian population and as a feature of certain syndromes such as Down syndrome.

Epitympanum - the portion of the tympanic cavity (middle ear cavity) extending beyond the superior border of the tympanic membrane.

Exophthalmus - abnormal protrusion of the eye- balls.

Exostosis - a bony tumor/protruberence on the surface of a bone.

Expressivity - the degree of severity of expression of a gene in a particular individual. Some genes are of variable expressivity, such as that for the symptom triad of blue sclerae, brittle bones, and deafness; some of those possessing this gene show all three effects, where as others may show only two, or even one, of the three possible effects of the gene.

Familial - the situation where several individuals in a family group are affected, not necessarily the result of a genetic mechanism.

Fertilization - fusion between the male gamete (spermatozoon) and the female gamete (ovum). The essence of fertilization lies in the combination of a haploid set of maternal chromosomes with a haploid set of paternal chromosomes.

Fibroblast - a connective tissue cell such as skin.

Fistula - a sinus or passage leading from one organ surface to another.

Frontal bossing - prominence of the forehead.

Fungiform papillae - minute elevations on the tongue.

Gamete - a mature male or female reproductive cell; spermatozoon or ovum; normally, with a haploid set of chromosomes.

Gametogenesis - the process of formation of sperm and eggs.

Gene - a unit situated at a particular locus on a chromosome, concerned with the determination of a specific protein or protein-like material.

Genetic counseling - guidance to individuals about the possibility of occurrence or recurrence (in instances where a known condition has already occurred) of specific genetically determined defects in themselves or close relatives, especially future children.

Genetic heterogeneity - a certain phenotype can be produced by two or more different genetic mechanisms.

Genetic marker - a readily "recognizable" gene or chromosome which can be used in family and population studies to mark the route of transmission or frequency of that particular gene or chromosome.

Genome - a complement or complete set of genes, characteristic of a species or an individual.

Genotype - the genetic make up of an individual; this may refer to one locus or several loci.

Glomerulus - the capillary tufts associated with the nephron of the kidney.

Glossoptosis - downward displacement of the tongue.

Gonadal - relating to the gonads (testis or ovary).

Hallux - the large toe.

Haploid - Possessing a single set of chromosomes, as in the reproductive cells (synonym: In).

Hemizygous - a state in which only the allele of a particular genic locus is present in a nucleus such as a sex chromosome in a male. Thus, the gene may be on part of

the X which has no homologue on the Y. In either case, the gene will have no allele and will, therefore, express its effect, even if it is a recessive allele.

Heterochromia hides - different colors of the iris.

Heterozygote - one who possesses two different alleles of a gene at a particular locus on a pair of homologous chromosomes.

Heterozygous - Possessing two different alleles of a particular gene on a pair of homologous chromosomes.

Hirsutism - excessive facial or body hair.

Homologous chromosomes — all the chromosomes of a diploid set (except the sex chromosomes in a male) can be paired off into corresponding or homologous pairs. In humans there are 22 pairs of homologous autosomes, plus the sex chromosome pair.

Homozygote — one who possesses identical alleles of a gene particular locus on two homologous chromosomes.

Homozygous - Possessing identical alleles of a particular gene on a pair of homologous chromosomes.

Hydantoin - drug used in the treatment of epilepsy; commonly referred to by its trade name, Dilantin.

Hyper cholesterolemia - increased levels of cholesterol in blood.

Hyperplasia - increase in the size or bulk of a body tissue as a result of an increase in cell number.

Hypertelorism - increased distance between the eyes.

Hypertrophy - overgrowth of tissue or body organ usually due to an increase in cell size but not in number.

Hypopondia - less than the expected number of teeth.

Hypogonadism - decreased gonadal function usually manifesting as deficient gonadal hormone production.

Hypoplasia - incomplete or underdevelopment of a tissue or organ.

Hypospadias - defect of the wall of the urethra, such that the urethral opening is on the underside of the penis

Identical twins - monozygotic or one-egg twins.

Inborn error of metabolism - a genetical defect that block, diverts, or otherwise alters metabolic processes, often with pathological consequences for the individual.

Inbreeding - mating between relatives, especially applied to mating between first or second cousins.

Incudomalleal fusion — a deformity in which the incudomalleolar joint is fused by bone; one of the most common of congenital middle ear anomalies.

Inguinal hernia — protrusion of intestine through the abdominal wall in the groin area.

Inversion - a reversal of the usual gene order along part of a chromosome, following breakage and reunion of non corresponding ends after 180 degree rotation of the internal broken segment.

Karyotype - the chromosomes of an individual systematically arranged from photomicrographs of a single cell's nucleus. Kyphoscoliosis - a convex backward curvature of the spine in association with silicosis.

Labyrinthitis - inflammation of the labyrinth of the inner ear (i.e., the cochlea, vestibule, or semicircular canal).

Lethal genes - alleles that cause early death of affected individual, at the stage of embryo, fetus, or infant. Such genes can never be passed on to offspring, unless they occasionally fail to penetrate. Most cases with a lethal dominant trait are therefore, due to mutation.

Linkage - if two genetic loci are on the same chromosome, they are said to be linked.

Locus - the precise position of a particular gene on a chromosome. Different forms of the gene (alleles) are found at the same position (locus) on homologous chromosomes.

Lyon hypothesis (inactive - X, phenomenon) - the genetic inactivation of all X chromosomes in excess of one, on random basis in all cells at an early stage of embryogenesis.

Lymphedema - swelling caused by the accumulation of lymph, the clear fluid present in tissues throughout the body.

Macroorchidism - abnormal enlargement of testes.

Mandibular ramus - the upturned perpendicular extremity on the lateral side of the mandible.

Mastoiditis - inflammation of mastoid sinus.

Maxilla - upper bone of the jaw.

Meiosis - a special form of nuclear division which occurs during the formation of gametes (spermatozoa and ova) in sexually reproducing organisms. Two consecutive cell divisions, the first and second meiotic divisions, occur but only one division of the chromosomes occurs; thus the number of chromosomes is reduced from the diploid (46) to the haploid (23) number. During meiosis, pairing of homologous chromosomes takes place, followed by chromosomal breakage and crossing over.

Mesodermal - those parts of the body derived from the middle of the three primary germ layers of an embryo (e.g., skeleton, muscles).

Micrognathia - underdevelopment of the chin.

Microphthalmia - Abnormally small size of one or both eyes.

Microsomia - smallness of the body.

Microtia - small or underdeveloped ears.

Mitosis - a form of nuclear division in which each chromosome splits lengthwise (it replicates itself), one chromatid of each chromosome passing to one daughter cell and the other chromatid to the second daughter cell. Thus each daughter cell receives the full complement of 46 chromosomes. This type of cell division is characteristic of somatic cells and germ cells before the onset of meiosis.

Monogenic (monomeric) inheritance - inheritance of a trait that is governed by a single genetic locus.

Monosomy - the presence in an otherwise diploid complement of only one member of a particular chromosomal pair ($2n-1$).

Monozygotic twins - twins resulting from the division into two embryos of a single zygote, following fertilization of a single ovum by a single spermatozoon (synonym : identical or one-egg twins).

Mosaic — an organism that displays genotypic or phenotypic variation from cell to cell within the same tissue or genotypic variation between tissues. At least two cell lines differing in genotype or karyotype are present.

Modifiers - factors that affect the expression of a gene. Modifiers may be other genes or they may be environmental factors.

Mutagen - any agent that may induce mutation (or increase the rate of mutation).

Mutant - a changed or mutated allele or gene; or an individual bearing such a mutant allele

Mutation - A change of gene from one allelic form to another. Mutations are important source of hereditary diversity. The term also is used generally to include chromosomal aberration.

Nephritis — inflammation of kidneys.

Neurofibroma - a benign neoplasm derived from nerve fibers.

Nevus - an area of discolored skin that is due either to hypopigmentation or hyperplasia of blood vessels.

Nondisjunction — an abnormality of nuclear division in which a pair of newly divided chromosomes fail to disjoin or to separate to opposite poles of the division spindle and instead both pass together to one pole. The resulting daughter cells thus contain unequal number of chromosomes. Nondisjunction explains the origin of many of the numerical variations of human chromosomes. If all the cells of an individual agree in showing the same abnormal number, nondisjunction must have occurred either during the early mitotic division of the 2ygote followed by selection of one aneuploid line, or during meiosis in one of the parental germ cells.

Oligodactyly - the presence of fewer than five digits on any one extremity.

Organomegaly - enlargement of the liver or spleen.

Otoadmittance - also known as immitance. A procedure used to assess the status of the external and middle ear. The tests performed typically include: tympanometry, a measure of static compliance, the determination of the acoustic muscle reflex decay.

Palpebral fissures - the slits of the eye formed by the upper and lower eyelids.

Parotid gland - the salivary gland anterior to the ear.

Patent ductus arteriosus (PDA)- failure of the ductus arteriosus is a small blood vessel connecting the pulmonary artery to the aorta in fetal life. Following birth physiological factors cause this connection to constrict Failure to constrict allows some of the blood to bypass the pulmonary circulation and thus, be under oxygenated.

Pedigree - diagram of a family tree, showing the occurrence of one or more traits in different members of a family. The analysis of patterns of heredity is facilitated by the study of pedigrees.

Penetrance - when a gene (or an allelic pair) shows an effect in the phenotype, it is said to penetrate. The penetrance of gene is the number of individuals showing the phenotypic trait expressed as a percentage of all those possessing the gene. When a dominant gene fails to produce any effect in an individual — i.e. its expressivity is nil - there is said to be a failure of penetrance ; the gene has "skipped a generation". Failure of penetrance is thus the extreme degree of reduced expressivity of a gene. A dominant gene that fails to penetrate from time to time is an irregular dominant.

Periventricular calcification - usually seen as tiny nodules in the brain substance closed to ventricular system, commonly-as a secondary consequence of congenital infections such as cytomegalovirus or toxoplasmosis.

Pharyngeal flap - surgical procedure to aid and achieving velopharyngeal closure; a flap of skin used to close most of the opening between velum and nasopharynx.

Phenocopy - an environmentally produced change in the phenotype which mimics a genetically determined trait.

Phenotype - the sum total of all observable features of a developing or developed individual (including anatomical physiological, biochemical and psychological make up and disease reaction, potential or actual). The phenotype is the result of

interaction between the genotype and the environment. This term also apply to the trait produced by single gene or several genes.

Phocomelia - abnormal development of the limbs such that they appear short and close to the body.

Plasmapheresis - an experimental procedure where plasma is separated from the cellular portion being returned. This effectively removes plasma proteins from a parent.

Pleiotropism - the production of multiple phenotypic effects by a single gene. Some cases of apparent pleiotropism may be due to a single gene operating early in embryonic development so that many later processes are indirectly effected.

Point mutation - change of a gene at single locus (in contrast with chromosomal aberrations such as deletions and translocations.)

Polydactyfy - extra fingers or toes.

Polygenic inheritance - inheritance of a trait governed by many genes which are called polygenes or multiple factors. Each of these gene may act independently and their total effect is cumulative. Height and weight and other dimensions of the body are determined in part by polygenic inheritance (quantitative inheritance).

Polymorphism - genetic polymorphism refers to the coexistence of two or more alleles in a population in frequencies too high to be explained by new mutations (e.g., the coexistence of the different blood groups or hemoglobin types in human population.)

Polyneuritis - inflammation of multiple nerves.

Polyploidy - the occurrence of an abnormal number of chromosomes which is an exact multiple of the haploid number. Polyploids may be triploid, tetraploid, pentaploid, hexaploid etc., these forms being simply expressed as $3n$, $4n$, $5n$, $6n$ etc.

Prenatal diagnosis - determination of the karyotype or phenotype (or sex) of a fetus, usually prior to 20 weeks of gestation. A variety of techniques, especially amniocentesis and cell culture, is employed.

Proband - an affected individual through whom a family is first brought to the attention of the investigator. The propositus (a) is usually indicated on a pedigree by an arrow.

Propositus (a) - an affected individual through whom a family is first brought to the attention of the investigator. The propositus (a) is usually indicated on a pedigree by an arrow.

Ptosis - droopiness of the upper eyelid.

Q - T interval - an electrocardiographic term used to denote the distance between the QRS complex and the T - wave. This measurement reflects the electrical activity of the heart.

Recessive gene - a gene that is unable to express its effect when it is present in heterozygous state (single dose) as it is dominated by its dominant allele; a recessive gene must be present in homozygous state (double dose) to express its effect. Refined methods of analysis have shown that many genes formerly thought to be completely recessive do in fact produce a slight in the heterozygote i.e. they are incompletely recessive.

Renal dysplasia - abnormal development of kidney or urinary tract.

Retinitis pigmentosa - a hereditary condition of the retina characterized by inflammation of pigmentary infiltration of the retina.

RNA (Ribose nucleic acid) - this form of nucleic acid is found in the cytoplasm and to a small extent in the chromosome. It differs both in its sugar components and in its nitrogenous bases from DNA. RNA is essential for the synthesis of proteins and acts as an intermediary, handing on genetic information to the sequence of aminoacids in proteins.

Scheibe aplasia - this most common form of inner ear aplasia is characterized by exclusive involvement of the membranous portion of cochlea. Specific features include atrophy of the stria vascularis, a rolling up of the tectorial membrane, and degeneration of the organ of Corti.

Sclera - the white of the eye.

Sexchromatin - a chromatin mass in the nucleus of interphase and early prophase cells of most mammalian species, including humans. It represents a single X chromosome which is relatively inactive in the metabolism of the cell. Females normally have sex chromatin, and thus are sex chromatin positive; males lack it, and thus are sex chromatin negative, (synonyms : Barr body, X-body.)

Sex chromosomes - the chromosomes that govern primary sex determination, In the human being, these are XX in female individuals. The distribution of these sex chromosomes governs the distribution of offspring: those who in the normal course of events receive a Y from their father and an X from their mother become males those who receive both an X from both father and mother become females. Errors may occur in the distribution of sex chromosomes to the offspring, resulting in a variety of sexual abnormalities.

Sex determination - the determination of the genetic sex of an individual by the type of sex chromosome present.

Sex differentiation - the embryological development of the features of a particular sex.

Sex limited - when the expression of a trait is restricted to one sex or markedly reduced in the other.

Sexlinkage - a form of linkage in which the gene is situated on the X or the Y chromosome. If the gene is on the non homologous part of the Y, holandric or male- to- male inheritance results; if the gene is on the homologous part of the X or the Y, incomplete or partial sex linkage results. If the gene is on the

nonhomologous part of the X, complete X linkage results; such a gene will be passed from a heterozygous mother to half of her daughters and half of her sons, and from a father only to his daughters (to whom he gives his X chromosome).

Sibs (siblings) - brothers and sisters of the same family.

Sibship - a group of children resulting from the union of the same two parents.

Somatic cells - all the body cells except the sex cells.

Somatic mutation - occurrence of a mutation in a somatic cell; it may produce mosaic effects in the mutant individual, but it will not be transmitted to progeny.

Spondylitis— inflammation of the vertebral bodies.

Stenosis - a narrowing of a canal or opening (e.g.; cardiac valves).

Strabismus - squinting or deviation of the eyes from a parallel axis.

Synchondrosis - a joining of two bones by cartilaginous material.

Syncope - fainting.

Syndactyly - persistent soft tissue between the fingers and toes, giving the impression of webbing.

Trait - a characteristic manifested in the phenotype of an individual.

Translocation - the transfer of a segment of one chromosome to another. The translocation is reciprocal when there is mutual exchange of part of a chromosome arm with that of another homologous or non-homologous chromosome resulting from their breakage and subsequent reunion. The exchanged segments may be equal or unequal in size.

Trisomy - the addition to an otherwise normal diploid complement of a member of a particular chromosome pair ($2n + 1$).

Tympanogram - a graph depicting the compliance of the tympanic membrane as a function of changes in the amount of air pressure applied to the (sealed) external auditory meatus. In clinical settings the following classification scheme is used to describe the most common tympanometric shapes.

Tympanosclerosis - the result of a deposit of calcium on the tympanic membrane.

Ventricular septal defect (VSD) - failure of complete development of the intraventricular septum. Abnormal shunting of blood can occur as a result.

Vitiligo - pale patches of skin due to loss of pigment.

X Chromosome - a sex chromosome that normally occurs singly in the male, but in duplicate in the female. The X comprises a non homologous segment and probably a homologous segment corresponding with part of the Y.

X linkage - linkage due to the presence of a gene on the X chromosome; the term is applied especially to gene on the nonhomologous segment of the X chromosome or to traits dependant on such genes for their expression.

Y chromosome - a sex chromosome that normally occurs singly in the male, but is totally lacking in the Karyotype of the female. The Y comprises of non homologous segment and probably a homologous segment corresponding with part of the X.

Zygoma - the facial bones in the area of the temple.

Zygotity - the number of zygotes from which a set of twins or higher multiple births has resulted.

Zygote - a cell formed by the fusion of male and female gametes; a fertilized egg.