

## CONTENTS

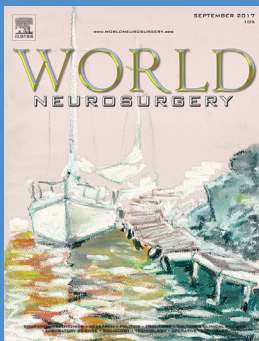
XVII–XVIII **UPCOMING EVENTS:** *Max Jägersberg*

### EDITOR'S LETTER

XX Calling: *Ed Benzel*

### LETTERS TO THE EDITOR

- 1001 Rosette-Forming Glioneuronal Tumor Arising from the Spinal Cord: *Saurabh Sharma*
- 1002 Predicting Shape, Location, and Course of Facial Nerve in Relation to Large Vestibular Schwannoma on Diffusion Tensor Imaging with Intraoperative Correlation: Important Surgical Adjunct: *Guru Dutta Satyarthee*
- 1003 In Reply to "Predicting Shape, Location, and Course of Facial Nerve in Relation to Large Vestibular Schwannoma on Diffusion Tensor Imaging with Intraoperative Correlation: Important Surgical Adjunct": *Yanyang Zhang and Xinguang Yu*
- 1004 — 1005 Single Stage Surgery Avoiding Cranioplasty at a Later Date Following Decompressive Hemicraniectomy: *Sudip Kumar Sengupta*
- 1006 In Reply to "Intraocular Silicone Oil Migration into the Ventricles Resembling Intraventricular Hemorrhage: Case Report and Review of the Literature": *Francisco J. Ascaso and Andrzej Grzybowski*
- 1007 Does Spinal Cord Line Influence Choice of Surgical Approach in Multilevel Cervical Spondylotic Myelopathy?: *Mohit Agrawal, Sachin Anil Borkar, Manoj Phalak, Raghav Singla, Ashok K. Mahapatra*
- 1008 In Reply to "Does Spinal Cord Line Influence Choice of Surgical Approach in Multilevel Cervical Spondylotic Myelopathy?": *Guang-Heng Xiang*
- 1009 — 1010 Small Stories: In Defense of the Humble Case Report: *Christopher S. Graffeo, Avital Perry, Lucas P. Carlstrom, William R. Copeland III, Kathryn M. Van Abel, Michael J. Link*
- 1011 In Reply to "Small Stories: In Defense of the Humble Case Report": *Hussam Abou-Al-Shaar and Abdulrahman J. Sabbagh*
- 1012 — 1014 A Neurosurgical Stratagem: Doing the Same with Less?: *Nicola Alberio, Rosario Maugeri, Roberto Giuseppe Giannelis, Domenico Gerardo Iacopino, Salvatore Cicero, Natale Francaviglia, Roberto Battaglia*
- 1015 — 1017 In Reply to "A Neurosurgical Stratagem: Doing the Same with Less?": *Yuanzheng Hou, Lichao Ma, Ruyuan Zhu, Xiaolei Chen*
- 1018 Letter to the Editor Regarding "Prophylactic Antiepileptic Drug Use in Patients with Brain Tumors Undergoing Craniotomy": *Pietro Ivo D'Urso and Ismail Ughratdar*
- 1019 In Reply to the Letter to the Editor Regarding "Prophylactic Antiepileptic Drug Use in Patients with Brain Tumors Undergoing Craniotomy": *Dennis T. Lockney, Paul Kubilis, Maryam Rahman*
- 1020 Letter to the Editor Regarding "Effects of Oral Glibenclamide on Brain Contusion Volume and Functional Outcome of Patients with Moderate and Severe Traumatic Brain Injuries: A Randomized Double-Blind Placebo-Controlled Clinical Trial": *Kanwaljeet Garg and Preet Mohinder Singh*



#### ON THE COVER

Mehmet Zileli, M.D. "Göcek boats, oil pastel. Göcek, on the shores of South West Turkey has unique opportunities for boat lovers with conjugation of deep blue waters and forests typical for Aegean area."

*Continued on page II*

*Continued from page I*

- 1021 In Reply to the Letter to the Editor Regarding “Effects of Oral Glibenclamide on Brain Contusion Volume and Functional Outcome of Patients with Moderate and Severe Traumatic Brain Injuries: A Randomized Double-Blind Placebo-Controlled Clinical Trial”: *Hosseinali Khalili, Nima Derakhshan, Fariborz Ghaffarpasand, Seyed Taghi Heydari*
- 1022 Letter to the Editor Regarding “Safety and Efficacy of Noncompliant Balloon Angioplasty for the Treatment of Subarachnoid Hemorrhage—Induced Vasospasm: A Multicenter Study”: *Zhong Yao and Chao You*
- 1023 In Reply to the Letter to the Editor Regarding “Safety and Efficacy of Noncompliant Balloon Angioplasty for the Treatment of Subarachnoid Hemorrhage-Induced Vasospasm: A Multicenter Study”: *Christoph J. Griessenauer, Apar S. Patel, Raghav Gupta, Nimer Adeeb, Paul M. Foreman, Hussain Shallwani, Justin M. Moore, Mark R. Harrigan, Adnan H. Siddiqui, Christopher S. Ogilvy, Ajith J. Thomas*
- 1024 — 1025 In Reply to “Indication of Surgical Management of Vestibular Schwannoma in the Older Age Group: Mysteries Still Unsolved”: *Christian A. Bowers, Richard K. Gurgel, Joel D. MacDonald*
- 1026 Postoperative Depression Following Spinal Fusion Surgery; Is There a Role for Elevated Serum Levels of Cobalt and Chromium?: *Nima Derakhshan*
- 1027 In Reply to “Postoperative Depression Following Spinal Fusion Surgery; Is There a Role for Elevated Serum Levels of Cobalt and Chromium?": *Tarek R. Mansour, Ahmed Alnemari, Brianna Krafcik, Daniel Gaudin*

**NEWS:** *Edited by Christopher Kellner*

- 980 — 982 Bionic-Brain: Controlling a Prosthetic Hand: *Rahul Jandial and Reid Hoshide*
- 983 — 984 Traumatic Brain Injury and Mood Stabilizers: Recent Cumulative Evidence: *Leonardo C. Welling, Mariana S. Welling, Eberval G. Figueiredo*

**BOOK REVIEWS:** *Edited by William J. Mack*

- 27 The Prefrontal Cortex, Fifth Edition: *Sameer A. Sheth*
- 176 Neuroimaging Parts 1 and 2 (Handbook of Clinical Neurology), edited by: *Wende N. Gibbs*
- 420 — 421 Goodman’s Neurosurgery Oral Board Review: *J. Bradley Elder*

**PERSPECTIVES**

- 985 — 987 Therapeutic Options for Recurrent High-Grade Gliomas: A Perspective Statement: *Christoph Schwartz, Niklas Thon, Peter A. Winkler*
- 988 — 989 Is There a Formula for Residency Selection of Future Academic Neurosurgeons?: *Edie E. Zusman, Robert M. Friedlander, Jonathan A. Forbes*
- 990 — 992 Predatory Publishing and Academic Integrity: *David F. Jimenez and David N. Garza*
- 993 — 996 Publication Metrics in Neurosurgery: *Vikram C. Prabhu, Kevin Swong, Gail Hendler*
- 997 — 1000 The Healthcare Landscape: Are Doctors Agents of Change or Impediments to Change?: *Russell J. Andrews and Nigel Crisp*

**ORIGINAL ARTICLES**

- 7 — 13 Analysis of Factors Related to Hypopituitarism in Patients with Nonsellar Intracranial Tumor: *Song-Song Lu, Jian-Jun Gu, Xiao-Hong Luo, Jian-He Zhang, Shou-Sen Wang*

- 14 — 19 Intraoperative Mapping and Monitoring of the Pyramidal Tract Using Endoscopic Depth Electrodes: *Yukinori Akiyama, Shunya Ohtaki, Katsuya Komatsu, Kentaro Toyama, Rei Enatsu, Takeshi Mikami, Masahiko Wanibuchi, Nobuhiro Mikuni*
- 28 — 36 DNA Methylation Regulates Gene Expression in Intracranial Aneurysms: *Langbing Yu, Jia Wang, Shuo Wang, Dong Zhang, Yuanli Zhao, Rong Wang, Jizong Zhao*
- 37 — 46 Predictive Factors of Postoperative Seizure for Pediatric Patients with Unruptured Arteriovenous Malformations: *Haibo Yang, Zhenghai Deng, Wuyang Yang, Kai Liu, Hongxin Yao, Xianzeng Tong, Jun Wu, Yuanli Zhao, Yong Cao, Shuo Wang*
- 47 — 52 Chronic Subdural Hematoma in Women: *Kazuko Hotta, Takatoshi Sorimachi, Yumie Honda, Mitsunori Matsumae*
- 63 — 68 Risk Factors for Ventriculoperitoneal Shunt Dependency in Patients with Spontaneous Cerebellar Hemorrhage: *Shih-Yuan Hsu, Hsin-Huan Chang, Fu-Yuan Shih, Yu-Jun Lin, Wei-Che Lin, Ben-Chung Cheng, Yu-Jih Su, Chia-Te Kung, Yu-Ni Ho, Nai-Wen Tsai, Cheng-Hsien Lu, Hung-Chen Wang*
- 69 — 77 Risk Factors for Surgical Results of Hirayama Disease: A Retrospective Analysis of a Large Cohort: *Jian Song, Hong-Li Wang, Chao-Jun Zheng, Jian-Yuan Jiang*
- 78 — 85 Incidence and Risk Factors of Postoperative Adjacent Segment Degeneration Following Anterior Decompression and Instrumented Fusion for Degenerative Disorders of the Cervical Spine: *Hui Wang, Lei Ma, Dalong Yang, Sidong Yang, Wenyuan Ding*
- 86 — 94 Evaluation of Screw Placement Accuracy in Circumferential Lumbar Arthrodesis Using Robotic Assistance and Intraoperative Flat-Panel Computed Tomography: *Louis Chenin, Cyrille Capel, Anthony Fichten, Johann Peltier, Michel Lefranc*
- 95 — 101 A Meta-Analysis on the Clinical Significance of Redundant Nerve Roots in Symptomatic Lumbar Spinal Stenosis: *Lin Cong, Yue Zhu, Qi Yan, GuanJun Tu*
- 102 — 107 Safety of Percutaneous Dilatational Tracheostomy in Patients with Acute Brain Injury and Reduced PaO<sub>2</sub>/FiO<sub>2</sub> Ratio—Retrospective Analysis of 54 Patients: *Claudia Ditz, Jann F. Wojak, Emma Smith, Abdulkareem Abusamha, Volker M. Tronnier, Jan Gliemroth, Jan N. Küchler*
- 108 — 114 Respiratory and Swallowing Outcomes Based on Aneurysm Location in 360 Patients with Subarachnoid Hemorrhage: *Isaac Josh Abecassis, Ryan P. Morton, Lynn McGrath, Josiah Hanson, Anna H. Xue, Cory M. Kelly, Michael R. Levitt, Laligam N. Sekhar, Louis J. Kim*
- 115 — 121 Effects of Dexamethasone in the Treatment of Recurrent Chronic Subdural Hematoma: *Yu Zhang, Shiping Chen, Yangchun Xiao, Wenhua Tang*
- 137 — 144 Requirements for a Stable Long-Term Result in Surgical Reduction of Vertebral Fragility Fractures: *Jesús Crespo-Sanjuán, Francisco Ardura, Rubén Hernández-Ramajo, David C. Noriega*
- 153 — 162 Vitom-3D for Exoscopic Neurosurgery: Initial Experience in Cranial and Spinal Procedures: *Joachim M. Oertel and Benedikt W. Burkhardt*
- 163 — 169 Endoscopic Third Ventriculostomy for the Treatment of Hydrocephalus in a Pediatric Population with Myelomeningocele: *Joana Rei, Josué Pereira, Carina Reis, Sérgio Salvador, Rui Vaz*
- 177 — 183 Intraprocedural Rupture of Unruptured Cerebral Aneurysms During Coil Embolization: A Single-Center Experience: *Su Hee Cho, Mohammed Denewer, Wonhyoung Park, Jae Sung Ahn, Byung Duk Kwun, Deok Hee Lee, Jung Cheol Park*
- 184 — 190 Outcome Evaluation of Patients with Limited Brain Metastasis From Malignant Melanoma, Treated with Surgery, Radiation Therapy, and Targeted Therapy: *Federico Pessina, Pierina Navarria, Stefano Tomatis, Luca Cozzi, Ciro Franzese, Lorenza Di Guardo, Anna Maria Ascolese, Giacomo Reggiori, Davide Franceschini, Michele Del Vecchio, Lorenzo Bello, Marta Scorsetti*

*Continued on page IV*

*Continued from page III*

- 199 – 205 **Conservative and Surgical Treatment of Patients with Pineal Cysts: Prospective Case Series of 110 Patients:** *Martin Májovský, David Netuka, Vladimír Beneš*
- 206 – 212 **Comparison of Stent-Assisted Coil Embolization and the Pipeline Embolization Device for Endovascular Treatment of Ophthalmic Segment Aneurysms: A Multicenter Cohort Study:** *Nimer Adeeb, Christoph J. Griessenauer, Paul M. Foreman, Justin M. Moore, Rouzbeh Motiei-Langroudi, Michelle H. Chua, Raghav Gupta, Apar S. Patel, Mark R. Harrigan, Abdulrahman Y. Alturki, Christopher S. Ogilvy, Ajith J. Thomas*
- 213 – 222 **Clinical and Radiologic Outcomes After Fenestration and Partial Wall Excision of Idiopathic Intradural Spinal Arachnoid Cysts Presenting with Myelopathy:** *Vibhu K. Viswanathan, Sakthivel R. Manoharan, Hyunwoo Do, Amy Minnema, Sophia M. Shaddy, J. Brad Elder, H. Francis Farhadi*
- 223 – 231 **Two-Dimensional High Definition Versus Three-Dimensional Endoscopy in Endonasal Skull Base Surgery: A Comparative Preclinical Study:** *Vittorio Rampinelli, Francesco Doglietto, Davide Mattavelli, Jimmy Qiu, Elena Raffetti, Alberto Schreiber, Andrea Bolzoni Villaret, Walter Kucharczyk, Francesco Donato, Marco Maria Fontanella, Piero Nicolai*
- 232 – 237 **Pipeline Embolization Device in Treatment of 50 Unruptured Large and Giant Aneurysms:** *Nimer Adeeb, Christoph J. Griessenauer, Hussain Shallwani, Hakeem Shakir, Paul M. Foreman, Justin M. Moore, Adam A. Dmytriv, Raghav Gupta, Adnan H. Siddiqui, Elad I. Levy, Kenneth Snyder, Mark R. Harrigan, Christopher S. Ogilvy, Ajith J. Thomas*
- 238 – 248 **Severe Traumatic Brain Injury at a Tertiary Referral Center in Tanzania: Epidemiology and Adherence to Brain Trauma Foundation Guidelines:** *Luke R. Smart, Halinder S. Mangat, Benson Issarow, Paul McClelland, Gerald Mayaya, Emmanuel Kanumba, Linda M. Gerber, Xian Wu, Robert N. Peck, Isidore Ngayomela, Malik Fakhar, Philip E. Stieg, Roger Härtl*
- 249 – 256 **Anterior Column Realignment has Similar Results to Pedicle Subtraction Osteotomy in Treating Adults with Sagittal Plane Deformity:** *Gregory M. Mundis Jr., Jay D. Turner, Nima Kabirian, Jeff Pawelek, Robert K. Eastlack, Juan Uribe, Eric Klineberg, Shay Bess, Chris Ames, Vedat Deviren, Stacie Nguyen, Virginie Lafage, Behrooz A. Akbarinia, International Spine Study Group*
- 265 – 269 **Complicated Mild Traumatic Brain Injury and the Need for Imaging Surveillance:** *Martina Stippler, Jingyi Liu, Rouzbeh Motiei-Langroudi, Zoya Voronovich, Howard Yonas, Roger B. Davis*
- 270 – 281 **What Factors Determine Treatment Outcome in Aneurysmal Subarachnoid Hemorrhage in the Modern Era? A Post Hoc STASH Analysis:** *Mario Teo, Mathew R. Guilfoyle, Carole Turner, Peter J. Kirkpatrick, for the STASH Collaborators*
- 282 – 288 **High Expression of Glypican-1 Predicts Dissemination and Poor Prognosis in Glioblastomas:** *Taiichi Saito, Kazuhiko Sugiyama, Seiji Hama, Fumiyuki Yamasaki, Takeshi Takayasu, Ryo Nosaka, Shumpei Onishi, Yoshihiro Muragaki, Takakazu Kawamata, Kaoru Kurisu*
- 289 – 293 **Classification of Meningiomas Based on Their Surgical Removal, World Health Organization Grade, and Cytogenetic Profile: A Treatment Algorithm:** *Carlos Eduardo da Silva and Paulo Eduardo Peixoto de Freitas*
- 294 – 301 **Radiolucent Carbon Fiber—Reinforced Pedicle Screws for Treatment of Spinal Tumors: Advantages for Radiation Planning and Follow-Up Imaging:** *Florian Ringel, Yu-Mi Ryang, Jan S. Kirschke, Birgit S. Müller, Jan J. Wilkens, Jeremy Brodard, Stephanie E. Combs, Bernhard Meyer*
- 314 – 320 **Prognostic Value of Preoperative Nurick Grade and Time with Symptoms in Patients with Cervical Myelopathy and Gait Impairment:** *Rafael De la Garza-Ramos, Seba Ramhmdani, Thomas Kosztowski, Risheng Xu, Reza Yassari, Timothy F. Witham, Ali Bydon*

- 321 — 326 Potential of New-Generation Double-Layer Micromesh Stent for Carotid Artery Stenting in Patients with Unstable Plaque: A Preliminary Result Using OFDI Analysis: *Kiyofumi Yamada, Shinichi Yoshimura, Masatomo Miura, Takuya Kanamaru, Seigo Shindo, Kazutaka Uchida, Manabu Shirakawa, Masahiko Shibuya, Takahiro Imanaka, Masaharu Ishihara, Tohru Masuyama, Reiichi Ishikura, Masanori Kawasaki*
- 327 — 331 Prognostic Factors for Recovery of Patients After Surgery for Thoracic Spinal Tuberculosis: *Yuan Yao, Huiyu Zhang, Minghan Liu, Huan Liu, Tongwei Chu, Yu Tang, Yue Zhou*
- 332 — 340 Surgical Evacuation of Spontaneous Supratentorial Lobar Intracerebral Hemorrhage: Comparison of Safety and Efficacy of Stereotactic Aspiration, Endoscopic Surgery, and Craniotomy: *Yuqian Li, Ruixin Yang, Zhihong Li, Yanping Yang, Bo Tian, Xingye Zhang, Bao Wang, Dan Lu, Shaochun Guo, Minghao Man, Yang Yang, Tao Luo, Guodong Gao, Lihong Li*
- 341 — 347 The Neurosurgery Match: A Bibliometric Analysis of 206 First-Year Residents: *Ahmed Kashkoush, Arpan V. Prabhu, Daniel Tonetti, Nitin Agarwal*
- 348 — 358 Minimally Invasive Surgery for Patients with Hypertensive Intracerebral Hemorrhage with Large Hematoma Volume: A Retrospective Study: *Weijun Wang, Ningquan Zhou, Chao Wang*
- 359 — 368 Preserving the Facial Nerve During Orbitozygomatic Craniotomy: Surgical Anatomy Assessment and Stepwise Illustration: *Ali Tayebi Meybodi, Michael T. Lawton, Sonia Yousef, J.J.González Sánchez, Armau Benet*
- 375 — 385 Intraoperative Scoring System to Predict Postoperative Remission in Endoscopic Endonasal Transsphenoidal Surgery for Growth Hormone—Secreting Pituitary Adenomas: *Shigetoshi Yano, Naoki Shinjima, Junji Kawashima, Tatsuya Kondo, Takuichiro Hide*
- 394 — 398 YouTube as a Source of Information on Neurosurgery: *Nardin Samuel, Naif M. Alotaibi, Andres M. Lozano*
- 399 — 405 Sphenopterional Point: Strategic Point for Burr Hole Placement in Frontotemporal Craniotomies: *Baltazar Leão Reis, Roberto Leal Da Silveira, Sebastião Nataniel Silva Gusmão*
- 406 — 411 Fluorescein Angiography in Intracranial Aneurysm Surgery: A Helpful Method to Evaluate the Security of Clipping and Observe Blood Flow: *Cristian Kakucs, Ioan-Alexandru Florian, Gheorghe Ungureanu, Ioan-Stefan Florian*
- 412 — 419 Comparison of Operative Time with Conventional Fluoroscopy Versus Spinal Neuronavigation in Instrumented Spinal Tumor Surgery: *James A. Miller and Andrew J. Fabiano*
- 422 — 431 Factors Affecting the Visual Outcome of Pituitary Adenoma Patients Treated with Endoscopic Transsphenoidal Surgery: *Tuomas Luomaranta, Antti Raappana, Ville Saarela, M. Johanna Linnamaa*
- 432 — 440 Brain Arteriovenous Malformations Located in Premotor Cortex: Surgical Outcomes and Risk Factors for Postoperative Neurologic Deficits: *Yuming Jiao, Fuxin Lin, Jun Wu, Hao Li, Xin Chen, Zhicen Li, Ji Ma, Yong Cao, Shuo Wang, Jizong Zhao*
- 441 — 455 Anterior Transthoracic Surgery with Motor Evoked Potential Monitoring for High-Risk Thoracic Disc Herniations: Technique and Results: *Erwin Cornips, Jeroen Habets, Vivianne van Kranen-Mastenbroek, Herman Bos, Paul Bergs, Alida Postma*
- 456 — 461 The Timed Up and Go Test as a Diagnostic Criterion in Normal Pressure Hydrocephalus: *Gabriel André Silva Mendes, Matheus Fernandes de Oliveira, Fernando Campos Gomes Pinto*
- 462 — 469 One-Year Mortality of Patients with Chronic Kidney Disease After Spinal Cord Injury: A 14-Year Population-Based Study: *Shou-Chun Yu, Jinn-Rung Kuo, Yow-Ling Shiue, Zong-Xing Yu, Chung-Han Ho, Chia-Chun Wu, Jhi-Joung Wang, Chin-Chen Chu, Sher-Wei Lim*
- 470 — 477 Results of Early High-Flow Bypass and Trapping for Ruptured Blood Blister-Like Aneurysms of the Internal Carotid Artery: *Yuichiro Kikkawa, Toshiki Ikeda, Ririko Takeda, Hiroyuki Nakajima, Takeshi Ogura, Hidetoshi Ooigawa, Hiroki Kurita*

Continued on page VI

*Continued from page V*

- 478 — 491 **Brain Arteriovenous Malformations Located in Language Area: Surgical Outcomes and Risk Factors for Postoperative Language Deficits:** *Yuming Jiao, Fuxin Lin, Jun Wu, Hao Li, Xin Chen, Zhicen Li, Ji Ma, Yong Cao, Shuo Wang, Jizong Zhao*
- 492 — 497 **Irreversible Total Loss of Brain Function and Organ Donation in Patients with Aneurysmal Subarachnoid Hemorrhage:** *Malte Mohme, Thomas Sauvigny, Jörn Grensemann, Gerold Söffker, Stefan Kluge, Manfred Westphal, Patrick Czorlich*
- 498 — 502 **The Impact of Kidney Disease on Acute Tubular Necrosis and Surgical Site Infection After Lumbar Fusion:** *Jonathan Nakhla, Rafael de la Garza Ramos, Niketh Bhashyam, Andrew Kobets, Rani Nasser, Murray Echt, Gernot Lang, Rodrigo Navarro-Ramirez, Ajit Jada, Merritt Kinon, Reza Yassari*
- 503 — 509 **Impact of Elderly Age on Complications and Clinical Outcomes Following Anterior Lumbar Interbody Fusion Surgery:** *Kevin Phan, Vignesh Ramachandran, Tommy Tran, Steven Phan, Prashanth J. Rao, Ralph J. Mobbs*
- 510 — 518 **The Effect of Single-Level Disc Degeneration on Dynamic Response of the Whole Lumbar Spine to Vertical Vibration:** *Li-Xin Guo and Wei Fan*
- 519 — 525 **Injury to the Lumbar Plexus and its Branches After Lateral Fusion Procedures: A Cadaver Study:** *Peter Grunert, Doniel Drazin, Joe Iwanaga, Cameron Schmidt, Fernando Alonso, Marc Moisi, Jens R. Chapman, Rod J. Oskouiian, Richard Shane Tubbs*
- 526 — 528 **Patients' Perioperative Experience of Awake Deep-Brain Stimulation for Parkinson Disease:** *Eoin Mulroy, Nigel Robertson, Lorraine Macdonald, Arnold Bok, Mark Simpson*
- 534 — 542 **Supracerebellar Infratentorial Paramedian Approach in Helsinki Neurosurgery: Cornerstones of a Safe and Effective Route to the Pineal Region:** *Joham Choque-Velasquez, Roberto Colasanti, Julio C. Resendiz-Nieves, Behnam Rezaei Jahromi, Danil A. Kozyrev, Peeraphong Thiarawat, Juha Hernesniemi*
- 543 — 548 **Volume-Outcome Relationship After 1 and 2 Level Anterior Cervical Discectomy and Fusion:** *Rafael De la Garza Ramos, Jonathan Nakhla, Rani Nasser, Ajit Jada, Niketh Bhashyam, Merritt D. Kinon, Reza Yassari*
- 549 — 556 **Structural Allograft versus Autograft for Instrumented Atlantoaxial Fusions in Pediatric Patients: Radiologic and Clinical Outcomes in Series of 32 Patients:** *Yue-Hui Zhang, Lei Shen, Jiang Shao, Dean Chou, Jia Song, Jing Zhang*
- 557 — 567 **Awake High-Flow Extracranial to Intracranial Bypass for Complex Cerebral Aneurysms: Institutional Clinical Trial Results:** *Saleem I. Abdulrauf, Jorge F. Urquiaga, Ritesh Patel, J. Andrew Albers, Sirajeddin Belkhair, Kyle Dryden, Michael Prim, Douglas Snyder, Brian Kang, Lama Mokhlis, Asad S. Akhter, Lauren N. Mackie, Abdullah Alatar, Elizabeth A. Erickson, Nanthiya Sujjantarat, Jay Shah, Trenton Wecker, George Stevens, Jodi Walsh, Abigail Schweiger, Paula Buchanan*
- 568 — 584 **Internal Maxillary Artery Bypass with Radial Artery Graft Treatment of Giant Intracranial Aneurysms:** *Long Wang, Shuaibin Lu, Hai Qian, Xiang'en Shi*
- 585 — 590 **Illumination in Spinal Surgery Depending on Different Approaches and Light Sources:** *Eike Wilbers, Christian Ewelt, Stephanie Schipmann, Walter Stummer, Mark Klingenhöfer*
- 591 — 598 **Long-Term Volume Reduction Effects of Endovascular Embolization for Intracranial Meningioma: Preliminary Experience of 5 Cases:** *Norio Nakajima, Hitoshi Fukuda, Hiromasa Adachi, Natsuhi Sasaki, Makoto Yamaguchi, Yuto Mitsuno, Masashi Kitagawa, Fumihiko Horikawa, Kenichi Murao, Keisuke Yamada*
- 599 — 604 **Occipital Nerve Stimulation for the Treatment of Refractory Occipital Neuralgia: A Case Series:** *Orion P. Keifer Jr., Ashley Diaz, Melissa Campbell, Yarema B. Bezchlibnyk, Nicholas M. Boulis*

- 605 — 611 Results of Atypical Hemifacial Spasm with Microvascular Decompression: 14 Case Reports and Literature Review: *Hua Zhao, Xin Zhang, Ying Zhang, Yin-Da Tang, Jin Zhu, Xu-Hui Wang, Ting-Ting Ying, Shi-Ting Li*
- 612 — 622 Which Approach Is Advantageous to Preventing Development of Adjacent Segment Disease? Comparative Analysis of 3 Different Lumbar Interbody Fusion Techniques (ALIF, LLIF, and PLIF) in L4-5 Spondylolisthesis: *Chul-Woo Lee, Kang-Jun Yoon, Sang-Soo Ha*
- 623 — 631 Results of Operative Treatment of Brachial Plexus Injury Resulting from Shoulder Dislocation: A Study with A Long-Term Follow-Up: *Olga Gutkowska, Jacek Martynkiewicz, Sylwia Mizia, Michał Bąk, Jerzy Gosk*
- 643 — 650 Impact of Associated Nidal Lesions in Outcome of Brain Arteriovenous Malformations After Radiosurgery with or without Embolization: *Carlos Michel A. Peres, Evandro Cesar de Souza, Manoel Jacobsen Teixeira, Eberval G. Figueiredo, Jose Guilherme M.P. Caldas*
- 651 — 658 Surgical Outcome of Growth Hormone—Secreting Pituitary Adenoma with Empty Sella Using a New Classification: *Qiang Wang, Xiaopeng Guo, Lu Gao, Zihao Wang, Kan Deng, Wei Lian, Renzhi Wang, Huijuan Zhu, Bing Xing*
- 659 — 671 Awake Surgery for Brain Vascular Malformations and Moyamoya Disease: *Rami James N. Aoun, Mithun G. Sattur, Chandan Krishna, Amen Gupta, Matthew E. Welz, Allan D. Nanney III, Antoun H. Koht, Matthew C. Tate, Katherine H. Noe, Joseph I. Sirven, Barrett J. Anderies, Patrick B. Bolton, Terry L. Trentman, Richard S. Zimmerman, Kristin R. Swanson, Bernard R. Bendok*
- 672 — 677 Association of Plasminogen Activator Inhibitor 1 (*SERPINE1*) Polymorphisms and Aneurysmal Subarachnoid Hemorrhage: *Phillip Hendrix, Paul M. Foreman, Mark R. Harrigan, Winfield S. Fisher III, Nilesh A. Vyas, Robert H. Lipsky, Minkuan Lin, Beverly C. Walters, R. Shane Tubbs, Mohammadali M. Shoja, Jean-Francois Pittet, Mali Mathru, Christoph J. Griessenauer*
- 678 — 688 Microsurgical Treatment of Colloid Cysts of the Third Ventricle: *Alexander N. Konovalov, David I. Pitskhelauri, Michael Shkarubo, Svetlana B. Buklina, Anna A. Poddubskaya, Mariya Kolycheva*
- 697 — 701 Subventricular Zone Involvement Characterized by Diffusion Tensor Imaging in Glioblastoma: *Bart R.J. van Dijken, Jiun-Lin Yan, Natalie R. Boonzaier, Chao Li, Peter Jan van Laar, Anouk van der Hoorn, Stephen J. Price*
- 702 — 708 The Histological Effects of Ozone Therapy on Sciatic Nerve Crush Injury in Rats: *Hakan Somay, Selin Tural Emon, Serap Uslu, Metin Orakdogan, Zeynep Cingu Meric, Umit Ince, Tayfun Hakan*
- 709 — 713 Increased Levels of Soluble Cluster of Differentiation 40 Ligand, Matrix Metalloproteinase 9, and Matrix Metalloproteinase 2 Are Associated with Carotid Plaque Vulnerability in Patients with Ischemic Cerebrovascular Disease: *Yipeng Han, Xiang Mao, Lijun Wang, Jiachun Liu, Daming Wang, Hongwei Cheng, Guozhuan Miao*
- 714 — 719 Presence of a Malignant Tumor as a Novel Predictive Factor for Repeated Recurrences of Chronic Subdural Hematoma: *Yusuke S. Hori, Mizuho Aoi, Kazunori Oda, Toru Fukuhara*
- 720 — 727 The Need for Clinical Practice Guidelines in Assessing and Managing Perioperative Neurologic Deficit: Results from a Survey of the AOSpine International Community: *Anick Nater, Jean-Christophe Murray, Allan R. Martin, Aria Nouri, Lindsay Tetreault, Michael G. Fehlings*
- 728 — 731 Effect of Aspirin in Postoperative Management of Adult Ischemic Moyamoya Disease: *Yahui Zhao, Qian Zhang, Dong Zhang, Yuanli Zhao*
- 732 — 736 The Effect of Morbid Obesity on Subarachnoid Hemorrhage Prognosis in the United States: *Ross-Jordon S. Elliott, Daniel Agustin Godoy, Joel E. Michalek, Réza Behrouz, Marwah A. Elsehety, Shaheryar Hafeez, Denise Rios, Ali Seifi*

Continued on page VIII

*Continued from page VII*

- 737 – 744 Management of Residual Tumor After Limited Subtotal Resection of Large Vestibular Schwannomas: Lessons Learned and Rationale for Specialized Care: *William R. Copeland, Matthew L. Carlson, Brian A. Neff, Colin L.W. Driscoll, Michael J. Link*
- 749 – 754 Emergency Reoperations in Cranial Neurosurgery: *Borys M. Kwinta, Roger M. Krzyżewski, Kornelia M. Kliś, Paulina Donicz, Małgorzata Gackowska, Jarosław Polak, Krzysztof Stachura, Marek Moskala*
- 765 – 774 Neurologic Outcome After Decompressive Craniectomy: Predictors of Outcome in Different Pathologic Conditions: *Taco Goedemans, Dagmar Verbaan, Bert A. Coert, Bertjan J. Kerklaan, René van den Berg, Jonathan M. Coutinho, Tessa van Middelaar, Paul J. Nederkoorn, William Peter Vandertop, Pepijn van den Munckhof*
- 775 – 782 Four-Dimensional Phase Contrast Magnetic Resonance Imaging Protocol Optimization Using Patient-Specific 3-Dimensional Printed Replicas for In Vivo Imaging Before and After Flow Diverter Placement: *Christof Karmonik, Jeff R. Anderson, Saba Elias, Richard Klucznik, Orlando Diaz, Yi Jonathan Zhang, Robert G. Grossman, Gavin W. Britz*
- 783 – 789 Reconstruction of Cranial Vault Defect with Polyetheretherketone Implants: *Pierre Brandicourt, Franck Delanoé, Franck-Emmanuel Roux, Florian Jalbert, David Brauge, Frédéric Lauwers*
- 790 – 795 Efficacy of Early Surgery for Neurological Improvement in Spinal Cord Injury without Radiographic Evidence of Trauma in the Elderly: *Tomoo Inoue, Shinsuke Suzuki, Toshiki Endo, Hiroshi Uenohara, Teiji Tominaga*
- 805 – 811 Endoscopic Supracerebellar Transtentorial Approach to Atrium of Lateral Ventricle: Preliminary Surgical and Optical Considerations: *Tao Xie, Linjun Zhou, Xiaobiao Zhang, Wei Sun, Hailin Ding, Tengfei Liu, Ye Gu, Chongjing Sun, Fan Hu, Wei Zhu*
- 818 – 823 Assessment of Cost Drivers in Transsphenoidal Approaches for Resection of Pituitary Tumors Using the Value-Driven Outcome Database: *Michael Karsy, Andrea A. Brock, Jian Guan, Erica F. Bisson, William T. Couldwell*
- 824 – 831 Analysis of Patients with Myelopathy due to Benign Intradural Spinal Tumors with Concomitant Lumbar Degenerative Diseases Misdiagnosed and Erroneously Treated with Lumbar Surgery: *Kang Lu, Hao-Kuang Wang, Po-Chou Liliang, Chih-Hui Yang, Cheng-Yo Yen, Yu-Duan Tsai, Po-Yuan Chen, Cien-Leong Chye, Kuo-Wei Wang, Cheng-Loong Liang, Han-Jung Chen*
- 832 – 840 Clinical Efficacy and Its Prognostic Factor of Percutaneous Endoscopic Lumbar Annuloplasty and Nucleoplasty for the Treatment of Patients with Discogenic Low Back Pain: *Jung Hwan Lee and Sang-Ho Lee*
- 841 – 848 Novel Oral Anticoagulants in Patients Undergoing Cranial Surgery:  *Davide Marco Croci, Maria Kamenova, Raphael Guzman, Luigi Mariani, Jehuda Soleman*
- 849 – 856 Long-Term Functional Outcome of Symptomatic Unruptured Intracranial Aneurysms in an Interdisciplinary Treatment Concept: *Mathias Kunz, Franziska Dorn, Tobias Greve, Veit Stoecklein, Joerg-Christian Tonn, Hartmut Brückmann, Christian Schichor*
- 857 – 863 Clinical Application of Insertion Force Sensor System for Coil Embolization of Intracranial Aneurysms: *Noriaki Matsubara, Shigeru Miyachi, Takashi Izumi, Hiroyuki Yamada, Naoki Marui, Keisuke Ota, Hayato Tajima, Kazunori Shintai, Masashi Ito, Tasuku Imai, Masahiro Nishihori, Toshihiko Wakabayashi*
- 864 – 874 Influence of Magnetic Resonance Imaging Features on Surgical Decision-Making in Degenerative Cervical Myelopathy: Results from a Global Survey of AOSpine International Members: *Aria Nouri, Allan R. Martin, Anick Nater, Christopher D. Witiv, So Kato, Lindsay Tetreault, Hamed Reihani-Kermani, Carlo Santaguida, Michael G. Fehlings*



- 875 — 883 **Robotic Transnasal Endoscopic Skull Base Surgery: Systematic Review of the Literature and Report of a Novel Prototype for a Hybrid System (Brescia Endoscope Assistant Robotic Holder):** *Andrea Bolzoni Villaret, Francesco Doglietto, Andrea Carobbio, Alberto Schreiber, Camilla Panni, Enrico Piantoni, Giovanni Guida, Marco Maria Fontanella, Piero Nicolai, Riccardo Cassinis*
- 884 — 894 **Obese (Body Mass Index >30) Patients Have Greater Functional Improvement and Reach Equivalent Outcomes at 12 Months Following Decompression Surgery for Symptomatic Lumbar Stenosis:** *Galal Elsayed, Matthew C. Davis, Esther C. Dupépe, Samuel G. McCluggage, Paul Szerlip, Beverly C. Walters, Mark N. Hadley*
- 895 — 905 **Stemness Marker Detection in the Periphery of Glioblastoma and Ability of Glioblastoma to Generate Glioma Stem Cells: Clinical Correlations:** *Soheila Raysi Dehcordi, Alessandro Ricci, Hembra Di Vitantonio, Danilo De Paulis, Sabino Luzzi, Paola Palumbo, Benedetta Cinque, Daniela Tempesta, Gino Coletti, Gianluca Cipolloni, Maria Grazia Cifone, Renato Galzio*
- 906 — 912 **Safety and Efficacy of Antibacterial Prophylaxis After Craniotomy: A Decision Model Analysis:** *Amal F. Alotaibi, Rania A. Mekary, Hasan A. Zaidi, Timothy R. Smith, Ankur Pandya*
- 913 — 922 **Functional Connectivity in Frontoparietal Network: Indicator of Preoperative Cognitive Function and Cognitive Outcome Following Surgery in Patients with Glioma:** *Stefan Lang, Ismael Gaxiola-Valdez, Michael Opoku-Darko, Lisa A. Partlo, Bradley G. Goodyear, John J.P. Kelly, Paolo Federico*
- 923 — 934 **Impact of Gradient Number and Voxel Size on Diffusion Tensor Imaging Tractography for Resective Brain Surgery:** *Friso W.A. Hoefnagels, Philip C. de Witt Hamer, Petra J.W. Pouwels, Frederik Barkhof, W. Peter Vandertop*
- 935 — 943 **Intraventricular Cavernomas of the Third Ventricle: Report of 2 Cases and a Systematic Review of the Literature:** *Vivek B. Beechar, Visish M. Srinivasan, Oleg E. Reznik, Anish Sen, Tiemo J. Klisch, Alexander E. Ropper, Jacob J. Mandel, Kent A. Heck, Timothy J. Seipel, Akash J. Patel*
- 944 — 951 **Outcome After Subarachnoid Hemorrhage from Blood Blister—Like Aneurysm Rupture Depends on Age and Aneurysm Morphology:** *Juergen Konczalla, Florian Gessler, Markus Bruder, Joachim Berkefeld, Gerhard Marquardt, Volker Seifert*
- 952 — 960 **Face, Content, and Construct Validity of an Aneurysm Clipping Model Using Human Placenta:** *Evgenii Belykh, Eric J. Miller, Ting Lei, Kristina Chapple, Vadim A. Byvaltsev, Robert F. Spetzler, Peter Nakaji, Mark C. Preul*

## DOING MORE WITH LESS

- 122 — 125 **Inside Vietnam’s Largest Neurosurgery Department:** *Constantine L. Karras, Huy Minh Tran, David Dombos III, Phong Nguyen, Shahid M. Nimjee, Daniel M. Prevedello, Ciarán J. Powers*
- 126 — 136 **Supraorbital Versus Endoscopic Endonasal Approaches for Olfactory Groove Meningiomas: A Cost-Minimization Study:** *Gurpreet S. Gandhoke, Matthew Pease, Kenneth J. Smith, Raymond F. Sekula Jr*
- 257 — 264 **Outcomes Following Exploratory Burr Holes for Traumatic Brain Injury in a Resource Poor Setting:** *Jessica Eaton, Asma Bilal Hanif, Gift Mulima, Chifundo Kajombo, Anthony Charles*

## HISTORICAL VIGNETTE

- 745 — 748 **A Cranial Trauma was the Cause of Death of Charles VIII of France (1470–1498):** *Konstantinos Markatos, Marianna Karamanou, Konstantina Arkoudi, Apostolia Konstantinidi, Georgios Androutsos*

*Continued on page X*

*Continued from page IX***LITERATURE REVIEWS**

- 1 – 6 Hypertonic Saline for Increased Intracranial Pressure After Aneurysmal Subarachnoid Hemorrhage: A Systematic Review: *Christopher R. Pasarikovski, Naif M. Alotaibi, Fawaz Al-Mufti, R. Loch Macdonald*
- 53 – 62 Management of Glioblastoma Multiforme in Elderly Patients: A Review of the Literature: *Sameer H. Halani, Ranjith Babu, D. Cory Adamson*
- 145 – 152 Intraspinal Pressure Monitoring and Extensive Duroplasty in the Acute Phase of Traumatic Spinal Cord Injury: A Systematic Review: *Tomasz Tykocki, Łukasz Poniatowski, Marcin Czyż, Michael Koziara, Guy Wynne-Jones*
- 170 – 175 Potential for Intrathecal Baclofen in Treatment of Essential Tremor: *Mousa Hamad, Ryan Holland, Naveed Kamal, Robert Luceri, Antonios Mammis*
- 191 – 198 “Asleep” Deep Brain Stimulation Surgery: A Critical Review of the Literature: *Tsinsue Chen, Zaman Mirzadeh, Francisco A. Ponce*
- 302 – 313 Intracranial Aneurysm in Patients with Sickle Cell Disease: A Systematic Review: *Zhong Yao, Jin Li, Min He, Chao You*
- 632 – 642 Role of Hemodynamic Forces in Unruptured Intracranial Aneurysms: An Overview of a Complex Scenario: *Marcello Longo, Francesca Granata, Sergio Racchiusa, Enricomaria Mormina, Giovanni Grasso, Giuseppe Maria Longo, Giada Garufi, Francesco M. Salpietro, Concetta Alafaci*
- 689 – 696 Predictors of Outcomes in Fourth Ventricular Epidermoid Cysts: A Case Report and a Review of Literature: *Lawrance K. Chung, Joel S. Beckett, Vera Ong, Carlito Lagman, Daniel T. Nagasawa, Isaac Yang, Won Kim*
- 961 – 970 Radiation-Induced Malignant Peripheral Nerve Sheath Tumors: A Systematic Review: *Ryuya Yamanaka and Azusa Hayano*

**TECHNICAL NOTES**

- 20 – 26 A Novel Approach for Percutaneous Vertebroplasty Based on Preoperative Computed Tomography—Based Three-Dimensional Model Design: *Jian Li, JiSheng Lin, JunChuan Xu, Hai Meng, Nan Su, ZiHan Fan, JinJun Li, Yong Yang, Dong Li, BingQiang Wang, Qi Fei*
- 369 – 374 An Affordable Microsurgical Training System for a Beginning Neurosurgeon: How to Realize the Self-Training Laboratory: *Sang-Bong Chung, Jiwook Ryu, Yeongu Chung, Sung Ho Lee, Seok Keun Choi*
- 386 – 393 Autostereoscopic Three-Dimensional Neuronavigation to the Sella: Technical Note: *A. Nimer Amr, Jens Conrad, Sven Kantelhardt, Alf Giese*
- 529 – 533 Use of Simple Neck Extension to Improve Guiding Catheter Accessibility in Tortuous Cervical Internal Carotid Artery for Endovascular Embolization of Intracranial Aneurysm: A Technical Note: *Megumu Takata, Hitoshi Fukuda, Masanori Kinosada, Kosuke Miyake, Kenichi Murao*
- 755 – 759 Posterior Paramedian Approach to Ventrally Located Spinal Meningioma: *Han Soo Chang*
- 760 – 764 Biplanar Fluoroscopy-Guided Percutaneous Lead Implantation for Spinal Cord Stimulation: Technical Note: *Aaron Lawson McLean, Susanne Frank, Daniel Staribacher, Rolf Kalff, Rupert Reichart*
- 796 – 804 Repair of V2 Vertebral Artery Injuries Sustained During Anterior Cervical Discectomy: *Evgenii Belykh, David S. Xu, Kaan Yağmurlu, Ting Lei, Vadim A. Byvaltsev, Curtis A. Dickman, Mark C. Preul, Peter Nakaji*

- 812 — 817 Flow Diverters as Useful Adjunct to Traditional Endovascular Techniques in Treatment of Direct Carotid-Cavernous Fistulas: *Christopher S. Ogilvy, Rouzbeh Motiei-Langroudi, Mohammad Ghorbani, Christoph J. Griessenauer, Abdulrahman Y. Alturki, Ajith J. Thomas*
- 971 — 979 Customized Polymethylmethacrylate Cranioplasty Implants Using 3-Dimensional Printed Polylactic Acid Molds: Technical Note with 2 Illustrative Cases: *Joe Abdel Hay, Tarek Smayra, Ronald Moussa*
- 1030 **CLINICAL IMAGE:** *Full text available at [www.WORLDNEUROSURGERY.org](http://www.WORLDNEUROSURGERY.org) and [www.sciencedirect.com](http://www.sciencedirect.com)*
- “Outside Support”: Curious Case of Duplicated Posterior Elements: *Rahat Brar, Abhishek Prasad, Sachin Goudihalli, Ashis Pathak*
- 1031 **VIDEO ARTICLE:** *Full text available at [www.WORLDNEUROSURGERY.org](http://www.WORLDNEUROSURGERY.org) and [www.sciencedirect.com](http://www.sciencedirect.com)*
- Microsurgical Resection After Failed Gamma Knife Radiosurgery of Papillary Tumor of the Pineal Gland: *Anil Nanda, Piyush Kalakoti, Devi Prasad Patra, Tanmoy Maiti, Hai Sun*
- 1032 — 1044 **CASE REPORTS:** *Full text available at [www.WORLDNEUROSURGERY.org](http://www.WORLDNEUROSURGERY.org) and [www.sciencedirect.com](http://www.sciencedirect.com)*
- Chronic Spinal Subdural Hematoma Associated with Antiplatelet Therapy: *Yukinori Akiyama, Izumi Koyanagi, Nobuhiro Mikuni*
  - Primary Pituitary Fibrosarcoma with Previous Adenoma: *Ahmed B. Bayoumi, Jenny X. Chen, Peter R. Swiatek, Yosef Laviv, Ekkehard M. Kasper*
  - Reconstruction of Thoracic Spine Using a Personalized 3D-Printed Vertebral Body in Adolescent with T9 Primary Bone Tumor: *Wen Jie Choy, Ralph J. Mobbs, Ben Wilcox, Steven Phan, Kevin Phan, Chester E. Sutterlin III*
  - Ruptured Distal Anterior Choroidal Artery Aneurysm Treated with Superselective Provocative Testing and Coil Embolization: *Philip G.R. Schmalz, Abdulrahman Alturki, Christopher S. Ogilvy, Ajith J. Thomas*
  - Cross-Modal Recruitment of Auditory and Orofacial Areas During Sign Language in a Deaf Subject: *Juan Martino, Carlos Velasquez, Javier Vázquez-Bourgon, Enrique Marco de Lucas, Elsa Gomez*
  - Spontaneous Regression of a Hypoglossal Neurinoma: Case Report and Review of the Literature: *Xavier A. Santander, Carlos E. Cotúa, Cristóbal Saldaña*
  - A Case of Echordosis Physaliphora in the Prepontine Cistern: A Rare Entity in the Differential Diagnosis of an Epidermoid Cyst: *Kenji Miki, Koji Yoshimoto, Ataru Nishimura, Satoshi O. Suzuki, Akio Hiwatashi, Koji Iihara*
  - Hereditary Multiple Cerebral Cavernous Malformations Associated with Wilson Disease and Multiple Lipomatosis: *Olga B. Belousova, Dmitry N. Okishev, Tatyana M. Ignatova, Maria S. Balashova, Eugenia S. Boulygina*
  - Successful Hybrid Neurovascular Surgery for a Ruptured Basilar Artery Dissecting Aneurysm in a Patient with Jeopardized Collateral Circulation Associated with Aortitis Syndrome: *Kazuaki Yamamoto, Takahisa Mori, Tsuyoshi Watanabe, Tomonori Iwata, Gakuji Gondo, Masahiko Tanaka, Satoshi Tanaka*
  - Dynamic Four-Dimensional Computed Tomography Angiography for Neurovascular Pathologies: *Ahmed Alnemari, Tarek R. Mansour, Mohamad Bazerbashi, Mark Buehler, Jason Schroeder, Daniel Gaudin*

*Continued on page XII*

Continued from page XI

- Case of Familial Moyamoya Disease Presenting 10 Years After Initial Negative Magnetic Resonance Screening in Childhood: *Jiro Aoyama, Tadashi Nariai, Maki Mukawa, Motoki Inaji, Yoji Tanaka, Taketoshi Maehara*
- Was Cavum Septum Pellucidum the Cause of Intractable Seizure in a 17-Year-Old Boy with Wilson Disease?: *Asifur Rahman, Saif Ul Haque, Paawan Bahadur Bhandari, Shamsul Alam*
- Delayed Brainstem Hemorrhage Secondary to Mild Traumatic Head Injury: Report of Case with Good Recovery: *Kun Hou, Jinchuan Zhao, Xianfeng Gao, Xiaobo Zhu, Guichen Li*
- Medulloblastoma with Atypical Dynamic Imaging Changes: Case Report with Literature Review: *Shuang-Shuang Song, Jian-Hong Wang, Wei-Wei Fu, Ying Li, Qing-Lan Sui, Xue-Jun Liu*
- Long-Standing Isolated Autoimmune Hypophysitis Diagnosed with Endoscopic Transventricular Biopsy: *Lorenzo Bertulli, Giulio Andrea Bertani, Umberto Gianelli, Giovanna Mantovani, Paolo Maria Rampini, Marco Locatelli*
- Intracranial Hypotension Following Traumatic Brain Injury: A Diagnostic and Therapeutic Challenge: *Jacob Chen Ming Low, Anan Shtaya, Samantha Hettige*
- Subarachnoid Hemorrhage Because of Distal Superior Cerebellar Artery Dissection in Neurofibromatosis Type 1: *Yuki Takeshima, Yuki Ohmori, Takashi Nakagawa, Yasuyuki Kaku, Jun-ichi Kuratsu, Shigetoshi Yano*
- Primary Spinal Intramedullary Neurocysticercosis: A Report of 3 Cases: *Subramanya G.S. Datta, Ritu Mehta, Shrikant Macha, Sanjog Tripathi*
- “On the Spot”: The Use of Four-Dimensional Computed Tomography Angiography to Differentiate a True Spot Sign From a Distal Intracranial Aneurysm: *Johanna P. de Jong, Leo Kluijtmans, Martinus J. van Amerongen, Mathias Prokop, Hieronymus D. Boogaarts, Frederick J.A. Meijer*
- Remote Lesions of Synchronous Sacral and Cervical Dural Arteriovenous Fistulas: A Case Report: *Yasuyuki Kaku, Yuki Ohmori, Takayuki Kawano, Yuki Takeshima, Jun-ichi Kuratsu*
- Newly Detected Cervical Spinal Dural Arteriovenous Fistula on Magnetic Resonance Angiography Causing Intracranial Subarachnoid Hemorrhage: *Hiroaki Matsumoto, Hiroaki Minami, Ikuya Yamaura, Yasuhisa Yoshida, Yutaka Hirata*
- Endoscopic Removal of a Bullet That Migrated to the Third Ventricle Causing Hydrocephalus: *Aydin Aydoseli, Tugrul Cem Unal, Yavuz Aras, Pulat Akin Sabanci, Emre Altunrende, Nail Izgi*
- Giant Bicompartamental Cystic Tentorial Schwannoma Mimicking a Meningioma: *Amandeep Kumar, Manmohan Singh, Mehar C. Sharma, Poodipedi S. Chandra, Bhawani S. Sharma, Ashok K. Mahapatra*
- Delayed Retroclival and Cervical Spinal Subdural Hematoma Complicated by Preexisting Chiari Malformation in Adult Trauma Patient: *Ha Son Nguyen, Hoon Choi, Shekar Kurpad, Hesham Soliman*
- A Confirmed Case in the United Kingdom of Hirayama Disease in a Young White Male Presenting with Hand Weakness: *Daniel Lewis, Ankur Saxena, Amit Herwadkar, John Leach*
- A Primary Pigmented Choroid Plexus Papilloma Located Within the Sella Turcica: Case Report and Literature Review: *Xuan Gong, Chao Liu, Longbo Zhang, Zhenyan Li, Christopher M. Bartley, Zhixiong Liu*

- Endovascular Therapy for the Steal Phenomenon due to the Innominate Artery Severe Stenosis and Bilateral Internal Carotid Artery Severe Stenosis: *Shuta Aketa, Daisuke Wajima, Masahiro Kishi, Yudai Morisaki, Taiji Yonezawa, Ichiro Nakagawa, Hiroyuki Nakase*
- Rupture After Bypass and Distal Occlusion of Giant Anterior Circulation Aneurysms: *Sophia F. Shakur, Andrew P. Carlson, Dominic Harris, Ali Alaraj, Fady T. Charbel*
- Pial-Dural Intracranial Arteriovenous Fistula with Flow-Associated Aneurysmal Rupture—Case Report with Review of Literature and Proposal on the Mechanism of Hemorrhage and Treatment Options: *Christopher Elia, Tanya Minasian, Mazen Noufal, Vaninder Chhabra*
- Cervical Burst Fracture in a Patient with Contiguous 2-Level Cervical Stand-Alone Cages: *Rui Feng, Joshua Loewenstern, John Caridi*
- Concomitant Lumbosacral Perimedullary Arteriovenous Fistula and Spinal Dural Arteriovenous Fistula: *Jingwei Li, Guilin Li, Lisong Bian, Tao Hong, Jiaying Yu, Hongqi Zhang, Feng Ling*
- Image Guidance to Aid Pedicle Screw Fixation of a Lumbar Fracture-Dislocation Injury in a Toddler: *John K. Houten, Jonathan Nahkla, Shashank Ghandi*
- A Hemorrhagic Clival Chordoma with a Long Progression-Free Survival: *Marcelo D. Vilela, Hugo A.S. Pedrosa, Marco Antonio Dias Filho*
- Microsurgical Repair of Ruptured Aneurysms Associated with Moyamoya-Pattern Collateral Vessels of the Middle Cerebral Artery: A Report of Two Cases: *Min Lang, Nina Z. Moore, Alex M. Witek, Varun R. Kshetry, Mark D. Bain*
- Incidental Primary Intradural Carcinoid Tumor in a Patient with Lumbar Radiculopathy: *Stavros Koustaïs, Philip J. O'Halloran, Alfrzdaq Hassan, Francesca Brett, Steven Young*
- Recurrent Pituicytoma with Pseudoaneurysm: Report of a Challenging Case: *Stefano Peron, Jaime Mandelli, Nicola Galante, Stefano Colombo, Davide Locatelli*
- An Intraoperative Look at a Residual/Recurrent Tentorial Dural Arteriovenous Fistula: *Bradley A. Gross, Andrew F. Ducruet, Brian T. Jankowitz, Paul A. Gardner*
- Transventricular Migration of Neurocysticercosis: *Abhidha Shah, Ravikiran Vutha, Shilpa Sankhe, Atul Goel*
- A Case of Laterally Extended High-Positioned Chordoma Treated Using the High Cervical Retropharyngeal Approach: *Kiyoshi Ito, Takuya Nakamura, Tatsuro Aoyama, Tetsuyoshi Horiuchi, Kazuhiro Hongo*

## CORRIGENDA

- 1028 Corrigendum to “Clinical Outcomes of Correcting Cervical Deformity in Cerebral Palsy Patients” [World Neurosurgery 96 (2016) 500–509]: *Chang Kyu Lee, Ha Ra Jeon, Do Heum Yoon, Keung Nyun Kim, Seong Yi, Dong Ah Shin, Naobumi Hosogane, Kai Cao, Sung-Rae Cho, Yoon Ha*
- 1029 Corrigendum to: ‘Shunting of Syringomyelic Cavities by Using a Myringotomy Tube: Technical Note and Long-Term Results’ [World Neurosurgery 98 (2017) 1–5]: *Dorota Tassigny, Basel Abu-Serieh, Daniella Tsague Fofe, Jacques Born, Germain Milbouw*