

We agree with the author that it might have been better to use the standard deviation, interquartile range, or range as a measure of dispersion. Nevertheless, we feel this is a minor error because the confidence interval of quantitative values would also be an approximate measure of dispersion in the reference population of our sample given that this sample corresponds to the entire population of publications. According to Dr García-Doval,<sup>1</sup> the use of statistical significance ( $P$ ) in this article is not appropriate because we analyzed the entire sample. We were interested in measuring the difference between the two periods, using a statistical tool that would allow us to detect significant differences and interpret whether or not any significant differences were relevant or whether they are important in a bibliometric study.

In the other article, "Análisis de la producción científica nacional e internacional de los dermatólogos españoles (1988-2000)," (Analysis of International and National Scientific Production of Spanish Dermatologists [1988-2000]),<sup>3</sup> we used the odds ratio (OR) and respective confidence interval as a measurement of association between publications in international journals and those in *Actas*. According to Dr García-Doval,<sup>1</sup> in this article we should

not have used the confidence interval or tested for statistical significance because we have worked with the entire sample of the articles, but this is not the case. Publications in international journals do not account for all papers published by Spanish dermatologists and so we did indeed study a sample since there were international journals for which we were unable to find abstracts in the database used. As a result, we feel that the use of confidence interval and statistical tests in this publication is appropriate to identify significant differences between international journal and *Actas* papers. It is possible that information containing many odd ratios and  $P$  values proves to be weighty. As in the previous article, not all significant  $P$  values have the same relevance. For example, the Hospital General de Soria produced 0.2% of all documents in the international journals and 1% of those published in *Actas*, with a difference of 0.8% in prevalence and a statistical significance of  $P=.01$ . Despite this, we feel this difference would not be relevant in the literature. Conversely, Hospital Universitario 12 de Octubre had published 3.8% of the articles in international journals and 11.1% of those published in *Actas*, with a difference of 7.7% in prevalence and

a statistical significance of  $P<.001$ . In this case, the Hospital Universitario 12 de Octubre produces more articles for the *Actas* journal, compared to international journals. These examples illustrate the fact that statistics can help, but an accurate interpretation of the results from the clinical (or bibliometric, in this case) point of view is also needed.

We wish to thank Dr García Doval<sup>1</sup> for his letter, as it allows us to maintain a dialectic discussion with the *Actas* readership. Hopefully this discussion will help improve the papers and enhance communication among journal readers.

## References

1. García Doval I. De Intervalos de Confianza, pes y farolas. *Actas Dermosifiliogr.* 2007;98:135.
2. Belinchón I, Miralles J, Ramos JM. Análisis de la producción científica de la revista *Actas Dermo-sifiliográficas* en el trienio 2003-2005. *Actas Dermosifiliogr.* 2006;97:428-35.
3. Ramos JM, Belinchón I, Miralles J, Ballester R, Sánchez-Yus E. Análisis de la producción científica nacional e internacional de los dermatólogos españoles (1988-2000). *Actas Dermosifiliogr.* 2006;97:436-43.

## Benign Epithelioid Fibrous Histiocytoma

A Alfaro-Rubio,<sup>a</sup> R Botella-Estrada,<sup>a</sup> A Calatrava,<sup>b</sup> C Requena,<sup>a</sup> C Serra-Guillén,<sup>a</sup> L Hueso,<sup>a</sup> A Martorell,<sup>a</sup> O Sanmartín,<sup>a</sup> E Nagore,<sup>a</sup> B Llombart,<sup>a</sup> and C Guillén<sup>a</sup>

<sup>a</sup>Servicio de Dermatología and <sup>b</sup>Servicio de Anatomía Patológica, Instituto Valenciano de Oncología, Valencia, Spain

### To the Editor:

Epithelioid benign fibrous histiocytoma (EBFH) is a variant of dermatofibroma first described by Wilson-Jones in 1989.<sup>1</sup>

The incidence of EBFH ranges between 0.5% and 1.4% of all benign fibrous histiocytomas of the skin in the various published series.<sup>1-3</sup>

We describe a 33-year-old man who consulted for a stable, asymptomatic lesion with onset 2 years earlier, located on the right gluteus.

The patient's relevant history included in situ malignant melanoma in the right clavicular region 5 years before, with yearly clinical follow-up showing no evidence of local or distant recurrence.

The physical examination revealed an exophytic tumor with a maximum diameter of 0.6 cm located on the right gluteus, of port-wine color. The lesion remained unchanged with pressure and had a rather hard fibrous texture, although no deep infiltration could be observed.

Dermatoscopy study (Figure 1) of the lesion showed branched vessels

predominantly at the periphery as well as whitish reticular structures against a background of uniform erythematous violaceous structures. There was a complete absence of pigmented reticulum, spots, corpuscles, or blue-white veil.

An excisional biopsy of the lesion was analyzed using hematoxylin-eosin staining and various immunohistochemical techniques. The lesion was exophytic, well-delimited, and located mainly in the papillary dermis in a region with no skin appendages. The overlying epidermis had no ridges and formed a ring that delimited the lesion, but was not connected to it.

At higher magnification, a dense cellular component was apparent accompanied by rich vascularization, particularly at the periphery of the lesion (Figure 2).

The cells comprising the lesion had an extensive eosinophilic cytoplasm with a large, vesicular nucleus, some of which were binucleated with a small nucleolus surrounded by abundant, extremely dense collagen.

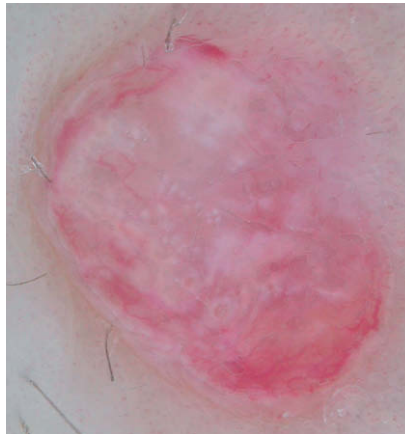
The immunohistochemical study disclosed a lesion composed of cells with strong vimentin staining that were negative for S-100 (Figure 3), Melan-A, EMA, factor XIIIa, CD-31, CD-34, and CD-68.

The diagnosis was epithelioid benign fibrous histiocytoma.

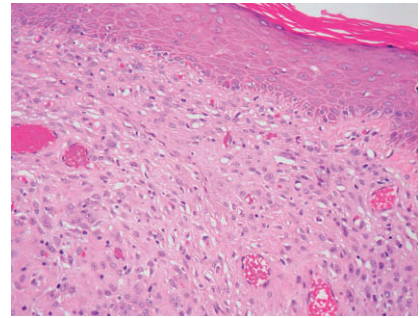
Once excised, the lesion showed no recurrence 1 year later.

This entity usually presents clinically as a single nodular lesion, often located on the lower limbs with a characteristic vascular clinical appearance that is often confused with a pyogenic granuloma.<sup>4-7</sup>

The histopathology of this tumor differs substantially from other forms of dermatofibromas in 5 main characteristics: predominance of epithelioid cells, relative shortage of secondary elements (such as multinucleated giant cells, foamy macrophages, or macrophages with traces of hemosiderin), good delimitation, prominent vascularization, and centered in the papillary dermis in most cases.<sup>3</sup>



**Figure 1.** Branched vessels predominantly at the periphery and whitish reticular structures against a background of uniform violet-pink structures and complete absence of pigmented lesions.



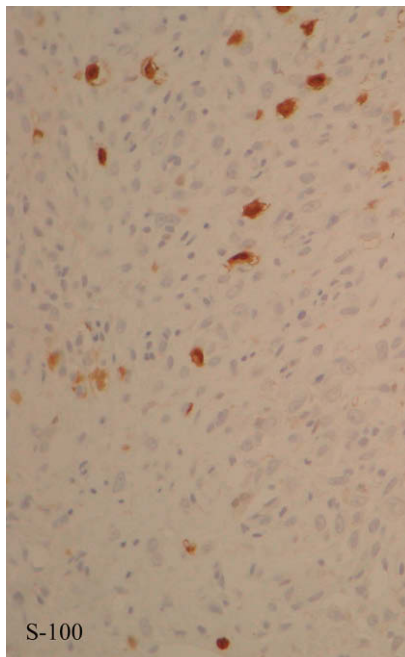
**Figure 2.** Dense dermal cellular component accompanied by rich vascularization, particularly at the periphery of the lesion. (Hematoxylin-eosin, ×20).

In the immunohistochemical study, EBFH is characterized by strong, diffuse positivity for vimentin, moderate positivity for factor XIIIa, and negative results for protein S-100. However, some cases of EBFH have been published that, like ours, were negative for factor XIIIa.<sup>2</sup> The differential

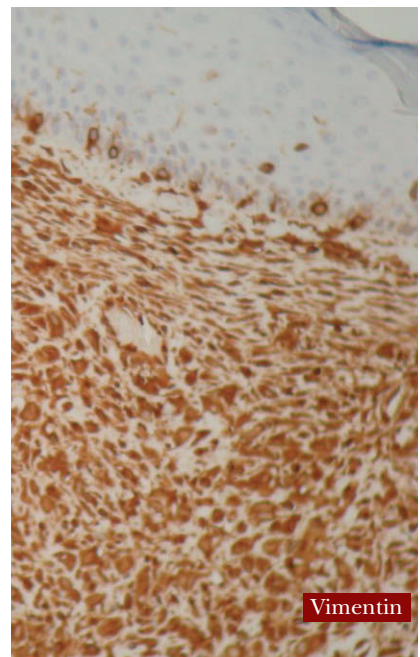
histopathological diagnosis of EBFH should consider the desmoplastic variant of Spitz nevus, as the negative results of EBFH for melanocytic cell markers, such as S-100, HMB-45, and Melan-A, differentiate EBFH from this entity.<sup>3,7</sup>

## References

1. Wilson Jones E, Cerio R, Smith NP. Epithelioid cell histiocytoma: a new entity. *Br J Dermatol.* 1989;120:185-95.



S-100



Vimentin

**Figure 3.** Immunohistochemistry: Vimentin-positive and S-100-negative (×40)

2. Singh Gomez C, Calonje E, Fletcher CDM. Epithelioid benign fibrous histiocytoma of skin: clinico-pathological analysis of 20 cases of poorly known variant. *Histopathology*. 1994; 24:123-9.
3. Glusac EJ, McNiff JM. Epithelioid cell histiocytoma: a simulant of vascular and melanocytic neoplasms. *Am J Dermatopathol*. 1999;21:1-7.
4. Blum A, Jaworski S, Metzler G, Bauer J. Lessons on dermoscopy: Dermoscopic pattern of hemosiderotic dermatofibroma. *Dermatol Surg*. 2004;30:1354-5.
5. Álvarez JG, Pérez A, Romero A, Gómez de la Fuente E, Rodríguez Peralto JL, Iglesias L. Histiocitoma fibroso aneurismático (angiomatoide). *Actas Dermosifiliogr*. 1999;90:128-31.
6. Heras JA, Fernández FJ, Martínez P, Jiménez F, Muñoz MD, Barba L. Nevo de Spitz desmoplásico. *Actas Dermosifiliogr*. 2001;92:305-7.
7. Botella-Estrada R, Rodríguez M, Sanmartín O, Aliaga A. Histiocitoma de células epitelioides. Una nueva variedad de dermatofibroma. *Actas Dermosifiliogr*. 1993;84:99-102.

## Eruptive Pseudoangiomatosis

A Romero,<sup>a</sup> L Martín,<sup>b</sup> A Hernández-Núñez,<sup>a</sup> D Arias,<sup>a</sup> E Castaño,<sup>a</sup> and J Borbujo<sup>a</sup>

<sup>a</sup>Servicio de Dermatología and <sup>b</sup>Servicio de Anatomía Patológica, Hospital de Fuenlabrada, Madrid, Spain

### To the Editor:

Eruptive pseudoangiomatosis is characterized by small, shiny red papules of angioma-like appearance surrounded by a characteristic pale halo. The condition usually resolves spontaneously within a few days.

A 43-year-old man consulted for the onset of small asymptomatic, erythematous lesions on the forearms 7 days earlier. His history included hypertension, hypercholesterolemia,

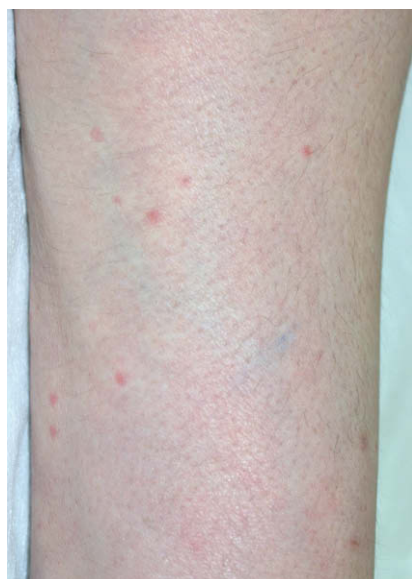morbid obesity, alcoholism, smoking, and obstructive lung disease that, due to acute recurrence caused by a respiratory infection of undetermined cause, required admission to the intensive care unit up to 2 weeks before he was seen by our unit.

The physical examination showed almost 20 bright red, nonconfluent, maculopapular lesions on both forearms, measuring diameter 2-3 mm and surrounded by a clear halo that whitened on diascopy (Figure 1).

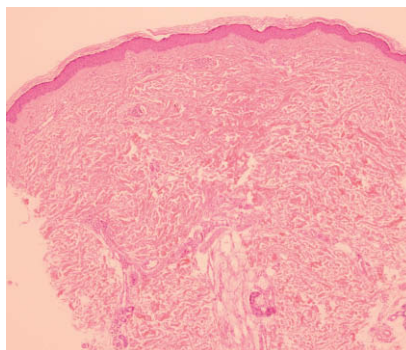
The biopsy revealed mild dermal edema and slight perivascular lymphocytic infiltrate in the superficial and middle dermis; the vessels of the superficial dermis

were dilated, congestive, with no erythrocytic extravasation, capillary proliferation, or vasculitis (Figure 2). Additional examinations, including complete blood count and basic biochemistry, as well as serology for cytomegalovirus, Epstein-Barr virus, parvovirus, human immunodeficiency virus, and hepatitis C virus were normal or negative. The lesions disappeared spontaneously after 10 days.

Eruptive pseudoangiomatosis is a rare process that was first described by Cherry in 1969,<sup>1</sup> although the term itself was coined by Prose in 1993.<sup>2</sup> Its etiology is unknown. A viral cause has been suspected because of the presence in children of prodrome symptoms that include fever, diarrhea, or respiratory symptoms,<sup>3,4</sup> because the symptoms have been associated with echovirus infection in 4 cases,<sup>1</sup> and because several familial cases<sup>4,5</sup> and other epidemics in closed communities have been published.<sup>6</sup> Other evidence indicating viral infection is a report of apoptosis and viral-like particle groups in the lymphocytes of perivascular infiltrate in an ultrastructural study.<sup>7</sup> Cases associated with acute lymphocytic leukemia<sup>8</sup> and others that have presented after renal transplantation have also been described,<sup>9</sup> with no evidence of viral infection. Other



**Figure 1.** Red, maculopapular, well-delimited lesions surrounded by a pale halo on the forearm.



**Figure 2.** Histological image of one of the lesions, showing capillary dilatation and endothelial edema, accompanied by perivascular lymphocytic infiltrate, with no extravasation or vasculitis. (Hematoxylin-eosin,  $\times 100$ )