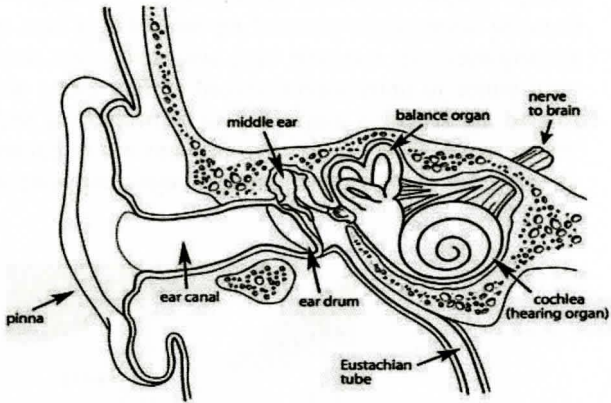


STRUCTURE OF THE EAR



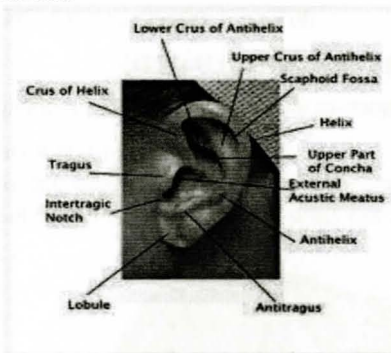
All India Institute of Speech and Hearing

Manasagangothri, Mysore 570006

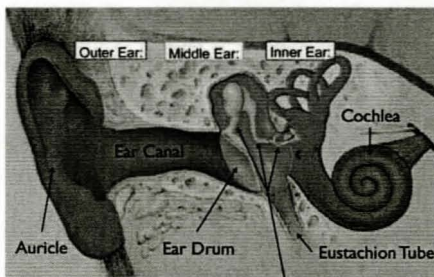
DEPARTMENT OF AUDIOLOGY

STRUCTURE OF THE EAR

Eyes, ear, nose, tongue and skin are the five sense organs. Eyes sense vision, ears sense hearing, nose senses smell, tongue senses taste and skin senses touch and sends the information to the brain. It is very difficult for the person to live a normal life if any of the senses are damaged. Thus, any damage to the ear can definitely lead to problems. Before knowing about the problems it is important to know about the structure of a normal ear.



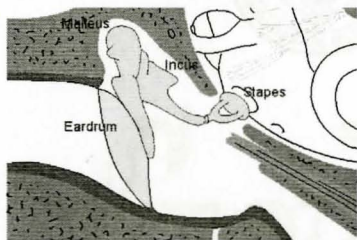
The structure of the ear can be broadly divided into outer ear, middle ear and inner ear.



3 Middle Ear Bones

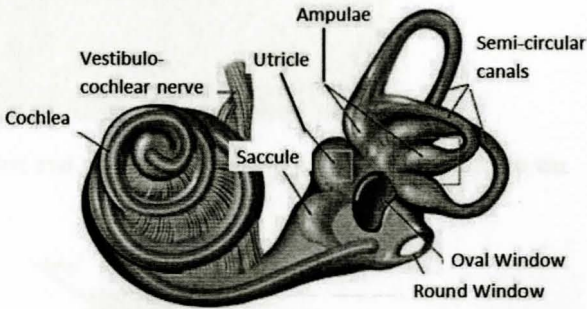
Outer Ear: Outer ear is made up of cartilaginous pinna and the ear canal. Pinna is made up cartilaginous structure which is covered by the skin. Ear canal is like S-shaped tube. The pinna collects the sound from outside and sends it to the ear drum and then to the middle ear. At the end of the ear canal, there is diagonally placed ear drum. Ear drum is a very thin structure of 0.1mm. Ear canal protects the ear by not allowing external substance, dust, tiny insects etc from entering into the ear.

Middle ear: Middle ear has a volume of approximately 2cc. It is made up 3 tiniest bones of the body namely hammer shaped malleus, incus and stapes which forms the ossicular chain.



The first bone in the ossicular chain is the malleus which is connected to incus. Incus is connected to the smallest bone of the body – the Stapes. The end of the stapes is attached to oval window which is the part of inner ear. These three bones help in proper transmission of sound from the middle to the inner ear. Eustachian tube connects the Nasopharynx and middle ear. This tube is important for pressure equalization between atmosphere and the middle ear. The end of the Eustachian tube is always closed and it opens when we swallow, yawn, sneeze or cough. Hence, while travelling in airplane during ascent and descent of the plane chocolates are given so that the Eustachian tube opens and the pressure difference is maintained in the middle ear.

Inner Ear: This is a very important part of the ear. It is made up of coil shaped cochlea which is important for hearing the sound. It is also made up of semicircular canals, utricle and saccule which are important for maintaining the balance. The inner ear is made up of two types of fluids perilymph and endolymph. The cochlea consists of tiny hair cells which help in transmission of the sound to auditory nerve. The auditory nerve sends the information through electrical signals to the brain. This leads for the perception of sound.



We all may have two ears but both perceive the same sound and coordinate for better hearing. Two ears help us to identify from which direction sound is produced.

If you have any questions, feel free to contact us.

DEPARTMENT OF AUDIOLOGY

Phone No: 0821-2502000, 2502100

Toll free No:1800 425 5218, Fax: 2510515

Email: director@aiishmysore.in Website: www.aiishmysore.in

Working hours: 9.00 A.M to 5.30 P.M

Monday to Friday, except central government holidays

Developed by: Prashanth Prabhu P, Dr. Ajith Kumar U, R. Rajalakshmi