

Paper12

by Unknown Author

FILE	PAPER-12.DOCX (680.19K)	WORD COUNT	1726
TIME SUBMITTED	30-NOV-2016 10:05AM	CHARACTER COUNT	9749
SUBMISSION ID	744610866		

Background

Leigh's Disease named after Archivald Denis Leigh is a rare inherited neuro-metabolic disorder that affects the central nervous system in infants and children. It is also known as Juvenile subacute necrotizing encephalomyelopathy; infantile subacute necrotizing encephalomyelopathy and subacute necrotizing encephalomyelopathy are some of the other names for this disorder (Leigh D, 1951). Progressive neurologic deterioration and symmetric spongiform lesions with demyelination, neural necrosis, vascular and capillary proliferation, bilateral focal lesions in the brain, brainstem, basal ganglia and spinal cord characterize the disorder. MRI shows symmetric involvement of the putamen, medulla, substantia nigra, thalami, globus pallidus, caudate nuclei, basal ganglia, and brain stem (Ruhoy & Saneto, 2014). Leigh's disease is also associated with delayed motor and language development, feeding and swallowing difficulties, hearing impairment and loss of sensation (Naviaux, 2004; Nesbitt, 2013)

Auditory brain stem responses (ABR) are far-field reflection of electrical events originating in the auditory pathway. Auditory brain stem responses in a variety of neurological disorders were found to be of assistance in evaluating the mechanisms of coma, the localization of midbrain and brain stem tumors, the localization of demyelination of the brain stem, and the presence of diminished brain stem circulation (Starr and Achor, 1975).

Brainstem auditory evoked potentials (BAEPs) reflect on the integrity of the auditory brainstem pathway; given the neuropathology of Leigh syndrome, BAEP abnormalities can be expected in this disorder. Kaga (1987) and Davis (1985) reported abnormalities on BAEP, though of an inconsistent pattern, in their patients with Leigh's syndrome. The

reported abnormalities ranged from prolonged I-V interpeak latencies, absent wave V, and abnormal waveforms to completely absent responses despite normal otologic examination. However, BAEPs in children with metabolic defects leading to Leigh syndrome were not always abnormal though there were neuro-pathologic changes (as observed at autopsy) (Taylor and Robinson, 1991). The BAEPs when present in these children appeared to covary with the specific metabolic findings and the clinical course of the disease. No specific pattern of BAEP could be considered characteristic of Leigh syndrome. Therefore, Taylor and Robinson (1991) opined that normal ABRs do not exclude a diagnosis of Leigh syndrome.

However, Yoshinaga et al (2003) reported that abnormal ABR recordings seemed to precede clinical signs of brainstem impairment in Leigh's disease. In addition, they noted on follow-up evaluation that improvements in clinical status of the patients were reflected in an improvement in ABR findings. Simon et al (2015) reported bilateral auditory neuropathy in a case with Leigh's disease as evident in the absence of ABR but with preserved cochlear microphonics. However, OAEs were absent bilaterally. Early developmental milestones were normal. The absence of OAEs in this instance may indicate that the degenerative changes neurodegenerative process occurring in Leigh's disease may also affect the inner ear (Ulualp et al 2004).

This brief review indicates that auditory system may be affected in children with Leigh's disease, but there is no uniqueness in the pattern that hearing is affected. The purpose of this study is to present atypical auditory findings in a child with Leigh's disease and to draw the attention of the readers to the possibility of transient auditory neuropathy in Leigh's disease.

Case Report

PM, 2.8 years old, second born to non-consanguineous parents was brought with the complaint of regression of motor milestones. The child was born full term, cried immediately after birth and weighed 2.8 kg at birth. According to parents, PM was apparently normal until 1.3 years when there was insidious and progressive onset of tremors of upper and lower limbs. PM was able to walk without support before the onset of tremors, but now needed support. Parents were also concerned about the highly inconsistent response to acoustic stimuli by PM and regression of speech-language after he was 1.3 years. Parents observed occurrence of myoclonic jerks triggered by sound, temper tantrums, easy irritability, stranger anxiety and stubbornness in the child. PM was seen by a neurologist at the age of 1.5 years. An MRI of brain showed bilateral T2 FLAIR hyper intense signal changes in basal ganglia, inferior cerebellar peduncle, substantia nigra, symmetric putamen, central tegmental tract, and olivary nucleus. Neurologist initiated treatment for control of myoclonic jerks and tremors. PM responded well to the treatment and showed improvement in developmental milestones too.

The anxious parents brought PM to the Department of Neurology of NIMHANS for further management where a diagnosis of Leigh's disease was made. Eventually PM was referred to ¹ Department of Speech Pathology & Audiology to address the concerns of the parents on the child's speech-language development and inconsistent responses to acoustic stimuli.

Audiological evaluation

¹ Distortion product OAEs were recorded (Echoport ILO 292-II). Intensity of the tone pairs was 65 and 55 dB SPL for L1 and L2, respectively. Two separate runs for each ear were collected for determining repeatability. Validity and reliability of normal outer hair cell

function was determined by analyzing each distortion product frequency separately. An OAE response was considered valid if the distortion product amplitude (signal to noise ratio) was greater than or equal to 6 dB.

ABRs (IHS, Miami, Florida) were recorded ¹ between the upper forehead and ipsilateral mastoid, with the opposite mastoid as ground. Bandpass filtering was set between 100 and 3000 Hz, with manual and automatic artifact rejection. Stimuli included rarefaction and condensation polarity clicks presented at 90 dB nHL through insert earphones (ER-3A) at a presentation rate of 11.1 clicks per second. Electrode impedance was maintained at <5 kOhms. Two recordings for rarefaction and one for condensation stimuli of 1200 samples each were obtained. ¹ Tube clamping was resorted to determine if the response components are biologic in origin (CM) or a recording artifact of the electrical input to the earphone or a stimulus artifact. The stimulus artifact will persist and CMs will disappear with withdrawal of stimuli through tube clamping.

Speech and language evaluation

Receptive and expressive language acquisition of PM was assessed on ¹⁰ the Receptive-Expressive Emergent Language tool (REEL-3; Bzoch, 2003). PM was also assessed on 3D-LAT for receptive and expressive language as well as cognition.

Analysis

Two expert audiologists made a blind and independent review of the recorded ABR waveforms. Reviewer 1 suspected cochlear hearing loss while reviewer 2 suspected auditory neuropathy spectrum disorder. Both of them, however, suggested correlation of ABR waveforms with the clinical information.

Results

Ringing cochlear microphonics was present up to 60dB nHL in both the ears. 5th peak could be traced up to 70dB nHL in the right ear and 60dB nHL in the left ear. No other peaks were clear. Waveforms are characterized by poor signal to noise ratio (Figures 1 and 2). The OAEs were present in the right ear, with lower amplitudes, and present only for 3 frequencies in the left ear (Figures 3 and 4).

Insert Figures 1, 2, 3 and 4 here

Speech-language evaluation at 30 months showed that PM had a receptive as well as expressive language age of 30 to 33 months on REEL. PM had a score of 30-32 months on each of the three dimensions of 3D-LAT.

Discussion

It is speculated here that audiological results - not so robust OAEs and 5th peak up to 60dB nHL with cochlear microphonics - indicate some variant of ANSD. This assumption is supported by the observation that PM picked up almost normal speech-language sometime after treatment for neurological problems was initiated. This would not have been possible if PM had permanent hearing loss. PM's developmental history as reported by parents (normal speech-language development till 1.3 years, inconsistent response to acoustic stimuli and regression of speech-language between 1.3 years and 2.0 years, and almost normal development of speech-language period beyond 2 years) support this assumption. Based on ABR, it is further speculated that PM may have had a transient form of ANSD. Psarommatis et al (2006) and Eom et al (2013) have reported cases of transient ANSD

though not in children with Leigh's disease. It is hoped that a second audiological evaluation (we hope to do this, but are not certain) would confirm or reject the hypothesis on transient ANSD in this child.

References

Bzoch KR, League R, Brown VL (2003) Receptive-Expressive Emergent Language Test. 3rd Edition Austin: PRO-ED.

Davis SL, Aminoff MJ, Berg BO. Brain-stem auditory evoked potentials in children with brain-stem or cerebellar dysfunction. *Arch Neurol* 1985;42:156–160.

Eom, J. H., Min, H. J., Lee, S. H., & Lee, H. K. (2013). A Case of Auditory Neuropathy with Recovery of Normal Hearing. *Korean Journal of Audiology*, 17(3), 138–141.

Kaga M, Naitoh H, Nihei K. Auditory brainstem response in Leigh's syndrome. *Acta Paediatr Jpn* 1987;29:254-60.

Leigh D. Subacute necrotizing encephalomyelopathy in an infant. *J Neurol Neurosurg Psychiatry* 1951;14:216–221.

Naviaux RK, Nguyen KV. POLG mutations associated with Alpers' syndrome and mitochondrial DNA depletion. *Ann Neurol* 2004;55(5):706–712

Nesbitt V, Pitceathly RD, Turnbull DM, et al. The UK MRC Mitochondrial Disease Patient Cohort Study: clinical phenotypes associated with the m.3243A>G mutation—implications for diagnosis and management. *J Neurol Neurosurg Psychiatry* 2013; 84(8): 936–938

Psarommatis, I., Riga, M., Douros, K., Koltsidopoulos, P., Douniadakis, D., Kapetanakis, I., & Apostolopoulos, N. (2006). Transient infantile auditory neuropathy and its clinical implications. *Int J Pediatr Otorhinolaryngol.* 2006; 70(9):1629-37.

Ruhoy, I. S., & Saneto, R. P. (2014). The genetics of Leigh syndrome and its implications for clinical practice and risk management. *The Application of Clinical Genetics*, 7, 221–234.

Simon, M., Richard, E. M., Wang, X., Shahzad, M., Huang, V. H., Qaiser, T. A., Riazuddin, S. (2015). Mutations of Human NARS2, Encoding the Mitochondrial Asparaginyl-tRNA Synthetase, Cause Nonsyndromic Deafness and Leigh Syndrome. *PLoS Genetics*, 11(3), e1005097.

Starr A, Achor J. Auditory brain stem responses in neurological disease. *Arch Neurol.* 1975 Nov; 32(11):761-8.

Taylor MJ, Robinson BH. Evoked potentials in children with oxidative metabolic defects leading to Leigh syndrome. *Pediatr Neurol* 1992;8:25–29.

Ulualp et al. Cochlear Degeneration in Leigh Disease. *Laryngoscope*, 114:2239-42, 2004

Yoshinaga H, Ogino T, Endo F, et al. Longitudinal study of auditory brainstem response in Leigh syndrome. *Neuropediatrics* 2003;34:81–86.

Figure 1: Auditory brainstem responses for the right ear. The four groups of waveforms correspond to 90, 80, 70 and 60 dB nHL (from top - numbers not clearly seen).

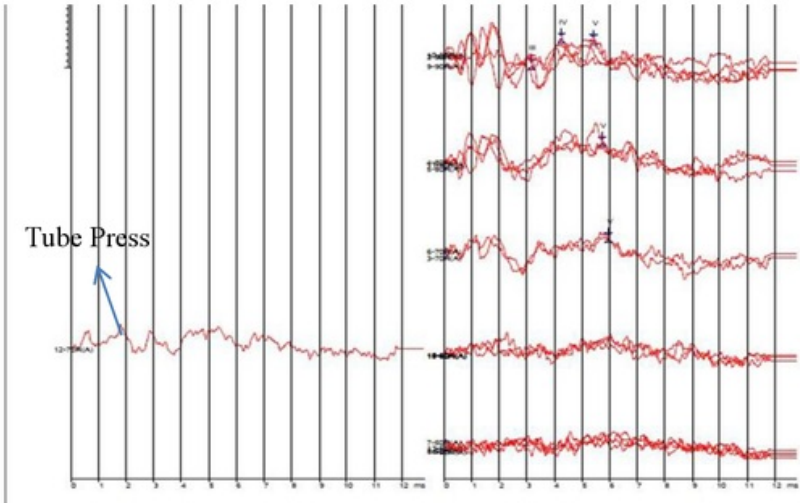


Figure 2: Auditory brainstem responses for the left ear. The four groups of waveforms correspond to 90, 80, 70 and 60 dB nHL (from top - numbers not clearly seen).

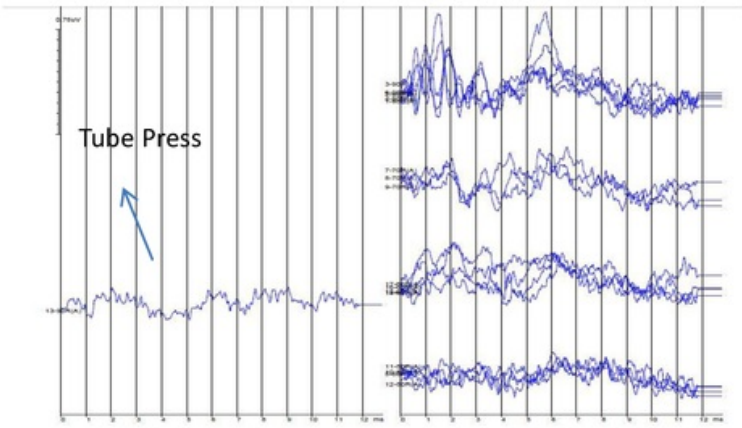


Figure 3: Otoacoustic emissions for the right ear

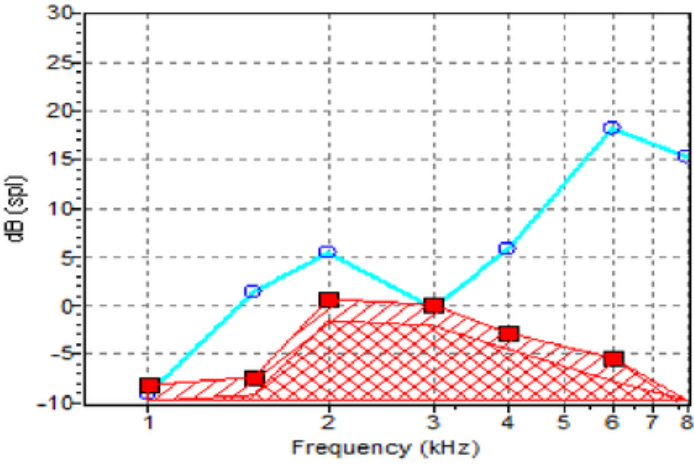
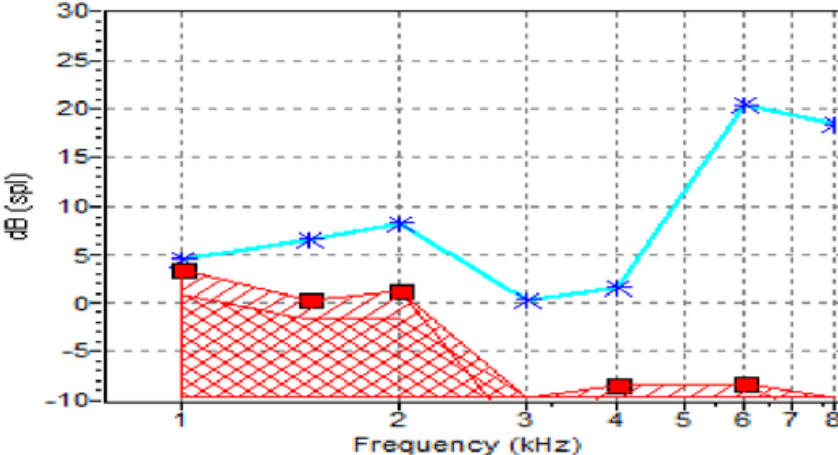


Figure 4: Otoacoustic emissions for the left ear



Paper12

ORIGINALITY REPORT

%29
SIMILARITY INDEX

%14
INTERNET SOURCES

%26
PUBLICATIONS

%2
STUDENT PAPERS

PRIMARY SOURCES

1 Yuvaraj, Pradeep, M. Jayaram, Rahina Abubacker, and P.S. Bindu. "Auditory neuropathy spectrum disorder in hypomyelinating leukodystrophy—A case study", *International Journal of Pediatric Otorhinolaryngology*, 2015. **%13**
Publication

2 Taylor, M.J.. "Evoked potentials in children with oxidative metabolic defects leading to Leigh syndrome", *Pediatric Neurology*, 199201/02 **%5**
Publication

3 archneur.jamanetwork.com **%3**
Internet Source

4 Seckin O. Ulualp. "Cochlear Degeneration in Leigh Disease: Histopathologic Features", *The Laryngoscope*, 12/2004 **%2**
Publication

5 Submitted to Columbia University **%1**
Student Paper

Submitted to Panola College

6

Student Paper

% 1

7

www.ncbi.nlm.nih.gov

Internet Source

% 1

8

www.nsslha.org

Internet Source

% 1

9

Santoro, L.. "A novel SURF1 mutation results in Leigh syndrome with peripheral neuropathy caused by cytochrome c oxidase deficiency", *Neuromuscular Disorders*, 20000801

Publication

% 1

10

"Differential Diagnosis", *Clinical Assessment and Intervention for Autism Spectrum Disorders*, 2008

Publication

% 1

11

services.rmh.med.sa

Internet Source

% 1

12

J. Finsterer. "Central nervous system manifestations of mitochondrial disorders", *Acta Neurologica Scandinavica*, 10/2006

Publication

% 1

EXCLUDE QUOTES ON

EXCLUDE MATCHES < 7 WORDS

EXCLUDE BIBLIOGRAPHY ON

